

CASE REPORT

Hematoma Causing Iliac Vein Compression Mimicking Deep Vein Thrombosis in an Elderly Patient with Hip Arthroplasty

Shusuke Yagi¹, Eriko Nasu², Kaori Inaba¹, Keisuke Inaba¹, Tomoya Hara², Muneyuki Kadota², Yutaka Kawabata², Takayuki Ise², Koji Yamaguchi², Hirotsugu Yamada², Takeshi Soeki², and Masataka Sata²

¹Department of General Medicine, Tokushima University Graduate School of Biomedical Sciences, Tokushima, Japan, ²Department of Cardiovascular Medicine, Tokushima University Hospital, Tokushima, Japan

Abstract : Unilateral leg edema in elderly patients is often attributed to deep vein thrombosis (DVT), particularly when D-dimer levels are elevated. We report an unusual case of an elderly woman with subacute unilateral leg edema caused by compression of the external iliac vein by a traumatic hematoma following a minor fall. Contrast-enhanced computed tomography excluded DVT and revealed venous obstruction due to the hematoma. Percutaneous aspiration led to prompt resolution of the edema without the need for anticoagulation. This case underscores the importance of appropriate imaging to identify alternative etiologies of unilateral leg edema and avoid potentially harmful empiric anticoagulant therapy. *J. Med. Invest.* 73:291-293, February, 2026

Keywords : Hematoma, DVT, Differential diagnosis, Leg edema

INTRODUCTION

Unilateral leg edema in elderly patients is most often attributed to deep vein thrombosis (DVT), especially in the presence of risk factors such as recent trauma or orthopedic surgery (1). DVT can lead to life-threatening pulmonary embolism; therefore, a high index of suspicion often prompts early investigation and treatment (1). D-dimer assays are commonly used as screening tools; however, they are nonspecific. D-dimer levels can be mildly elevated in various conditions, including recent injury or bleeding. Therefore, an accurate diagnosis of DVT relies on appropriate imaging confirmation (2). Current practice guidelines emphasize the use of imaging modalities—primarily ultrasonography, with computed tomography (CT) or magnetic resonance (MR) venography, if needed—to confirm or exclude DVT in patients with unilateral limb swelling (3). This case report highlights an unusual cause of subacute unilateral leg edema in an elderly woman, in whom the initial picture mimicked DVT; however, the true etiology was a traumatic hematoma compressing the iliac vein.

CASE REPORT

An 89-year-old woman presented with a 2-week history of painless swelling of her left lower leg. She had a history of bilateral total hip replacement for osteoarthritis 10 years prior. She had been followed at a clinic for hypertension and dyslipidemia and was receiving amlodipine 2.5 mg, carvedilol 5 mg, azilsartan 10 mg, and atorvastatin 10 mg. She had no history of bleeding diathesis or previously diagnosed bleeding disorders and was not taking any antithrombotic agents. No skin color changes, ulcers, or prominent varicosities were noted on examination; only

pitting edema of the left leg was observed. No tenderness was observed along the deep veins, and there was no difference in calf temperature or erythema. Her family recalled that she had fallen onto her left hip 1 month prior, although the patient did not remember the incident and reported no acute pain at that time.

Given her age and unilateral leg edema, DVT was considered the primary concern. The D-dimer level was mildly elevated at 1.8 µg/mL (normal <0.5 µg/mL), which further raised suspicion of thrombosis. Although empirical anticoagulation was initially considered, multimodality imaging was regarded as crucial for accurate diagnosis; therefore, ultrasonography was performed first. On ultrasonography, a hypoechoic mass was observed anterior to the femoral prosthesis, suggestive of a hematoma, and no evidence of DVT was detected.

Contrast-enhanced CT showed soft-tissue swelling of the left leg without evidence of thrombus in the deep venous system. A sizable hematoma was identified on the anterior surface of the left proximal femur around the prosthetic hip (Fig. 1). This hematoma appeared to compress the adjacent left external iliac vein, which was trapped between the hematoma mass and the overlying external iliac artery, resulting in significant narrowing of the venous lumen. This finding explains the patient's impaired venous return from the left leg and the development of edema. No pelvic or femoral DVT was present on imaging.

The working diagnosis was left leg edema due to external iliac vein compression by a traumatic hematoma (secondary to a fall). Given the subacute nature of her presentation (with onset weeks after trauma) and the absence of acute compartment syndrome or active hemorrhage, a decision was made to relieve the venous obstruction by reducing the hematoma size. Under ultrasound guidance, percutaneous aspiration of the hematoma was performed using an 18-gauge needle as a single procedure. Approximately 20 mL of old bloody fluid was aspirated from the collection, leading to partial decompression of the hematoma cavity. No complications, such as infection or bleeding, occurred during the procedure. Two days after aspiration, the left leg swelling resolved completely. One-week follow-up ultrasonography demonstrated patency of the left iliac vein without compression, with a marked reduction in hematoma size. At one-year follow-up, there was no recurrence or re-expansion of

Received for publication January 28, 2026; accepted February 6, 2026.

Address correspondence and reprint requests to Shusuke Yagi, MD, PhD, Department of General Medicine, Tokushima University Graduate School of Biomedical Sciences, 3-18-15 Kuramoto-cho, Tokushima City, Tokushima 770-8503, Japan and Fax: +81-88-633-7894. E-mail: syagi@tokushima-u.ac.jp

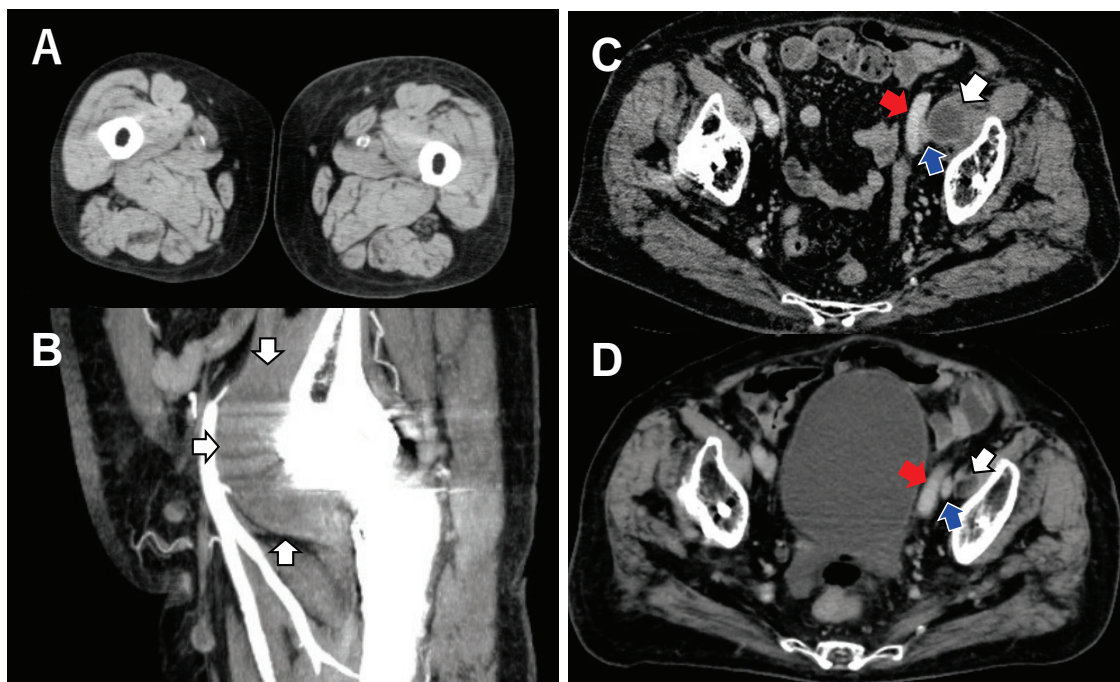


Fig. 1. Contrast-enhanced computed tomography demonstrates left leg swelling without deep vein thrombosis (A) and a hematoma on the anterior surface of the replaced femur (B, C; white arrows). The hematoma and the left external iliac artery (C, D; red arrows) compress the iliac vein (C, D; blue arrows), causing leg edema.

the hematoma.

DISCUSSION

This case illustrates an important diagnostic pitfall in evaluating unilateral leg edema in an elderly patient. DVT is a common cause of acute or subacute unilateral limb swelling, and an elevated D-dimer often reinforces clinical suspicion of DVT (1). Indeed, our patient had a mild D-dimer elevation and a history of hip prosthesis and trauma, which placed her at risk for venous thromboembolism (4, 5). Current diagnostic algorithms for suspected DVT combine clinical probability assessments with D-dimer testing and imaging confirmation. Ultrasonography is the first-line imaging modality for DVT; however, when ultrasonography is inconclusive or when pelvic vein pathology is suspected, additional imaging, such as CT or MR venography, is recommended (3). In this patient, CT was crucial because ultrasonography may not adequately visualize a pelvic hematoma compressing the iliac vein. The multimodal imaging approach ensured that the thrombus was not missed and identified the true cause of edema (3).

Notably, the patient's D-dimer elevation was a red herring. D-dimer is a fibrin degradation product that is sensitive but non-specific for thrombosis, and levels can be elevated after recent surgery, trauma, hematoma, or other inflammatory processes (6). In a post-traumatic setting, a moderately elevated D-dimer can occur secondary to tissue injury and hematoma formation, as was likely in this case (7). Thus, a positive D-dimer alone should not be viewed as a diagnostic marker for DVT without imaging evidence. Reliance on D-dimer without imaging can lead to misdiagnosis and inappropriate treatment.

Crucially, this case highlights the risk of empiric anticoagulation when the diagnosis is uncertain. Had we assumed that

the patient's leg swelling was due to DVT and initiated anticoagulant therapy immediately, which is a common practice when the clinical suspicion is high, this could have been detrimental (8). Anticoagulation in the presence of a large unresolved hematoma might have caused hemorrhage expansion or persistence, worsening venous compression and potentially leading to other complications (e.g., compartment syndrome or significant blood loss) (9, 10). There are reports in the literature of muscle or soft tissue hematomas masquerading as DVT; in these cases, delayed or inappropriate anticoagulation can cause harm until the true diagnosis is recognized (11). Therefore, careful assessment using proper imaging before initiating therapy is paramount for evaluating unilateral leg edema (12). When atypical features are present, such as lack of pain, bruising, history of trauma, or an unusual location of swelling, clinicians should broaden the differential diagnosis beyond DVT to include hematomas, Baker's cysts, external venous compression by tumors or cysts, and chronic venous insufficiency (13).

Elderly patients with orthopedic implants, such as hip prostheses, may develop peri-prosthetic fluid collections or hemorrhage after trauma or even minor falls (11). The patient had experienced a fall 1 month prior to presentation, while lower-limb edema developed 2 weeks before presentation. Muscle or subfascial hemorrhage after blunt trauma is typically venous in origin, involving persistent oozing from intramuscular veins or venous plexuses, which can lead to gradual hematoma enlargement sufficient to compress adjacent vascular structures, as observed in the present case (14).

A similar case was reported by Shieh *et al.*, in which a chronic expanding hematoma related to osteolysis around a hip arthroplasty site compressed the external iliac vein, leading to leg swelling (8). The patient's edema resolved only after surgical evacuation of the hematoma (8). Our case is analogous; however, the precipitant was acute trauma rather than prosthetic wear,

and resolution was achieved with percutaneous aspiration. Both instances underscore the importance of considering mechanical venous outflow obstruction in the differential diagnosis of unilateral leg edema, especially in patients with a history of orthopedic intervention.

Older adults are at increased risk of falls owing to declines in muscle strength, gait, and balance. Reported risk factors for hematoma formation include advanced age, antithrombotic therapy, bleeding diathesis, renal dysfunction, frailty, and prior hip arthroplasty (15). Even long after arthroplasty, residual scar tissue, reduced soft-tissue compliance, and fragile neovascularization may increase susceptibility to rebleeding following minor trauma (15).

In conclusion, this case highlights that not all cases of unilateral leg edema with elevated D-dimer levels are due to DVT. Thorough evaluation with appropriate imaging is essential to avoid misdiagnosis. In our patient, identifying the compressive hematoma and avoiding unnecessary anticoagulation led to a swift and complete recovery. Clinicians should remain vigilant for alternative causes of leg swelling, particularly traumatic hematoma, in elderly patients, and manage them accordingly. Prompt imaging and targeted treatment can prevent potential complications and ensure optimal outcomes.

FUNDING

This work was partially supported by a JSPS Kakenhi Grant (Number 25K02646 to M.S.).

REFERENCES

1. Gasparis AP, Kim PS, Dean SM, Khilnani NM, Labropoulos N : Diagnostic approach to lower limb edema. *Phlebology : The Journal of Venous Disease* 35(9) : 650-5, 2020
2. Fancher TL, White RH, Kravitz RL : Combined use of rapid D-dimer testing and estimation of clinical probability in the diagnosis of deep vein thrombosis : systematic review. *BMJ* 329(7470) : 821, 2004
3. Konstantinides SV, Meyer G, Becattini C, Bueno H, Geersing GJ, Harjola VP, Huisman M V, Humbert M, Jennings CS, Jiménez D, Kucher N, Lang IM, Lankeit M, Lorusso R, Mazzolai L, Meneveau N, Ni Ainle F, Prandoni P, Pruszczyk P, Righini M, Torbicki A, Van Belle E, Zamorano JL, Galié N, Gibbs JSR, Aboyans V, Ageno W, Agewall S, Almeida AG, Andreotti F, Barbato E, Bauersachs J, Baumbach A, Beygui F, Carlsen J, De Carlo M, Delcroix M, Delgado V, Subias PE, Fitzsimons D, Gaine S, Goldhaber SZ, Gopalan D, Habib G, Halvorsen S, Jenkins D, Katus HA, Kjellström B, Lainscak M, Lancellotti P, Lee G, Le Gal G, Messas E, Morais J, Petersen SE, Petronio AS, Piepoli MF, Price S, Roffi M, Salvi A, Sanchez O, Shlyakhto E, Simpson IA, Stortecky S, Thielmann M, Noordegraaf AV, Becattini C, Bueno H, Geersing GJ, Harjola VP, Huisman M V, Humbert M, Jennings CS, Jiménez D, Kucher N, Lang IM, Lankeit M, Lorusso R, Mazzolai L, Meneveau N, Ni Ainle F, Prandoni P, Pruszczyk P, Righini M, Torbicki A, VanBelle E, LuisZamorano J, Windecker S, Aboyans V, Baigent C, Collet JP, Dean V, Delgado V, Fitzsimons D, Gale CP, Grobbee D, Halvorsen S, Hindricks G, Iung B, Jüni P, Katus HA, Landmesser U, Leclercq C, Lettino M, Lewis BS, Merkely B, Mueller C, Petersen SE, Sonia Petronio A, Richter DJ, Roffi M, Shlyakhto E, Simpson IA, Sousa-Uva M, Touyz RM, Hammoudi N, Hayrapetyan H, Mascherbauer J, Ibrahimov F, Polonetsky O, Lancellotti P, Tokmakova M, Skoric B, Michaloliakos I, Hutrya M, Mellemkjaer S, Mostafa M, Reinmets J, Jääskeläinen P, Angoulvant D, Bauersachs J, Giannakoulas G, Zima E, Vizza CD, Sugraliyev A, Bytyçi I, Maca A, Ereminiene E, Huijnen S, Xuereb R, Diaconu N, Bulatovic N, Asfalou I, Bosevski M, Halvorsen S, Sobkowicz B, Ferreira D, Petris AO, Moiseeva O, Zavatta M, Obradovic S, Šimkova I, Radsel P, Ibanez B, Wikström G, Aujesky D, Kaymaz C, Parkhomenko A, Pepke-Zaba J : 2019 ESC Guidelines for the diagnosis and management of acute pulmonary embolism developed in collaboration with the European Respiratory Society (ERS). *Eur Heart J* 41(4) : 543-603, 2020
4. Kabrhel C, Mark Courtney D, Camargo CA, Plewa MC, Nordenholz KE, Moore CL, Richman PB, Smithline HA, Beam DM, Kline JA : Factors Associated With Positive D-dimer Results in Patients Evaluated for Pulmonary Embolism. *Academic Emergency Medicine* 17(6) : 589-97, 2010
5. Yagi S, Nishiyama S, Abe T, Sata M : Recurrent venous thromboembolism after discontinuation of rivaroxaban therapy in a patient with antiphospholipid syndrome. *BMJ Case Rep* 12(1) : bcr-2018-227663, 2019
6. Adam SS, Key NS, Greenberg CS : D-dimer antigen : current concepts and future prospects. *Blood* 113(13) : 2878-87, 2009
7. Ise T, Iwase T, Masuda S, Yagi S, Akaike M, Nishio S, Niki T, Yamaguchi K, Taketani Y, Yamada H, Soeki T, Wakatsuki T, Sata M : Acute pulmonary thromboembolism from deep vein thrombosis induced by trauma to the popliteal vein with a tennis racket. *J Cardiol Cases* 9(4) : 162-4, 2014
8. Shieh AK, Lum ZC, Singh AK, Pereira GC : External iliac vein compression secondary to osteolysis-induced hematoma in total hip arthroplasty. *Arthroplast Today* 5(3) : 279-83, 2019
9. Crowther MA, Warkentin TE : Bleeding risk and the management of bleeding complications in patients undergoing anticoagulant therapy : focus on new anticoagulant agents. *Blood* 111(10) : 4871-9, 2008
10. Yamazaki H, Yagi S, Torii Y, Amano R, Oomichi Y, Sangawa T, Fukuda D, Kadota M, Ise T, Ueno R, Hara T, Kusunose K, Matsuura T, Tobiume T, Yamaguchi K, Yamada H, Soeki T, Wakatsuki T, Akaike M, Sata M : Edoxaban improves acute venous thromboembolism while preserving protein C and protein S levels. *J Cardiol* 71(3) : 305-9, 2018
11. Sharan S, Rahman L, Islam MA, Wong V, Islam MS, Swapnil A, Bhowon A : Point-of-Care Ultrasound in the Diagnosis of Hematoma Mimicking Deep Vein Thrombosis : A Case Report. *Cureus*, 2025
12. Linkins LA, Choi PT, Douketis JD : Clinical Impact of Bleeding in Patients Taking Oral Anticoagulant Therapy for Venous Thromboembolism. *Ann Intern Med* 139(11) : 893-900, 2003
13. Yagi S, Sata M : Rupture of pes anserine bursa in a patient with pes anserine pain syndrome due to osteoarthritis. *The Journal of Medical Investigation* 66(1.2) : 211-2, 2019
14. Al-Rumaih M, Al-Jaber F, Batheeb N : Vascular injuries and complications in orthopedic surgery procedures. *Journal of Orthopaedic Reports* 4(2) : 100435, 2025
15. Pathak N, Bovonratwet P, Purtill JJ, Bernstein JA, Golden M, Grauer JN, Rubin LE : Incidence, Risk Factors, and Subsequent Complications of Postoperative Hematomas Requiring Reoperation After Primary Total Hip Arthroplasty. *Arthroplast Today* 19 : 101015, 2023