

CASE REPORT

Full-endoscopic spine surgery in oldest old patients aged over 90 years : A case report

Kazuya Kishima^{1,2}, Kiyoshi Yagi^{2,3}, Kazuta Yamashita², Fumitake Tezuka², Masatoshi Morimoto², Yoichiro Takata², Toshinori Sakai², Toru Maeda², and Koichi Sairyo²

¹Department of Orthopedic Surgery, Hyogo College of Medicine, Hyogo, Japan, ²Department of Orthopedics, Tokushima University, Tokushima, Japan, ³Department of Orthopedic Surgery, Nagoya City University, Aichi, Japan

Abstract : Background : Transforaminal full-endoscopic spine surgery (FESS) is the least invasive spinal surgery and can be performed under local anesthesia. In Japan, the population is rapidly aging and the number of spinal surgeries performed in the elderly is also increasing. **Object :** In this report, we describe 3 patients aged 90 years or older in whom we performed FESS under local anesthesia. **Case :** The first case was a 90-year-old man who presented with severe leg pain. He had multiple medical comorbidities and was unsuitable for general anesthesia. We performed FESS. After surgery, the leg pain resolved with full recovery of muscle strength. He was discharged with no perioperative complications. The second case was a 90-year-old man who presented with severe leg pain. MRI showed a herniated nucleus pulposus and foraminal stenosis at L4/5. We performed FESS. The leg pain improved immediately after surgery. The third case was a 91-year-old woman in whom we diagnosed left L5 radiculopathy due to foraminal stenosis at L5/S1. After surgery, her leg pain was relieved. **Conclusion :** FESS is a good surgical procedure for elderly patients who are in a poor general condition because it is minimally invasive and can be performed under local anesthesia with early mobilization. *J. Med. Invest.* 71 : 169-173, February, 2024

Keywords : full-endoscopic spine surgery, oldest old patients, over 90 years old, lumbar spinal stenosis

INTRODUCTION

Japanese society is rapidly aging, with 28.8% of the total population now aged 65 years or older and 1.9% aged over 90 years. The number of spine surgeries for the elderly is also increasing (1) due to advances in medical technology and minimal invasiveness of these procedures.

Spinal surgery is generally performed under general anesthesia. However, the number of patients with lumbar spinal stenosis (LSS) who cannot safely undergo general anesthesia due to advanced age or medical comorbidities is likely to increase in the future. The postoperative mortality rate is reported to be high in elderly patients who undergo general anesthesia (2, 3). Therefore, there is a need for a spinal decompression method that can be performed under local anesthesia (4). We have performed full-endoscopic spine surgery (FESS) using a transforaminal approach under local anesthesia for herniated nucleus pulposus (NHP) and LSS (5-7). This technique allows the surgeon to operate through a skin incision of only 8 millimeters with little or no damage to the back muscles, and preserves the mobility of the lumbar spine (7-9).

The pathophysiology of LSS can be divided into central canal stenosis, lateral recess stenosis, and foraminal stenosis (10, 11). We perform transforaminal full-endoscopic lumbar undercutting laminectomy for central canal stenosis (4), full-endoscopic ventral facetectomy (FEVF) for lateral recess stenosis (5, 12), and full-endoscopic lumbar foraminotomy (FELF) for foraminal stenosis (13-15).

Here, we describe 3 patients aged 90 years or older in whom we

have performed FESS using a transforaminal approach under local anesthesia.

CASE REPORTS

From December 2013 to October 2019, we performed 385 FESS procedures in our hospital. Of these, 3 (0.8%) were patients aged 90 years or older (reported in this paper), 38 were aged 80-89 years (9.9%), and 57 were aged 70-79 years (14.8% ; Fig 1).

Case 1

A 90-year-old man came to our hospital with the chief complaint of severe low back pain and right leg pain. The visual

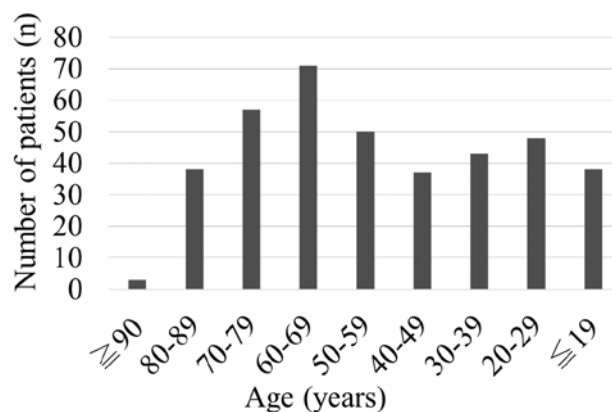


Fig 1. Graph showing the age distribution of patients who underwent full-endoscopic spine surgery at our hospital from December 2013 to October 2019. Three (0.8%) of these procedures were performed in patients aged 90 years or older.

Received for publication August 29, 2023 ; accepted October 1, 2023.

Address correspondence and reprint requests to Kazuya Kishima, MD, PhD, Assistant Professor, Department of Orthopedic Surgery, Hyogo College of medicine, 1-1 Mukogawa-cho, Nishinomiya, Hyogo 663-8501, Japan and Fax : +81-798-45-6453. E-mail : kazuya99@live.jp

analog scale (VAS) for low back pain and leg pain was 100/100. Conservative treatment with oral medication had been ineffective because of side effects of nausea and drowsiness. He had multiple comorbidities, including chronic kidney disease, heart failure, and chronic obstructive pulmonary disease. He also had hyperkalemia and a history of cerebral infarction. He was taking antiplatelet medication and had been assessed by an anesthesiologist as unsuitable for general anesthesia.

Physical examination revealed manual muscle test (MMT) 4/5 weakness of the right tibialis anterior and extensor digitorum longus muscles. Sensory and deep tendon reflexes were normal. Dynamic plain radiographs of the lumbar spine showed mild segmental instability at L4/5 and disc narrowing at L5/S1 (Fig 2A, B). Sagittal and axial views on magnetic resonance imaging (MRI) scans showed a dorsally migrated HNP that was localized on the right posterolateral and thickening of the ligamentum flavum at L4/5 (Fig 2C, D).

Reproducibility and an analgesic effect were confirmed by performing a selective right L5 nerve root block. The diagnosis was LSS with HNP at L4/5. The patient was not indicated for general anesthesia due to severe complications. Therefore, we performed full-endoscopic discectomy (FED) and FEVF using a transforaminal approach under local anesthesia. First, we created a surgical portal via an 8-mm skin incision 7 cm to the right of the midline and placed a cannula on the facet bone via the transforaminal approach. Next, we identified and resected the superior articular process and partially resected the inferior articular process using a high-speed drill. After removing the bulging nucleus pulposus from the outside, and we also removed the thickened ligament flavum that was compressing

the traversing nerve. Finally, we confirmed that the traversing nerve was decompressed. Postoperative images are shown in Fig 2E-G. The operating time was 55 min and there was no measurable blood loss.

The leg pain was disappeared immediately after surgery and muscle strength was fully recovered within a few days. At the final follow-up visit 2 years after surgery, the VAS scores were 30/100 for low back pain and 0/100 for leg pain and numbness.

Case 2

A 90-year-old man was referred to our hospital for investigation and treatment of severe left leg pain. There were comorbidities, including diabetes mellitus, hypertension, chronic kidney disease, chronic obstructive pulmonary disease, and smoking. Therefore, he was considered unsuitable for general anesthesia. MRI showed HNP at L4/5 (Fig 3A) and left-sided foraminal stenosis at L4/5 (Fig 3B). Computed tomography (CT) scans showed bony foraminal stenosis on the left at L4/5 (Fig 3C, G). Reproducibility and an analgesic effect was confirmed by an L4 and L5 nerve root block. We diagnosed left L4 and L5 radiculopathy due to lateral recess stenosis and foraminal stenosis at L4/5. We performed FEVF for lateral recess stenosis (Fig 3F) and FELF for foraminal stenosis (Fig 3D, H) at L4/5 under local anesthesia. Using the TF approach, the exiting and traversing nerve can be confirmed to be decompressed by completely resecting the SAP and resecting the ligamentum flavum. The leg pain resolved after surgery. At the final follow-up visit 12 months later, the good outcome was maintained and he was able to walk with a T-cane.

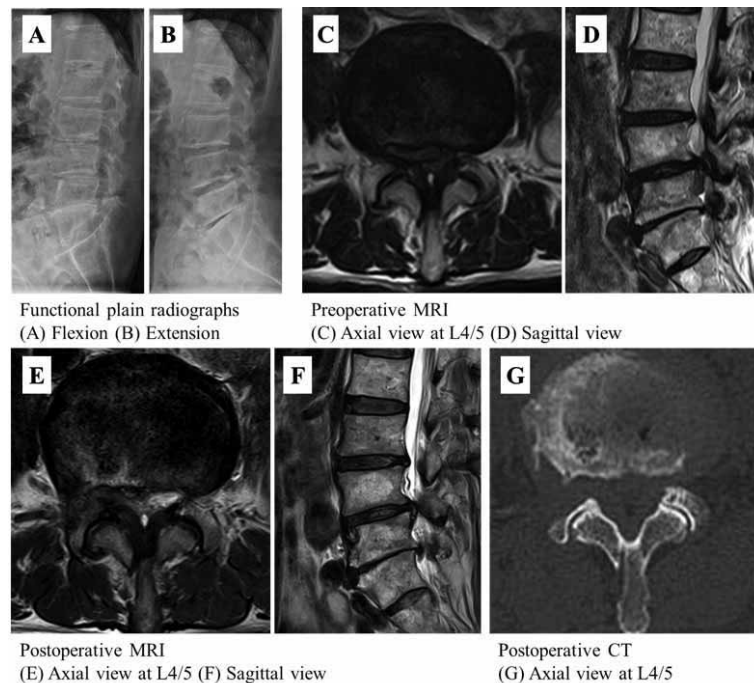


Fig 2. Case 1. Preoperative plain radiographs obtained in flexion (A) and extension (B) show mild segmental instability at L4/5 and disc narrowing at L5/S1. (C, D) Preoperative sagittal and axial MRI scans show a dorsally migrated herniated nucleus pulposus that is localized on the right posterolateral and a thickened ligamentum flavum at L4/5. (E, F) Postoperative sagittal and axial MRI scans confirm that the downward migrated herniated nucleus pulposus has been discectomized. (G) Postoperative axial CT scan at L4/5 confirms removal of the right superior articular process by foraminoplasty using a high-speed drill. 3D, 3-dimensional; MRI, magnetic resonance imaging; CT, computed tomography

Case 3

A 91-year-old woman visited our hospital complaining of severe left leg pain. She had undergone 2 spinal surgical procedures under general anesthesia in the past but had found the recovery period difficult. Therefore, she was reluctant to undergo further spinal surgery under general anesthesia.

MRI and CT scans showed left-sided foraminal stenosis at L5/S1 (Fig 4A-D). Reproducibility and an analgesic effect were confirmed by an L5 nerve root block. We diagnosed left-sided L5 radiculopathy due to foraminal stenosis at L5/S1 and performed FELF under local anesthesia. Postoperative images are shown in Fig 4E-G. The leg pain resolved after surgery but there was some residual numbness.

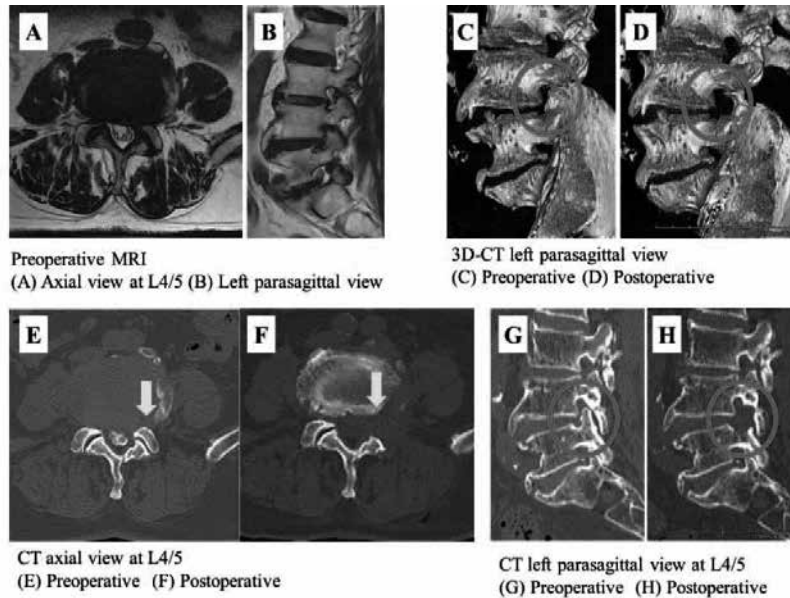


Fig 3. Case 2. (A) Preoperative axial MRI scan shows a herniated nucleus pulposus at L4/5. (B) Preoperative sagittal MRI scan shows foraminal stenosis on the left side at L4/5. (E, F) Axial CT scan at L4/5 confirms complete resection of the superior articular process (arrow) and enlargement of the lateral recess after surgery. (C, G) Preoperative 3D (C) and sagittal (G) CT scans show left-sided bony foraminal stenosis at L4/5. (D, H) Postoperative 3D (D) and sagittal (H) CT scans confirm total resection of the superior articular process and partial resection of the L5 pedicle (circle), resulting in enlargement of the L4/5 foramen after surgery. 3D, 3-dimensional; MRI, magnetic resonance imaging; CT, computed tomography

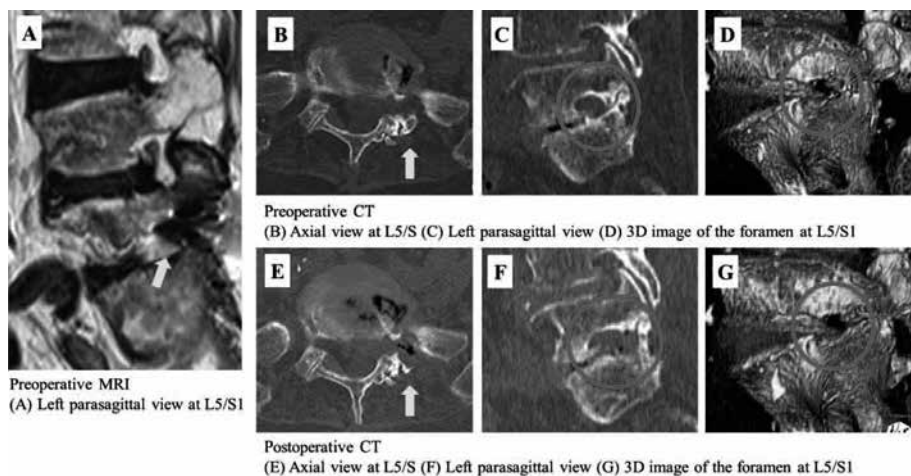


Fig 4. Case 3. (A) Left parasagittal MRI scan shows narrowing of the foramen at L5/S1. (B-D) Preoperative axial scan at L5/S1 and parasagittal and 3D CT scans show foraminal stenosis on the left side at L5/S1. (E-G) Postoperative axial scan at L5/S1 and parasagittal and 3D CT scans confirm partial resection of superior and inferior articular processes on the left, resulting in enlargement of the L5/S1 foramen after surgery. 3D, 3-dimensional; MRI, magnetic resonance imaging; CT, computed tomography

DISCUSSION

In these 3 cases, we performed FESS in oldest old patients aged 90 years or older under local anesthesia and awake and aware conditions. All cases had a favorable clinical outcome with no perioperative complications.

Spinal surgery for elderly patients

The overall complication rate for decompression surgery for LSS has been reported to range from 6% to 52% (16-18) and a major complication rate of 35% in patients aged 80 years or older with LSS (19). In a study of 8033 elderly patients with LSS by Imajo *et al.*, there was no significant difference in the incidence of surgical complications between patients aged 65-79 and those aged 80 and older, but there was a significant difference in the incidence of general complications between patients aged 65-79 and those aged 80 and older (20). Another study by Carreon *et al.* concluded that the risk of surgical complications increased by age (21).

Given that the above-mentioned studies were in patients over 80 years of age, it could be expected that there would be an even greater risk of complications in those aged 90 years and older. In a study of 108,419 patients by Smith *et al.*, the 60-day mortality rate after spinal surgery increased from 2.8 per 1000 in patients aged 60-69 years to 6.1 and 34.3 per 1000 in those aged 80-89 years and 90 years or older, respectively (22). The increased mortality rates in that study were associated with a higher American Society of Anesthesiologists score, spinal fusion, and implants use. Moreover, it has been reported that the mortality rate is higher with general anesthesia than with regional anesthesia (2, 3) and that the mortality risk is particularly high in patients with respiratory complications (23-25). All these reports suggest that patients over the age of 90 years who undergo spinal surgery are at high risk of surgical and general complications and of postoperative mortality. However, with the increasing proportion of elderly people in the population, the demand for spinal surgery in oldest old people is likely to increase in the future. We believe that performing FESS under local anesthesia can avoid unnecessary fusion surgery in oldest old patients and reduce the invasiveness of surgery and the hazards of anesthesia.

Full-endoscopic spine surgery

FESS was originally developed as a FED for HNP, but with the evolution of surgical instruments, its application has been expanded to LSS, and good results have been reported (26).

FESS is a minimally invasive spinal surgery (4) that needs only an 8-mm skin incision, causes minimal damage to the back muscles (5, 9) and relatively mild postoperative wound pain, and is reported to allow more rapid recovery, rehabilitation, and return to daily activity (27-29). Furthermore, one of the major advantages is that there is less bleeding. FESS can be performed via an interlaminar or transforaminal approach, and the transforaminal approach allows the surgery to be performed under local anesthesia. We perform FESS using the transforaminal approach under local anesthesia with the patient awake and aware. Furthermore, patients are able to get out of bed 2 hours after surgery, which is not possible on the day of surgery under general anesthesia. Early mobilization decreases the risk of delirium (30) and muscle weakness, which are postoperative complications peculiar to the elderly. It has also been reported that reducing the doses of sedating and analgesic agents decreases the risk of delirium (30), which is a further advantage of FESS under local anesthesia.

CONCLUSION

Here, we report 3 cases of FESS performed in oldest old patients aged over 90 years, none of whom had postoperative complications. Patients in this age group are at particularly high risk for surgical and general complications. FESS is a good surgical option, if indicated, for the elderly and those in poor health overall because it is minimally invasive, can be performed under local anesthesia, and allows early mobilization, which may lead to earlier discharge and decrease the risk of complications and mortality.

CONFLICT OF INTEREST

none declared.

REFERENCES

1. Nohara Y, Taneichi H, Ueyama K, Kawahara N, Shiba K, Tokuhashi Y, Tani T, Nakahara S, Iida T : Nationwide survey on complications of spine surgery in Japan. *J. Orthop. Sci.* 9 : 424-33, 2004
2. Rasmussen LS, Johnson T, Kuipers HM, Kristensen D, Siersma V. D, Vila P, Jolles J, Papaioannou A, Abildstrom H, Silverstein JH, Bonal JA, Raeder J, Nielsen IK, Korttila K, Munoz L, Dodds C, Hanning CD, Moller JT : Does anaesthesia cause postoperative cognitive dysfunction? A randomised study of regional versus general anaesthesia in 438 elderly patients. *Acta Anaesthesiol. Scand.* 47 : 260-6, 2003
3. Urwin SC, Parker MJ, Griffiths R : General versus regional anaesthesia for hip fracture surgery : a meta-analysis of randomized trials. *Br. J. Anaesth.* 84 : 450-5, 2000
4. Sairyo K, Yamashita K, Manabe H, Ishihama Y, Sugiura K, Tezuka F, Takata Y, Sakai T, Omichi Y, Takamatsu N, Hashimoto A, Maeda T : A novel surgical concept of transforaminal full-endoscopic lumbar undercutting laminectomy (TE-LUL) for central canal stenosis of the lumbar spine with local anesthesia : A case report and literature review. *J. Med. Invest.* 66 : 224-9, 2019
5. Sairyo K, Chikawa T, Nagamachi A : State-of-the-art transforaminal percutaneous endoscopic lumbar surgery under local anesthesia : Discectomy, foraminoplasty, and ventral facetectomy. *J. Orthop. Sci.* 23 : 229-36, 2018
6. Yeung AT, Tsou PM : Posterolateral endoscopic excision for lumbar disc herniation : Surgical technique, outcome, and complications in 307 consecutive cases. *Spine (Phila Pa 1976)* 27 : 722-31, 2002
7. Sairyo K, Nagamachi A : State-of-the-art management of low back pain in athletes : Instructional lecture. *J. Orthop. Sci.* 21 : 263-72, 2016
8. Kamada M, Manabe H, Yamashita K, Sakai T, Maeda T, Sairyo K : Full-endoscopic Decompression of Foraminal Stenosis Caused by Facet Hypertrophy Contralateral to the Dominant Hand in a Baseball Pitcher : A Case Report. *NMC Case Rep J* 7 : 173-7, 2020
9. Choi G, Lee SH, Lokhande P, Kong B. J, Shim C. S, Jung B, Kim JS : Percutaneous endoscopic approach for highly migrated intracanal disc herniations by foraminoplastic technique using rigid working channel endoscope. *Spine (Phila Pa 1976)* 33 : E508-15, 2008
10. Truumees E : Spinal stenosis : pathophysiology, clinical and radiologic classification. *Instr. Course Lect.* 54 : 287-302, 2005

11. Steurer J, Roner S, Gnannt R, Hodler J : Quantitative radiologic criteria for the diagnosis of lumbar spinal stenosis : a systematic literature review. *BMC Musculoskelet. Disord.* 12 : 175, 2011
12. Sairyo K, Higashino K, Yamashita K, Hayashi F, Wada K, Sakai T, Takata Y, Tezuka F, Morimoto M, Terai T, Chikawa T, Yonezu H, Nagamachi A, Fukui Y : A new concept of transforaminal ventral facetectomy including simultaneous decompression of foraminal and lateral recess stenosis : Technical considerations in a fresh cadaver model and a literature review. *J. Med. Invest.* 64 : 1-6, 2017
13. Yamashita K, Higashino K, Sakai T, Takata Y, Hayashi F, Tezuka F, Morimoto M, Chikawa T, Nagamachi A, Sairyo K : Percutaneous full endoscopic lumbar foraminoplasty for adjacent level foraminal stenosis following vertebral intersegmental fusion in an awake and aware patient under local anesthesia : A case report. *J. Med. Invest.* 64 : 291-5, 2017
14. Henmi T, Terai T, Hibino N, Yoshioka S, Kondo K, Goda Y, Tezuka F, Sairyo K : Percutaneous endoscopic lumbar discectomy utilizing ventral epiduroscopic observation technique and foraminoplasty for transligamentous extruded nucleus pulposus : technical note. *J. Neurosurg. Spine* 24 : 275-80, 2016
15. Ahn Y, Oh HK, Kim H, Lee SH, Lee HN : Percutaneous endoscopic lumbar foraminotomy : an advanced surgical technique and clinical outcomes. *Neurosurgery* 75 : 124-33 ; discussion 32-3, 2014
16. Nanjo Y, Nagashima H, Dokai T, Hamamoto Y, Hashiguchi H, Ishii H, Kameyama Y, Morio Y, Murata M, Tanida A, Tanishima S, Teshima R : Clinical features and surgical outcomes of lumbar spinal stenosis in patients aged 80 years or older : a multi-center retrospective study. *Arch. Orthop. Trauma Surg.* 133 : 1243-8, 2013
17. Shabat S, Arinzon Z, Folman Y, Leitner J, David R, Pevzner E, Gepstein R, Pekarsky I, Shuval I : Long-term outcome of decompressive surgery for lumbar spinal stenosis in octogenarians. *Eur. Spine J.* 17 : 193-8, 2008
18. Galiano K, Obwegeser AA, Gabl MV, Bauer R, Twerdy K : Long-term outcome of laminectomy for spinal stenosis in octogenarians. *Spine (Phila Pa 1976)* 30 : 332-5, 2005
19. Raffo CS, Lauerma WC : Predicting morbidity and mortality of lumbar spine arthrodesis in patients in their ninth decade. *Spine (Phila Pa 1976)* 31 : 99-103, 2006
20. Imajo Y, Taguchi T, Neo M, Otani K, Ogata T, Ozawa, Miyakoshi N, Murakami H, Iguchi T : Complications of spinal surgery for elderly patients with lumbar spinal stenosis in a super-aging country : An analysis of 8033 patients. *J. Orthop. Sci.* 22 : 10-5, 2017
21. Carreon LY, Puno RM, Dimar JR, 2nd, Glassman SD, Johnson JR : Perioperative complications of posterior lumbar decompression and arthrodesis in older adults. *J. Bone Joint Surg. Am.* 85 : 2089-92, 2003
22. Smith JS, Shaffrey CI, Sansur CA, Berven SH, Fu KM, Broadstone PA, Choma TJ, Goytan MJ, Noordeen HH, Knapp DR Jr, Hart RA, Donaldson WF 3rd, Polly DW Jr, Perra JH, Boachie-Adjei O ; Scoliosis Research Society Morbidity and Mortality Committee : Rates and causes of mortality associated with spine surgery based on 108,419 procedures : a review of the Scoliosis Research Society Morbidity and Mortality Database. *Spine (Phila Pa 1976)* 37 : 1975-82, 2012
23. Chou SE, Rau CS, Tsai YC, Hsu SY, Hsieh HY, Hsieh CH : Risk factors and complications contributing to mortality in elderly patients with fall-induced femoral fracture : A cross-sectional analysis based on trauma registry data of 2,407 patients. *Int. J. Surg.* 66 : 48-52, 2019
24. Rock P, Rich PB : Postoperative pulmonary complications. *Curr. Opin. Anaesthesiol.* 16 : 123-31, 2003
25. Chung JY, Chang WY, Lin TW, Lu, JR, Yang MW, Lin CC, Chang CJ, Chou AH : An analysis of surgical outcomes in patients aged 80 years and older. *Acta Anaesthesiol. Taiwan* 52 : 153-8, 2014
26. Kishima K, Yagi K, Yamashita K, Tezuka F, Morimoto M, Takata Y, Sakai T, Maeda T, Sairyo K : Transforaminal Full-Endoscopic Ventral Facetectomy : Midterm Results and Factors Associated with Poor Surgical Outcomes. *J Neurol Surg A Cent Eur Neurosurg.* 11, 2023
27. Fujii Y, Yamashita K, Sugiura K, Ishihama Y, Manabe H, Tezuka F, Takata Y, Sakai T, Maeda T, Sairyo K : Early return to activity after minimally invasive full endoscopic decompression surgery in medical doctors. *J Spine Surg* 6 : S294-S9, 2020
28. Tsou PM, Alan Yeung C, Yeung AT : Posterolateral transforaminal selective endoscopic discectomy and thermal annuloplasty for chronic lumbar discogenic pain : a minimal access visualized intradiscal surgical procedure. *Spine J* 4 : 564-73, 2004
29. Sugiura K, Yamashita K, Manabe H, Ishihama Y, Tezuka F, Takata Y, Sakai T, Maeda T, Sairyo K : Prompt return to work after bilateral transforaminal full-endoscopic lateral recess decompression under local anesthesia : A case report. *J Neurol Surg A Cent Eur Neurosurg.* 82(3) : 289-293, 2021
30. Arizumi F, Maruo K, Kusuyama K, Kishima K, Tachibana T : Efficacy of Intervention for Prevention of Postoperative Delirium after Spine Surgery. *Spine Surg Relat Res.* 5(1) : 16-21, 2020