

CASE REPORT

A case of complete decapitation in suicidal hanging : the mechanism and condition of decapitation

Asuka Ito¹, Hideyuki Nushida¹, Hiromitsu Kurata^{1,2}, Hitomi Umemoto^{1,3}, Hirofumi Iseki^{1,2}, Itsuo Tokunaga¹, and Akiyoshi Nishimura¹

¹Department of Forensic Medicine, Institute of Biomedical Sciences, Tokushima University Graduate School, Tokushima, Japan, ²Department of Physical Medicine, Nakazu-Yagi Hospital, Tokushima, Japan, ³Education Support Room for Anatomy, Tokushima University Faculty of Medicine, Tokushima, Japan

Abstract : Complete decapitation due to suicide by hanging is rare. We report the case of a decapitated man who was found in the sea near an estuary. A polyethylene rope was tied to the handrail of the bridge across a strait near the site of the body. The rope was 12 mm in diameter and 19 m in length from the handrail. It ended with a slip knot noose, and skin and mustache-like hair fragments were attached to it. The decapitated head was not found. The deceased weighed 82 kg and was 152 cm long without the head. The autopsy revealed coarse abrasions and intramuscular hemorrhage around the severed edge. The third cervical spine was not fractured. We reviewed the literature and suggested the conditions of body weight, fall height, rope diameter, and number of rolls in cases of decapitation by hanging. We calculated the hanging decapitation index (HDI) as the fall height (m) multiplied by the body weight (kg), divided by the rope diameter (mm), divided by the number of rolls ; and discussed the differences between complete and incomplete decapitation cases. *J. Med. Invest.* 70:290-293, February, 2023

Keywords : Decapitation, Hanging, Suicide, Case report, Forensic medicine

INTRODUCTION

Hanging is one of the most popular methods of suicide all over the world (1) ; however, complete decapitation in suicidal hanging is rare. 28 cases have been reported in the literatures (2-21) ; the biomechanism of decapitation was suggested in terms of axial traction concerning body weight, and drop height was predominant compared to rope thickness (10). We reviewed the past literature reporting complete decapitation in suicidal hanging and focused not only on body weight and drop height but also on rope diameters and number of rolls. We propose to calculate the hanging decapitation index from body weight, drop height, rope diameter, and number of rolls.

CASE REPORT

A decapitated man in his 50s was found in the sea near an estuary. A polyethylene rope was tied to the handrail of the bridge across a strait near the site of the body. The rope was 12 mm in diameter and 19 m in length from the handrail. The tip of the rope was looped from the beginning so that it could be hung on the projection of a truck bed ; it ended with a slip knot noose, and skin and mustache-like hair fragments were attached to it (Fig. 1). The decapitated head was not found. The deceased weighed 82 kg and was 152 cm long without the head. Postmortem hypostasis was slightly visible on the posterior side. The autopsy showed full circumferential coarse abrasions (up to 3 cm wide) and subcutaneous and intramuscular hemorrhages around the severed

edge (Fig. 2, 3). The spine was transected between the second and the third cervical vertebrae. The third cervical spine was not fractured. Blood aspiration was not observed in the larynx and trachea. Simon's sign was not observed. The heart weighed 396 g and contained no blood in its lumen. Small white fibrotic nests were observed on the split surface of the myocardium. The left coronary artery was strongly sclerosed, and the stents had been implanted in its lumen. The various organs were pale.

DISCUSSION

The incidence of complete decapitation in suicidal hanging

Long drop hanging has been reported to result in decapitation in judicial hanging since the 19th century (22). Hanging has




Fig 1. The synthetic rope was 12 mm thick. The tip was looped from the beginning so that it could be hung on the projection of a truck bed, and it ended with a slip knot noose (A). Skin and mustache-like hair fragments (white arrow heads) were attached to it (B).

Received for publication November 18, 2022 ; accepted January 6, 2023.

Address correspondence and reprint requests to Asuka Ito, Department of Forensic Medicine, Institute of Health Biosciences, Tokushima University Graduate School, 3-18-15, Kuramotocho, Tokushima, 770-8503, Japan and Fax : +81 88 633 7508. E-mail : a-ito@tokushima-u.ac.jp

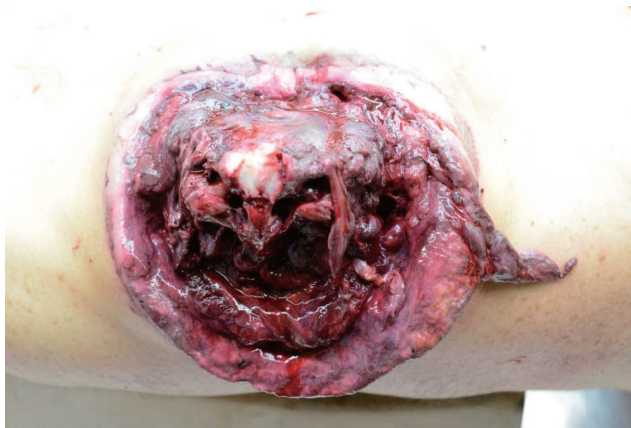

Fig 2. Superior view of the torso. Circumferential abrasion around the severance edge is visible.

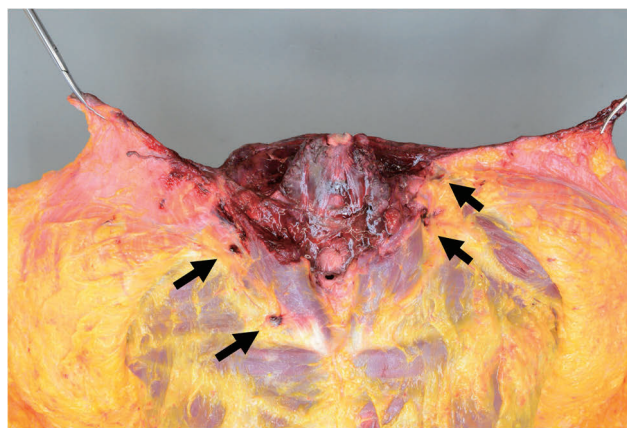

Fig 3. Subcutaneous view of the neck. Arrows indicate subcutaneous hemorrhage.

been the most popular method of suicide in the world ; however, cases of complete decapitation in suicide hanging are rare (1). 28 cases of complete decapitation in suicidal hanging have been reported in the literatures (2-21). Byard *et al.* reported that the incidence of decapitation in suicidal hanging was 0.2% (3/1446) in their series (20). The reported common conditions of hanging decapitation are long drop hanging, heavy body weight, and thin rope. Some reports have also mentioned a slip knot (12, 14, 21). Notably, all victims were male, which may indicate a long drop hanging as violent behavior.

Biomechanisms of hanging decapitation

The biomechanisms of hanging decapitation have been discussed, and the necessary conditions for hanging decapitation have been reported to be heavy body weight, thin inelastic rope, and falling from a great height in previous case reports (2, 4, 7). Rabl *et al.* (7) first introduced the mechanical parameter, that is, the axial traction force, which is calculated using the body mass and fall height. They also reported that an axial traction force greater than 12,000 N resulted in beheading, regardless of rope thickness. Several reports of hanging decapitation have used the concept of traction force to explain the mechanism of decapitation, but no threshold has been suggested (9, 10, 14, 15, 17, 21).

Raja and Sivaloganathan (8) mentioned that the rapidly tightening rope acted like a Gigli saw, which is used in craniotomy procedures. This suggests that the tightening rope generated concentric radial pressure, crushing, and cutting forces. The crushing and cutting effects on the skin and tissues of the neck also helped to sever it. This mechanism of decapitation resembled a case of suicide in which the individual put a nylon rope around the neck, tied the other end to a fixed steel pole, and then drove a car fast (16, 23).

Rothschild and Schneider (10) discussed the mechanisms of hanging decapitation in terms of the axial traction and the radial pressure of the tightening noose. The radial pressure force was twice pi ($\times 6.28$) of axial traction force (4, 7). However, the severance plane did not correspond to the circumference of the skin abrasion ; therefore, they concluded that axial traction was the predominant force in the decapitation procedure.

Morild and Lilleng (16) cast doubt on the calculation of axial traction and radial pressure forces. There was no significant difference between the calculated forces of the complete and incomplete decapitation cases (24). However, they agreed that potential energy is related to fall height and body weight. Potential energy (J) was calculated as the body weight (kg) multiplied

by the fall height (m) multiplied by the gravitational acceleration (m/sec^2). In judicial hanging, ideal hanging means immediate unconsciousness without decapitation, and 1700 J is considered a suitable amount of energy (25).

Difference in the severance edge due to force application

We observed severance edge and circumferential neck abrasion caused by the rope. There were two patterns in relation to the severance edge and the abrasion. The one was when the abrasion coincided with the severance edge. The other was when the skin valve remained caudal to the abrasion in the posterior neck. We assumed that in the former case, the tightening noose cut or crushed the skin around the whole neck by radial pressure force ; in the latter case, the remaining posterior part of the skin was torn by the axial traction force. The skin of the neck was found to be one of the strongest parts against tension, and the tensile strength was reported to be approximately 150 Newton per 1 cm of skin width (7). This means that if 4 cm-wide skin remained, a person weighting over 60 kg might have torn off the skin only by self-weight without falling. In the present case, full circumferential abrasion was observed at the severance edge. The rope diameter was small, and the knot was a slipknot, suggesting that a strong radial pressure was exerted.

Comparison of complete and incomplete decapitation cases

The biomechanism of hanging decapitation was undoubtedly a mixture of axial traction and radial tightening forces ; however, the proportions varied from case to case. The force calculated in the past literature was uncertain ; however, we did not dispute the potential energy before the fall being transferred to the energy of axial traction, stretch of rope, tightening of the noose, and heat by friction (26). The energy to sever the neck was proportional to body weight and fall height and inversely proportional to the area of the rope in contact with the neck. Using this principle, we attempted to calculate the hanging decapitation index (HDI), that is, the fall height (m) multiplied by the body weight (kg), divided by the rope diameter (mm), divided by the number of rolls. Table 1 shows 21 cases of complete decapitation by suicidal hanging whose body weight, fall height, rope thickness, and number of rolls are clear from the literature. In our case, the HDI was 137.75, which was very high. This appeared to be related to the very long drop distance (19 m). In contrast, seven cases of hanging resulting in incomplete decapitation have been reported in the literature (8, 17, 24, 26-29). One was judicial hanging (26), and the others were suicidal hanging. Table 2 lists

Table 1. Complete hanging decapitation cases

No.	Sex, Age	Body weight (kg)	Fall height (m)	Rope diameter (mm)	Roll	Severance edge	Potential energy (J)	HDI	Author
1	M, -	50	5.6	15	1	-	2,766	18.80	Takahashi (3)
2	M, 46	76	3.5	10	1	DSF	2,609	26.60	Pankratz (4)
3	M, 54	80	2.4	10	1	-	1,884	19.20	Pollak (6)
4	M, 38	63	10.0	15	1	-	6,180	42.00	Pollak (6)
5	M, 52	90	3.8	12	1	DSF	3,355	28.50	Rabl (7)
6	M, 22	87.5	4.5	13	1	CA	3,863	30.29	Tracqui (9)
7	M, 47	144	2.3	20	1	DSF	3,249	16.56	Rothschild (10)
8	M, 48	80	1.4	10	1	-	1,059	10.80	Matschke (11)
9	M, 59	54	3.7	10	1	DSF	1,960	19.98	Zhu (12)
10	M, 52	89	3.5	20	1	DSF	3,056	15.58	Tsokos (13)
11	M, 42	92	8.1	4	1	CA	7,310	186.30	Tsokos (13)
12	M, 65	74	3.6	10	1	CA	2,613	26.64	Dedouit (14)
13	M, 71	75	4.5	9	1	DSF	3,311	37.50	Kim (15)
14	M, Young	109	3.5	12	1	CA	3,743	31.79	Morild (16)
15	M, 29	105	4.7	12	1	-	4,821	40.95	Hejna (17)
16	M, 54	80	2.4	10	1	-	1,884	19.20	Hejna (17)
17	M, 27	95	3.2	10	1	-	2,982	30.40	Hejna (17)
18	M, 49	53	3.5	10	1	DSF	1,820	18.55	Jang (19)
19	M, 50	74	7.2	10	1	DSF	5,227	53.28	Jang (19)
20	-, -	76.5	4.2	11	1	CA	3,152	29.21	Russo (21)
21	M, 50s	82+5 ^a	19	12	1	CA	16,216	137.75	Our case

HDI : hanging decapitation index, DSF : dorsal skin flap, CA : circumference ablation

^a : The head was missing in our case, so the typical weight (5 kg) of an adult head was added to the body weight.

Table 2. Incomplete hanging decapitation cases

No.	Sex, Age	Body weight (kg)	Fall height (m)	Rope diameter (mm)	Roll	Potential energy (J)	HDI	Author
1	M, 65	85	3	13	1	2,502	19.62	Holczebek (27)
2	M, 40	73	3.8	20	1	2,721	13.87	Weigel (29)
3	M, 52	95	3.1	15	2	2,889	9.82	Töró (26)
4	M, 47	100	2.6	15	2	2,551	8.67	Hejna (17)
5	-, -	85	5	10	2	4,169	21.25	Leccia (24)

HDI : hanging decapitation index

five cases of incomplete decapitation by hanging with certain data. From these studies, including our case, we calculated the potential energy and HDI, and compared the complete and incomplete decapitation cases. In potential energy, there was no significant difference between complete and incomplete decapitation, while in HDI, complete decapitation was significantly higher at $P < 0.05$ by T-test. This HDI does not determine the threshold at which decapitation occurs; other factors, such as the elasticity of the rope, the position of the rope on the neck, the type of knot noose, and individual differences in the durability of the cervical tissue also come into play. However, body weight, fall distance, rope diameter, and number of rolls, which are the basis for calculating the HDI, are the most important factors in hanging decapitation.

CONFLICTS OF INTEREST

The authors have no conflicts of interest to declare.

REFERENCES

1. World Health Organization. Newsroom. Fact sheets. Detail. Suicide. 2021. Available at : <https://www.who.int/newsroom/fact-sheets/detail/suicide>. Accessed May 11, 2022
2. Weinmann W, Prokop O : Atlas der gerichtlichen Medizin. Verlag Volk und Gesundheit, Berlin, 1963, pp.210
3. Takahashi F, Suzuki T, Sato K, Yamamiya S : Decapitation in hanging : a case report (in Japanese). Res Pract Forensic Med 14 : 67-70, 1970

4. Pankratz H, Schuller E, Josephi E : Dekapitation beim Erhängen. Arch Kriminol 178 : 157-161, 1986
5. Urban R, Kleemann W, Tröger HD : Ungewöhnliche Tattort- und Obduktionsbefunde-Unfall, Suizid oder Gewaltwirkung durch dritte Hand. Klose W, Oehmichen WM eds. Festschrift zum 70. Geburtstag für Prof. Dr. med. Dipl.-Chem. Otto Pribilla. Schmidt-Römhild, Lübeck, 1990, pp.463-469
6. Pollak S, Stellweg-Carion C : Befundmuster bei Dekapitation durch Stagwerkzeuge. Schütz H, Kaatsch HJ, Thomsen H eds. Medizinrecht-Psychopathologie-Rechtmedizin. Springer, Berlin Heidelberg, 1991, pp.517-526.
7. Rabl W, Haid C, Katzgraber F, Walser B : Erhängen mit Dekapitation: Kasuistik—Biomechanik. Arch Kliminol 195 : 31-37, 1995
8. Raja V, Siraloganathan S. Decapitation – a rare complication in hanging. Med Sci Law 37 : 81-83, 1997
9. Tracqui A, Fonmartin K, Géraut A, Pennera D, Doray S, Ludes B : Suicidal hanging result in complete decapitation : a case report. Int J Leg Med 112 : 55-57, 1998
10. Rothschild MA, Schneider V : Decapitation as a result of suicidal hanging. Forensic Sci Int 106 : 55-62, 1999
11. Matschke J, Hildebrand E, Püschel K : An extraordinary case of death – decapitation via hanging in a murder – suicide. Kliminalistik 53 : 687-688, 1999
12. Zhu BL, Quan L, Ishida K, Oritani S, Taniguchi M, Fujita MQ, Fukita K, Maeda H : Decapitation in suicidal hanging – a case report with a review of the literature. Legal Med (Tokyo) 2 : 159-162, 2000
13. Tsokos M, Trürk EE, Uchigasaki S, Püschel K : Pathological features of suicidal complete decapitation. Forensic Sci Int 139 : 95-102, 2004
14. Dedouit F, Tournel G, Bécart A, Hédouin H, Gosset D : Suicidal hanging result in complete decapitation – Forensic, radiological, and anthropological studies : A case report. J Forensic Sci 52(5) : 1190-1193, 2007
15. Kim DY, Lee SH : A case report of rare decapitation in suicidal hanging death (in Korean). Korean J Leg Med 35 : 152-156, 2011
16. Morild I, Lilleng PK : Different mechanisms of decapitation : Three classic and one unique case history. J Forensic Sci 57(6) : 1659-1664, 2012
17. Hejna P, Bohnert M : Decapitation in suicidal hanging – vital reaction patterns. J Forensic Sci 58(S1) : S270-277, 2013
18. Ahuja JS, Yang KM : Decapitation in suicidal hanging : a case report. J Punjab Acad Forensic Med Toxicol 15 : 97-99, 2015
19. Jang LS, Yang KM : Case report of decapitation in hanging. Korean J Leg Med 40 : 138-140, 2016
20. Byard RW, Gilbert JD : Suicidal decapitation by hanging – a population-based study. J Forensic Sci 63(3) : 958-960, 2018
21. Russo MC, Antonietti A, Farina D, Verzeletti A : Complete decapitation in suicidal hanging – a case report and a review of the literature. Forensic Sci Med Pathol 16 : 325-329, 2020
22. DeZouche JJ : Judicial executions. Br Med J 2 : 779-782, 1888
23. Prichard PD : A suicide by self-decapitation. J Forensic Sci 38 : 981-984, 1993
24. Leccia C, Alunni V, Quatrehomme G : Suicidal hanging resulting in decapitation: a case report and review of the literature. Forensic Sci Int 279 : e10-13, 2017
25. Nokes LDM, Roberts A : Biomechanics of judicial hanging : a case report. Med Sci Law 39(1) : 61-64, 1999
26. Török K, Kristóf I, Keller É : Incomplete decapitation in suicidal hanging – report of a case and review of the literature. J Forensic Leg Med 15 : 180-184, 2008
27. Holczabek W : Eine seltene Verletzung der Vorderhalsgegend beim Tod durch Erhängen. Wien Klin Wochenschr 59 : 811, 1947
28. Nowak R, Heise B : Schwere mechanische Gewaltwirkung am Hals im Rahmen einer Erhängen. In : Brinkmann B, Püschel K eds. Ersticken (FS für Werner Janssen). Springer, Berlin, 1990, s202-207.
29. Weigel B, Wilk E, König C : Über eine erhebliche Verletzung des Halses einschließlich der Halswirbelsäule und der Halsweichteile in Rahmen einer suizidalen Strangulation. Arch Kriminol 193 : 23-28, 1994