

CASE REPORT

Laparoscopic pancreaticoduodenectomy in patients with a history of right hemicolectomy : A report of three cases

Hayato Ohya, Atsuyuki Maeda, Yuichi Takayama, Takamasa Takahashi, Hiroki Aoyama, Takahiro Hosoi, Kazuaki Seita, and Yuji Kaneoka

Department of Surgery, Ogaki Municipal Hospital, Ogaki, Gifu, Japan

Abstract : Laparoscopic pancreaticoduodenectomy (LPD) has been widely adopted in institutions with sufficiently skilled practitioners. This technique requires attentive dissection around the superior mesenteric vein (SMV) and artery. Dissection around the SMV and Henle's trunk is one of the key aspects of right hemicolectomy (RHC) ; adhesions and fibrosis around these vessels may impede LPD in patients with a history of RHC. We encountered three cases of periampullary tumors in patients with a history of RHC who were successfully treated with LPD. Cases 1, 2, and 3 were of 60-, 73-, and 74-year-old men with periampullary tumors. The operative durations in cases 1, 2, and 3 were 316, 267, and 265 min, respectively. The estimated blood loss volumes in cases 1, 2, and 3 were 20, 50, and 720 mL, respectively. The postoperative hospital stay durations in cases 1, 2, and 3 were of 13, 35, and 15 days, respectively. In conclusion, LPD following RHC may be safely completed with laparoscopy. *J. Med. Invest.* 70:285-289, February, 2023

Keywords : laparoscopy, pancreaticoduodenectomy, colectomy, ampulla of Vater, neoplasms

INTRODUCTION

Laparoscopic pancreaticoduodenectomy (LPD) has become a common treatment for periampullary tumors. Some randomized controlled trials (RCTs) (1, 2) and retrospective studies (3, 4) have demonstrated the greater feasibility, safety, and superiority of LPD over that of open pancreaticoduodenectomy (OPD) ; however, authors of one RCT have expressed skepticism regarding the safety of LPD (5). The results of one meta-analysis suggested that LPD did not offer any advantage over OPD ; thus, the superiority of LPD remains debatable (6). Conversely, the indications for LPD have expanded to include pancreatic adenocarcinomas. However, the feasibility of LPD in patients with previous abdominal operations has rarely been discussed. Herein, we report three cases involving periampullary tumors in patients with a history of right hemicolectomy (RHC) who were successfully treated with LPD.

SURGICAL TECHNIQUES

Surgical procedure of standard LPD

The patients were placed in the supine position with their legs apart. The operator and the first assistant stood on the patients' right and left sides, respectively. The camera operator stood between the patients' legs. First, a 12 mm Hasson port was placed between the umbilicus and pubic symphysis. Under the view of the laparoscope, which was inserted in the first port, six additional ports were placed in the abdomen. Notably, the auxiliary 12 mm port was placed routinely along the superior mesenteric artery (SMA) and SMV (Fig. 1).

LPD procedures were performed in a manner similar to those

of OPD. First, the duodenum was mobilized and divided (Kocher maneuver), the SMV was exposed, and the Henle's trunk was clipped. Next, the hepatoduodenal ligament was dissected, the common hepatic artery was isolated, and the gastroduodenal artery was clipped. The portal vein (PV) was also identified, and tunneling of the pancreatic head was performed just above the PV. Next, the jejunum was divided, and the mesentery was detached. The oral stamp of the jejunum was pulled out through the ligament of Treitz, and the pancreatic neck was divided. We then moved on to the division of the plexus to the right side of the SMA. In this process, the inferior pancreaticoduodenal

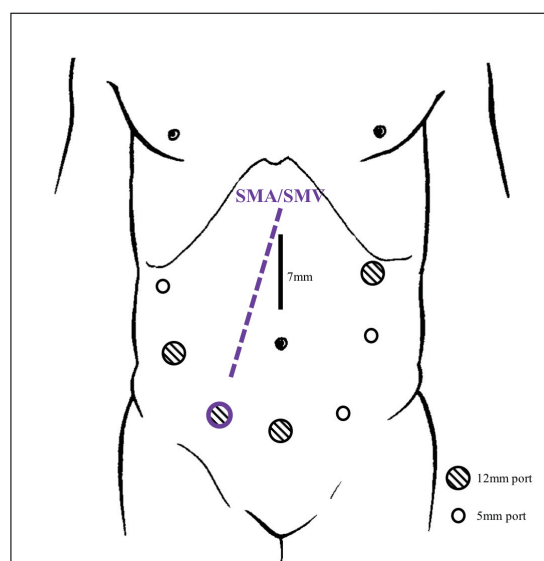


Fig 1. Image showing port placement. The circles indicate the locations of the ports. The epigastric line is the site of an additional incision (7 cm). An auxiliary 12 mm port is placed along the SMA and SMV. SMA : superior mesenteric artery, SMV : superior mesenteric vein.

Received for publication May 30, 2022 ; accepted November 17, 2022.

Address correspondence and reprint requests to Hayato Ohya, MD, Department of Surgery, Ogaki Municipal Hospital, 4-86 Minamino-kawa-cho, Ogaki, Gifu 503-0852, Japan and Fax : +81-584-75-5715. E-mail : ohyahayato@yahoo.co.jp

vein, proximal dorsal jejunal vein, and bile duct were divided; a 7 cm incision was made in the epigastrium, and the specimen was extracted. The reconstruction was performed according to the modified Child procedure. Duct-to-mucosa pancreatojejunostomy with a stent was performed extracorporeally. Cholecystojejunostomy with a continuous suture technique was performed laparoscopically, while gastrojejunostomy was performed extracorporeally. A drain was placed in the dorsal space of the cholecystojejunostomy and in the cranial portion of the pancreatojejunostomy.

Surgical procedure of LPD after RHC

In standard LPD, we perform the Kocher maneuver first, followed by mobilization of the transverse mesentery. In this approach, the SMV is identified from the right side. However, in the case of LPD after RHC, we expected to encounter difficulty with the Kocher maneuver and subsequent exposure of the SMV because of the adhesions (Fig. 2). Severe adhesions were expected to exist on the right side of the SMV. Therefore, we did not try to complete the Kocher maneuver at the first attempt, but rather

tried to identify the SMV from the left side by opening the omental bursa where no adhesiolysis was performed in the previous operation (Fig. 3 and 4). After identifying and securing the SMV, we completed the Kocher maneuver and adhesiolysis around the pancreatic head.

CASE REPORT

Case 1

A 60-year-old man presented to our hospital with jaundice. Contrast-enhanced computed tomography (CECT) and endoscopic retrograde cholangiopancreatography revealed severe narrowing of the lower bile duct due to a tumor. Cytological assessment indicated the existence of malignant cells, and he was clinically diagnosed with lower bile duct cancer (BDC). He had a history of open RHC with D3 lymph node dissection (complete mesocolic excision with central vascular ligations) (7) for ascending colon cancer (ACC), which was categorized as Stage IIA according to the Union for International Cancer Control (UICC)

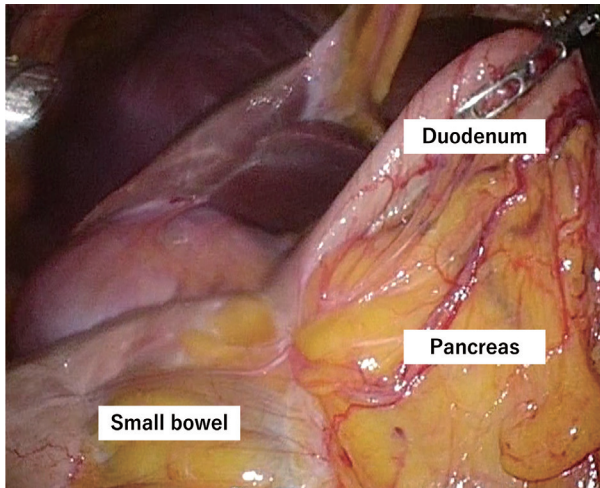


Fig 2. Severe adhesion was observed around the duodenum and pancreatic head.

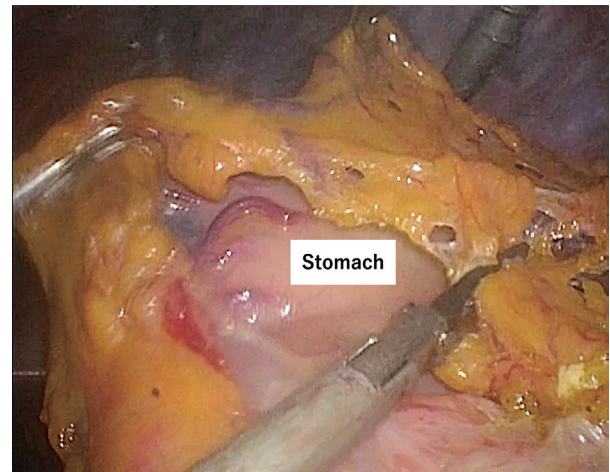


Fig 3. Division of the greater omentum enabled us to reach the virgin zone.

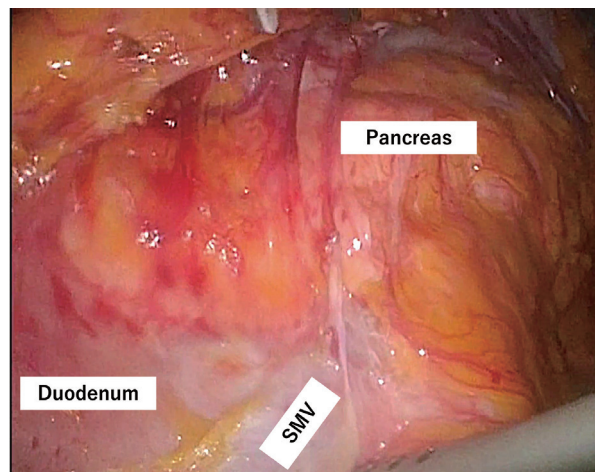


Fig 4. There was adhesion on the right side of SMV and no adhesion on the left side.

TNM Classification of Malignant Tumors, eighth edition. He was postoperatively prescribed capecitabine for 6 months as an adjuvant chemotherapy. He underwent LPD for BDC 33 months after the open RHC. Some adhesions were observed on the right side of the superior mesenteric vein (SMV). However, the adhesions were safely detached, operative time was 316 min, and estimated blood loss was 20 mL. The postoperative course was uneventful, and he was discharged on postoperative day (POD) 13. A final diagnosis of stage IIB tubular adenocarcinoma of the lower bile duct (tT3N0M0 stage IIB) was established (UICC) based on the histopathological examination. No evidence of recurrence has been reported for 13 months until now.

Case 2

A 73-year-old man with a history of laparoscopic RHC with D3 dissection for Stage IIA ACC was prescribed oral tegafur/uracil and leucovorin as adjuvant chemotherapy for 1 year. Follow-up CECT revealed a cystic lesion in the pancreatic head. Endoscopic ultrasound and magnetic resonance cholangiopancreatography revealed a 7 mm nodule inside the cyst ; thus, a clinical diagnosis

of an intraductal papillary mucinous adenoma (IPMA) was established. The patient underwent LPD for IPMA 67 months after the laparoscopic RHC. Some adhesions were observed around the pancreatic head and SMV. The operative time was 267 min and the estimated blood loss was 50 mL. The patient developed a postoperative pancreatic fistula, which was categorized as grade B according to the International Study Group of Pancreatic Fistula (8). He was discharged on POD 35. A diagnosis of IPMA was also established by a histopathological examination. No evidence of recurrence was observed after 31 months.

Case 3

A 74-year-old man with a history of laparoscopic RHC with D3 dissection for Stage II ACC underwent CECT for further investigation of an elevated carcinoembryonic antigen level. CECT revealed a hypervascular tumor in the papilla of Vater. Endoscopic examination and biopsy established a clinical diagnosis of Vaterian cancer. The patient underwent LPD for Vaterian cancer 21 months after laparoscopic RHC. Suprapancreatic portal vein injury that was irrelevant to the adhesion

Table 1. Patients' demographic characteristics and operative outcomes

Case	1	2	3
Demographic characteristics			
Indicated diseases	BDC	IPMA	PVC
Sex	Male	Male	Male
Age, years	60	73	74
BMI, kg/m ²	18.8	25.2	23.9
ASA-PS	1	2	2
Previous RHC	Open	Laparoscopic	Laparoscopic
Stage of colon cancer (UICC)	2A	2A	2A
Adjuvant chemotherapy	Capecitabine	UFT/UZEL	None
Duration between RHC and LPD, months	33	67	21
Operative outcomes			
Duration, minutes	316	267	265
Blood loss, mL	20	50	720
Number of ports	6	6	7
Wound length in mini-laparotomy, cm	7	8	8
Intraoperative injury	No	No	Portal vein
Open conversion	No	No	No
Number of harvested LNs	15	×	8
Morbidity (CD grade >2)	None	POPF	None
Hospital stay, days	13	35	15
Histological findings			
Tumor, cm	1.6	2.3	3
LN metastasis	None	×	None
Stage	2B	×	2A
Follow-up period, months	23	41	26
Recurrence	No	No	Liver
Outcome	NED	NED	DPD

BDC, bile duct cancer ; IPMA, intraductal papillary mucinous adenoma ; PVC, cancer of the papilla of Vater ; BMI, body mass index ; ASA-PS, American Society of Anesthesiologists physical status ; RHC, right hemicolectomy ; UICC, Union for International Cancer Control ; UFT/UZEL, Tegafur/uracil and leucovorin ; LPD, laparoscopic pancreaticoduodenectomy ; LN, lymph node ; CD, Clavien–Dindo classification ; POPF, postoperative pancreatic fistula ; NED, no evidence of disease ; DPD, death from primary disease.

occurred, although it was repaired laparoscopically. No other obstacle was found during surgery. The operative time was 265 min and the estimated blood loss was 720 mL. The postoperative course was uneventful, and the patient was discharged on POD 15. Based on the histopathological findings, a diagnosis of stage IIA mucinous adenocarcinoma of the duodenal papilla (tT3aN0M0; UICC) was established. Follow-up CECT 7 months after surgery revealed multiple liver metastases. Chemotherapy was initiated; however, the patient died of primary disease 26 months after the surgery.

ETHICS CONSIDERATION

This study was approved by our institutional review boards (approval number: 20180426-4). Informed consent was obtained in an opt-out manner on the institutional website, and patient anonymity was ensured. All investigations were performed in accordance with the principles of the Declaration of Helsinki.

DISCUSSION

LPD is a technically demanding procedure that can be performed only by hepatopancreatobiliary experts in advanced centers. LPD was introduced in our institution in April 2016, and a total of 88 cases have managed until November 2021. The procedure was initially indicated for patients below 80 years of age without any cardiovascular events who were diagnosed with benign or low-grade malignant tumors. However, after the indications for LPD were expanded in April 2020, patients with pancreatic cancer without vascular involvement were also treated with LPD. According to our institutional policy, only two surgeons, who have had an experience of more than 200 OPDs as operators (YK and AM), are exclusively permitted to perform LPD.

In our institution, as previously reported, laparoscopic surgery was aggressively selected for patients with a history of abdominal surgery (9). In a previous report, we presented a successfully treated LPD case following laparoscopic distal pancreatectomy and left lateral liver sectionectomy (10). In the present report, we present three cases of periampullary tumors successfully treated after an RHC. To the best of our knowledge, LPD following an RHC has not been reported to date.

Exposure of and dissection around the SMV and Henle's trunk are the key components of RHC. In LPD procedures, dissection around the SMA and SMV is one of the most difficult and critical steps. In LPD following RHC, adhesions and fibrosis around these vessels are expected to exist and require precise adhesiolysis, which seems to be a contraindication for laparoscopic surgery.

Generally, laparoscopic surgery is associated with fewer postoperative adhesions (11, 12). A multicenter prospective study that investigated adhesion formation after open and laparoscopic surgery for colorectal cancer showed reduced adhesion formation at the abdominal wall and a non-significant but minimal tendency for visceral adhesion formation in the laparoscopic surgery group (13). Cases 2 and 3 had a history of laparoscopic RHC, and the adhesions were not severe. Case 1 had a history of open RHC, and the adhesions were more severe than those in the other two cases, especially on the right side of the SMV. However, despite these adhesions and fibrosis, detachment was performed safely in all three cases.

As mentioned above, we inserted a 12 mm port parallel to the SMA and SMV in the right lower abdomen. The port is mainly used by the operator during dissection around the SMA and

SMV. Through the port the operator can gain traction parallel to the SMA and SMV, facilitating the dissection along them and the clipping of the surrounding small branches. In some cases, the camera assistant uses the port to obtain a view parallel to the SMA and SMV. This parallel view allows the operator to clearly visualize the small vessels branching from the SMA and SMV without obstruction from surrounding structures. This unique approach to port placement might contribute to safe dissection around the SMA and SMV. In one case (Case 3), an inadvertent suprapancreatic PV injury occurred, which was repaired laparoscopically, and the total blood loss was estimated to be 720 mL. However, this periportal area was not related to the previous RHC.

Postoperative pancreatic fistula (POPF) occurred in one case (Case 2). Previous reports have indicated that the incidence of POPF is more than 10%; once it occurs, it can reportedly cause life-threatening conditions with a mortality rate of up to 40% (14). Many articles have investigated the risk factors for POPF, but the most reliable risk factors (small pancreatic duct and soft pancreas) are well known (14). The updated alternative fistula risk score (ua-FRS) was published in 2019; it can predict POPF after minimally invasive pancreaticoduodenectomy and consists of the body mass index (BMI), pancreatic texture, duct size, and male sex (15). All three of our cases involved men and a soft pancreatic texture. The diameter of the main pancreatic duct in Case 2 was only 2 mm, while that in the other cases was 3 mm. In addition, the BMI in Case 2 was 25.2 kg/m², while that in Case 1 and Case 3 was 18.8 and 23.9 kg/m², respectively. The ua-FRSs were 35%, 55%, and 43% in Cases 1, 2, and 3, respectively. These findings may have affected the occurrence of POPF in Case 2.

In conclusion, dissection around the SMA and SMV is a key part of LPD following an RHC. However, based on our experience with these three cases, if the procedure is cautiously implemented with strategic port placement by experienced surgeons, LPD after an RHC can be performed safely. PV injury occurred in one case, although it was irrelevant to the influence of the previous operation. POPF occurred in one case, but this was attributable to the high-risk status of the patient. More research is needed to investigate the feasibility and safety of LPD after an abdominal surgery with greater precision.

CONFLICTS OF INTEREST

The authors have no conflicts of interest to declare.

FUNDING

The authors did not receive support from any organization for the submitted work.

ACKNOWLEDGEMENTS

None.

REFERENCES

1. Palanivelu C, Senthilnathan P, Sabnis SC, Babu NS, Srivatsan Gurumurthy S, Anand Vijai N, Nalankilli VP, Praveen Raj P, Parthasarathy R, Rajapandian S: Randomized clinical trial of laparoscopic versus open pancreaticoduodenectomy for periampullary tumours. *Br J Surg*

- 104 : 1443-1450, 2017
2. van Hilst J, de Rooij T, Bosscha K, Brinkman DJ, van Dieren S, Dijkgraaf MG, Gerhards MF, de Hingh IH, Karsten TM, Lips DJ, Luyer MD, Busch OR, Festen S, Besselink MG : Laparoscopic versus open pancreaticoduodenectomy for pancreatic or periampullary tumours (LEOPARD-2) : a multicentre, patient-blinded, randomised controlled phase 2/3 trial. *Lancet Gastroenterol Hepatol* 4 : 199-207, 2019
 3. Choi M, Hwang HK, Rho SY, Lee WJ, Kang CM : Comparing laparoscopic and open pancreaticoduodenectomy in patients with pancreatic head cancer : oncologic outcomes and inflammatory scores. *J Hepatobiliary Pancreat Sci* 27 : 124-131, 2020
 4. Tan Y, Tang T, Zhang Y, Zu G, An Y, Chen W, Wu D, Sun D, Chen X : Laparoscopic vs. open pancreaticoduodenectomy : a comparative study in elderly people. *Updates Surg* 72 : 701-707, 2020
 5. Poves I, Burdío F, Morató O, Iglesias M, Radošević A, Ilzarbe L, Visa L, Grande L : Comparison of perioperative outcomes between laparoscopic and open approach for pancreaticoduodenectomy : the PADULAP randomized controlled trial. *Ann Surg* 268 : 731-739, 2018
 6. Nickel F, Haney CM, Kowalewski KF, Probst P, Limen EF, Kalkum E, Diener MK, Strobel O, Müller-Stich BP, Hackert T : Laparoscopic versus open pancreaticoduodenectomy : a systematic review and meta-analysis of randomized controlled trials. *Ann Surg* 271 : 54-66, 2020
 7. Hashiguchi Y, Muro K, Saito Y, Ito Y, Ajioka Y, Hamaguchi T, Hasegawa K, Hotta K, Ishida H, Ishiguro M, Ishihara S, Kanemitsu Y, Kinugasa Y, Murofushi K, Nakajima TE, Oka S, Tanaka T, Taniguchi H, Tsuji A, Uehara K, Ueno H, Yamanaka T, Yamazaki K, Yoshida M, Yoshino T, Itabashi M, Sakamaki K, Sano K, Shimada Y, Tanaka S, Uetake H, Yamaguchi S, Yamaguchi N, Kobayashi H, Matsuda K, Kotake K, Sugihara K : Japanese Society for cancer of the colon and rectum (JSCCR) guidelines 2019 for the treatment of colorectal cancer. *Int J Clin Oncol* 25 : 1-42, 2020
 8. Bassi C, Marchegiani G, Dervenis C, Sarr M, Abu Hilal M, Adham M, Allen P, Andersson R, Asbun HJ, Besselink MG, Conlon K, Del Chiaro M, Falconi M, Fernandez-Cruz L, Fernandez-Del Castillo C, Fingerhut A, Friess H, Gouma DJ, Hackert T, Izbicki J, Lillemoe KD, Neoptolemos JP, Olah A, Schulick R, Shrikhande SV, Takada T, Takaori K, Traverso W, Vollmer CR, Wolfgang CL, Yeo CJ, Salvia R, Buchler M : The 2016 update of the international study group (ISGPS) definition and grading of postoperative pancreatic fistula : 11 years after. *Surgery* 161 : 584-591, 2017
 9. Kiriya M, Kaneoka Y, Maeda A, Takayama Y, Takahashi T, Seita K : Laparoscopic liver resection after laparoscopic pancreaticoduodenectomy for liver metastases of ampulla of Vater adenocarcinoma. *Surg Case Rep* 6 : 268, 2020
 10. Nakagawa Y, Fukami Y, Harada T, Maeda A, Takayama Y, Takahashi T, Uji M, Kaneoka Y : Laparoscopic pancreaticoduodenectomy for remnant pancreatic recurrence after laparoscopic distal pancreatectomy and hepatectomy for greater omentum leiomyosarcoma. *Asian J Endosc Surg* 13 : 117-120, 2020
 11. Gutt CN, Oniu T, Schemmer P, Mehrabi A, Büchler MW : Fewer adhesions induced by laparoscopic surgery? *Surg Endosc* 18 : 898-906, 2004
 12. Mais V : Peritoneal adhesions after laparoscopic gastrointestinal surgery. *World J Gastroenterol* 20 : 4917-4925, 2014
 13. Stommel MWJ, Ten Broek RPG, Strik C, Slooter GD, Verhoef C, Grunhagen DJ, van Duijvendijk P, Bemelmans MHA, den Dulk M, Sietses C, van Heek TNT, van den Boezem PB, de Wilt JHW, van Goor H : Multicenter observational study of adhesion formation after open-and laparoscopic surgery for colorectal cancer. *Ann Surg* 267 : 743-748, 2018
 14. Kawaida H, Kono H, Hosomura N, Amemiya H, Itakura J, Fujii H, Ichikawa D : Surgical techniques and postoperative management to prevent postoperative pancreatic fistula after pancreatic surgery. *World J Gastroenterol* 25 : 3722-3737, 2019
 15. Mungroop TH, Klomp maker S, Wellner UF, Steyerberg EW, Coratti A, D'Hondt M, de Pastena M, Dokmak S, Khatov I, Saint-Marc O, Wittel U, Abu Hilal M, Fuks D, Poves I, Keck T, Boggi U, Besselink MG : Updated alternative fistula risk score (ua-FRS) to include minimally invasive pancreaticoduodenectomy : pan-European validation. *Ann Surg* 273 : 334-340, 2021