

## CASE REPORT

# Transforaminal Full-endoscopic Discectomy for Gas-containing Herniated Nucleus Pulposus at L5-S1 Under Local Anesthesia : A Case Report

Takashi Inokuchi<sup>1,2</sup>, Fumitake Tezuka<sup>1</sup>, Kazuta Yamashita<sup>1</sup>, Masatoshi Morimoto<sup>1</sup>, Kosuke Sugiura<sup>1</sup>, Junzo Fujitani<sup>1</sup>, and Koichi Sairyo<sup>1</sup>

<sup>1</sup>Department of Orthopedics, Institute of Biomedical Sciences, Tokushima University Graduate School, Tokushima, Tokushima, Japan, <sup>2</sup>Department of Orthopedics, Chikamori Hospital, Kochi, Kochi, Japan

**Abstract:** The vacuum phenomenon is often observed in degenerative disc disease, whereas gas-containing disc herniation is relatively rare. Full-endoscopic discectomy at the lumbar spine level via a transforaminal approach, which was established and subsequently refined over the last two decades, requires only an 8-mm skin incision and causes minimal damage to the paravertebral muscles. Foraminoplasty, performed with a high-speed drill, is a useful technique to enlarge the foramen, especially when applied at the L5-S1 level, where the trajectory is limited because of anatomical structures such as the iliac crest. Here, we report a case of gas-containing lumbar disc herniation at L5-S1 that was successfully treated by transforaminal full-endoscopic discectomy. The patient was a 62-year-old man with low back pain and pain in the plantar aspect of the right great toe. Magnetic resonance and computed tomography scans demonstrated gas-containing lumbar disc herniation at L5-S1 on the right. Following foraminoplasty, transforaminal full-endoscopic lumbar discectomy was successfully performed under local anesthesia. The patient's symptoms improved immediately after the surgery. Transforaminal full-endoscopic surgery can be effective and minimally invasive even when performed for gas-containing disc herniation. *J. Med. Invest.* 69: 328-331, August, 2022

**Keywords:** gas-containing herniated nucleus pulposus, transforaminal approach, full-endoscopic discectomy, foraminoplasty

## INTRODUCTION

The presence of gas in the intervertebral disc space, known as the vacuum phenomenon, is a relatively common radiological finding in the elderly. Gas can be produced as part of degenerative disc disease and occasionally causes nerve compression syndrome (1, 2). There have been a few reports of gas-containing herniated nucleus pulposus (HNP) causing lumbar nerve root compression (1, 3), the treatment for which includes conservative measures (2), needle aspiration (4), and conventional surgery such as discectomy, laminotomy, and occasionally fusion (3). However, to our knowledge, there are no reports of gas-containing HNP treated by full-endoscopic surgery in the literature.

Here, we describe a case of gas-containing HNP at L5-S1 that was obvious on magnetic resonance imaging (MRI) and computed tomography (CT) and was successfully treated by transforaminal full-endoscopic discectomy (TF-FED) after foraminoplasty (5, 6). This may be the first report of a case of gas-containing HNP treated using the TF-FED technique.

## CASE REPORT

A 62-year-old man presented with low back pain and pain in the plantar aspect of the right great toe. The pain worsened when he was bending over washing his face or putting on shoes, both of which required flexion of the lumbar spine. His symp-

toms had worsened over a 2-year period of conservative treatment with medication and rehabilitation, and he was referred to our hospital. On examination, there was tenderness at the L5-S1 spinal process. The straight leg raise test was positive at 80° on the right and negative at 90° on the left. There were no sensory or motor deficits. Deep tendon reflexes were normal except for a decreased right Achilles tendon reflex. Right para-sagittal and axial T2-weighted images revealed an HNP at L5-S1 that was pressing on the right S1 nerve root (Figure 1A, 1B). CT scans showed the vacuum phenomenon in the disc space with a small collection of epidural gas and a large amount of epidural gas at L5-S1 (Figure 2A), with an axial scan through the S1 endplate clearly revealing epidural gas at the right lateral recess near the S1 nerve root (Figure 2B). Based on the MRI and CT findings, the diagnosis was gas-containing HNP at L5-S1 on the right impinging on the S1 nerve root. A right S1 selective nerve block using 1% lidocaine temporarily reduced the pain, confirming that the mechanism was S1 nerve root radiculopathy.

L5-S1 transforaminal approach would be a demanding procedure because of surrounding anatomical structures (7). Iliac crest, L5 transverse process, and hypertrophic L5-S1 facet joint were being limited in this case. Hence additional foraminoplasty was planned to enlarge the foramen. Minimally invasive TF-FED was done in the prone position under local anesthesia. The foraminoplasty was performed by shaving the superior articular process using a high-speed drill. The L5 inferior articular process and S1 pedicle were also partially removed for the foramen to be sufficiently enlarged and allow safe insertion of a cannula at the L5-S1 level. Following adequate discectomy and bony decompression, pulsation of the S1 nerve root and epidural space were confirmed. Immediately after the operation, there was marked improvement in the patient's low back pain and his pain in the great toe. He was able to walk without pain and discomfort from the day of the operation. He continued to be pain-free at

Received for publication April 7, 2022 ; accepted August 31, 2022.

Address correspondence and reprint requests to Koichi Sairyo, MD, PhD, Professor and Chairman, Department of Orthopedics, Institute of Biomedical Sciences, Tokushima University Graduate School, 3-18-15 Kuramoto-cho, Tokushima, Tokushima 770-8503, Japan and Fax : +81-88-633-0178. E-mail : sairyo@hotmail.com

the follow-up visit 12 months later.

After the surgery, sagittal and axial MRI scans indicated that the HNP was successfully removed (Figure 3A, 3B), and sagittal and axial CT scans revealed no epidural gas (Figure 4A, 4B).

The foraminoplasty had created enough space for insertion of the cannula into the neural canal (Figure 4C). This patient provided informed consent for this case report.

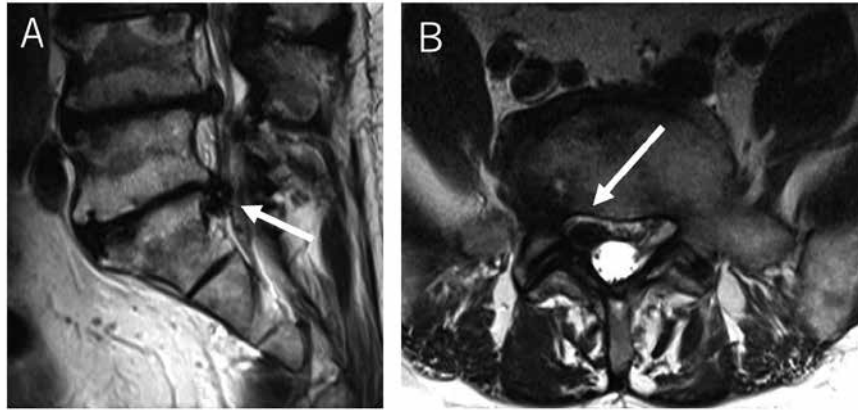


Figure 1. T2-weighted images obtained at L5–S1. (A) Para-sagittal image showing a herniated nucleus pulposus at L5–S1. (B) Axial image showing a mass pressing on the right S1 nerve root (arrows).

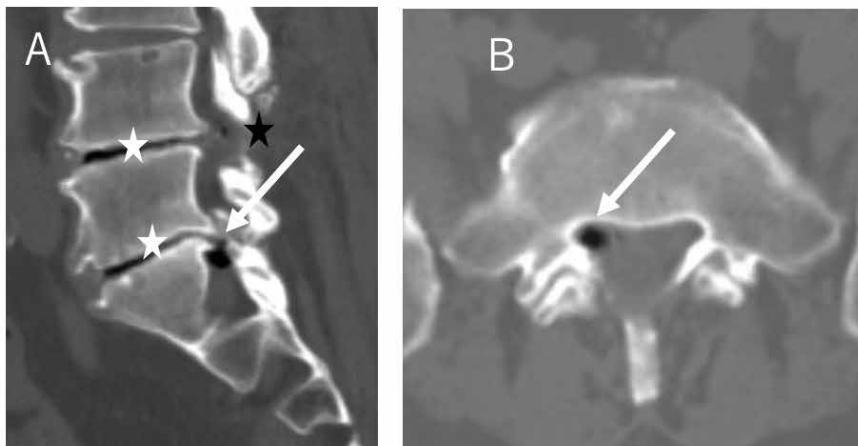


Figure 2. Computed tomography scans obtained before surgery. (A) shows the vacuum phenomenon in the disc space (white stars) and both small (black star) and large (arrow) collections of epidural gas at L5–S1. (B) Axial computed tomography scan through the S1 endplate clearly reveals epidural gas at the right lateral recess near the S1 nerve root.

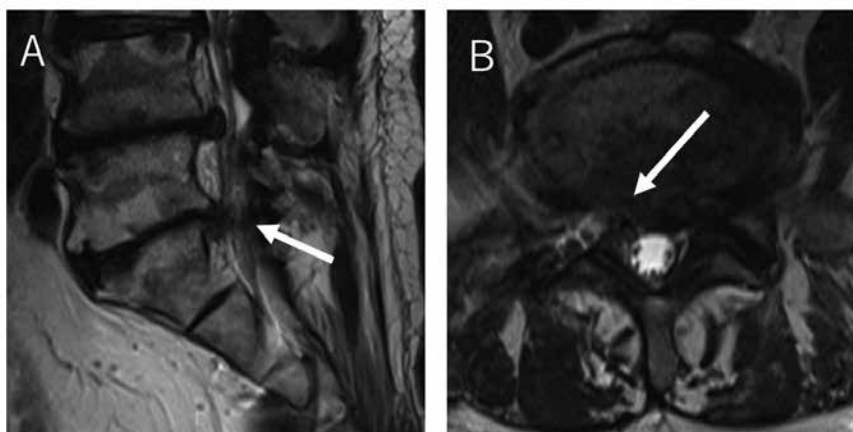


Figure 3. Magnetic resonance images obtained after surgery. Sagittal (A) and axial (B) images show that the herniated nucleus pulposus has been successfully removed (arrows).

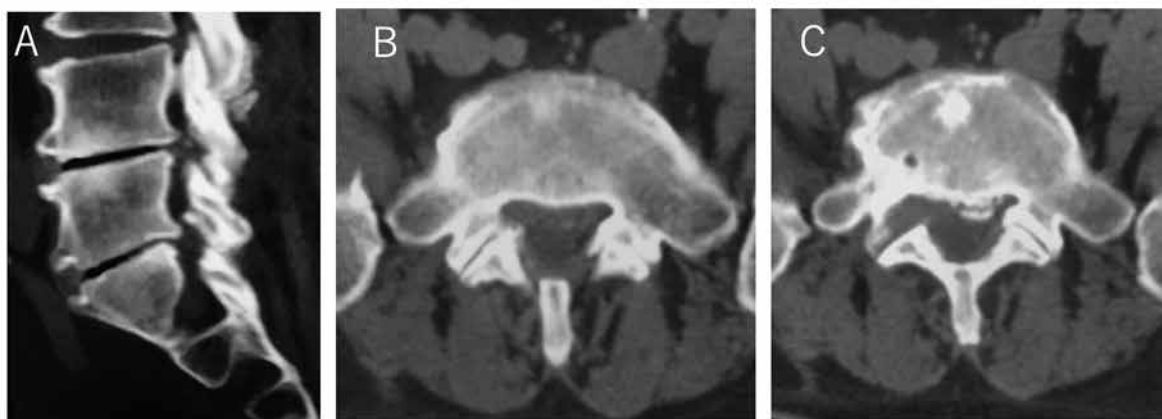


Figure 4. Computed tomography scans acquired after surgery. Epidural gas is not evident on sagittal (A) or axial (B) scans. (C) shows the area where the foraminoplasty was performed to create space for insertion of a cannula into the neural canal.

## DISCUSSION

The vacuum phenomenon in the intervertebral disc space was commonly reported (8, 9). However, gas-containing disc herniation remains relatively rare.

Liu *et al.* (10) identified 4 epidural gas patterns based on the morphologic characteristics seen on CT and MRI air pseudocyst, air cyst, air-contained disc herniation, and honeycomb-like cyst with the latter two types associated with radiculopathy. Our case showed a pattern resembling air-contained disc herniation and had radiculopathy, which is consistent with the report. Gas can be stored for a relatively long time because gas-containing disc herniation is often associated with the vacuum phenomenon, which strongly suggests degenerative disease. Also, there are no reports of gas-containing disc herniation in young persons, despite disc herniation being common in younger age groups.

In one report, 12 patients with gas-containing disc herniation who received conservative treatment for up to 6 months showed improvement or resolution of symptoms (11). There is also a report of aspiration of epidural gas using an 18-gauge needle in 2 cases of gas-containing disc herniation (4). However, an aggressive surgical approach is arguably necessary when conservative treatment is difficult or the patient has severe radiculopathy or acute cauda equina syndrome (12).

There are reports of good outcomes being obtained by open surgery or other conventional methods in patients with gas-containing disc herniation. Choi *et al.* (3) reported the results of open surgery in a series of 18 patients. Anterior lumbar interbody fusion was performed in 3 cases, transforaminal lumbar interbody fusion in 3, and discectomy in 12, with good clinical results and no recurrence at 3 months of follow-up. Hidalgo-Ovejero *et al.* (1) reported 19 cases of intraspinal gas corresponding to disc herniation, 6 of which were treated successfully by laminectomy or laminotomy.

Full-endoscopic discectomy under local anesthesia is now regarded as the least minimally invasive surgical procedure for the spine because it avoids the surgical morbidity stemming from dissection and denervation of the normal anatomy responsible for functional stability of the spine (13). Although Yeung *et al.* (13, 14) reported that it is possible to treat HNP at L5-S1 using a transforaminal approach under local anesthesia, the interlaminar approach is more widely recommended because of iliac crest obstruction under general anesthesia (15, 16). Tezuka *et al.* (17) described the trajectory of TF-FED being limited by surrounding anatomical structures such as the iliac crest, particularly at

L5-S1, and found that transforaminal full-endoscopic surgery could be performed in only 20% of the Japanese population for anatomical reasons. Therefore, an additional step, such as foraminoplasty, is needed to allow transforaminal surgery to be performed safely. As shown in Figure 4C, the intervertebral foramen is enlarged after foraminoplasty, allowing for safer insertion of the cannula (5, 6, 17-19). Our case had gas-containing HNP at L5-S1 that could be removed using TF-TED with foraminoplasty under local anesthesia. To the best of our knowledge, this is the first report of gas-containing lumbar disc herniation at L5-S1 treated by TF-FED.

A limitation for this case report is short follow-up period. There is some concern about recurrence after surgery. Sasani *et al.* (20) mentioned postoperative recurrence, and Salpietro *et al.* (21) described a case in which histological examination of the wall of a pseudocyst in association with lateral disc herniation revealed the presence of fibrous tissue identical to that found in a ligament. They emphasized the need to perform a complete microdiscectomy with accurate removal of the involved portion of the posterior longitudinal ligament to prevent subsequent formation of a pseudocyst. From this point of view, it is principal to remove including the wall of a pseudocyst completely in case of gas-containing HNP compared with those for without gas. However, more cases need to be accumulated to evaluate in more detail whether gas-containing lumbar disc herniation is likely to recur or not after TF-FED.

## CONFLICTS OF INTEREST DISCLOSURE

None of the authors has any conflicts of interest to report in connection with this article.

## REFERENCES

- Hidalgo-Ovejero AM, Matrinez-Grande M, Garcia-Mata S : Disc herniation with gas. *Spine* 19 : 2210-2212, 1994
- Tsitouridis I, Sayegh FE, Papapostolou P, Chondromatidou S, Goutsaridou F, Emmanouilidou M, Sidiropoulou MS, Kapetanios GA : Disc-like herniation in association with gas collection in the spinal canal : CT evaluation. *Eur J Radiol* 56 : 1-4, 2005
- Choi KC, Kim JS, Lee SH : Surgical experience of gas-containing disk herniation. *J Med Chir* 50 : 905-909, 2010

4. Righini A, Lucchi S, Reganati P, Zavanone M, Bettinelli A : Percutaneous treatment of gas-containing lumbar disc herniation. *J Neurosurg* 91 : 133-136, 1999
5. Sairyo K, Chikawa T, Nagamachi A : State-of-the-art transforaminal percutaneous endoscopic lumbar surgery under local anesthesia : Discectomy, foraminoplasty, and ventral facetectomy. *J Orthop Sci* 23 : 229-236, 2018
6. Yamashita K, Higashino K, Sakai T, Takata Y, Hayashi F, Tezuka F, Morimoto M, Chikawa T, Nagamachi A, Sairyo K : Percutaneous full endoscopic lumbar foraminoplasty for adjacent level foraminal stenosis following vertebral intersegmental fusion in an awake and aware patient under local anesthesia : A case report. *J Med Invest* 64 : 291-295, 2017
7. Eun SS, Lee SH, Liu WC, Erken HY : A novel preoperative trajectory evaluation method for L5-S1 transforaminal percutaneous endoscopic lumbar discectomy. *The Spine J* 18 : 1286-1291, 2018
8. Fick R : *Handbuch der Anatomie und Mechanik der Gelenke unter Verucksichtigung der bewegenden Muskeln*. Vol 2. Jena G : Fischer, 1910
9. Knutsson F : The vacuum phenomenon in the intervertebral discs. *Acta Radiol* 23 : 173-179, 1942
10. Liu WC, Lee SH, Kwon AM, Lee SH, Park J, Park HS : Morphologic characteristics and clinical significance of computed tomography and magnetic resonance imaging findings of spinal epidural gas. *World Neurosurg* 141 : 792-800, 2020
11. Tsitouridis I, Sayegh FE, Papapostolou P : Disc-like herniation in association with gas collection in the spinal canal : CT evaluation. *Eur J Radiol* 56 : 1-4, 2005
12. Mehta TA, Sharp DJ : Acute cauda equina syndrome caused by a gas-containing prolapsed intervertebral disc. *J Spinal Disord* 13 : 532-534, 2000
13. Yeung AT : The evolution of percutaneous spinal endoscopy and discectomy : state of the art. *Mt Sinai J Med* 67 : 327-332, 2000
14. Yeung AT, Tsou P.M : Posterolateral endoscopic excision for lumbar disc herniation : surgical technique, outcome, and complications in 307 consecutive cases. *Spine (Phila Pa 1976)* 27(7) : 722-731, 2002
15. Ruetten S, Komp M, Godolias G : A New full-endoscopic technique for the interlaminar operation of lumbar disc herniations using 6-mm endoscopes : prospective 2-year results of 331 patients. *Minim Invasive Neurosurg* 49(2) : 80-87, 2006
16. Dezawa A, Sairyo K : New minimally invasive discectomy technique through the interlaminar space using a percutaneous endoscope. *Asian J Endosc Surg* 4(2) : 94-98, 2011
17. Tezuka F, Toshinori S, Mitsunobu A, Yamashita K, Takata Y, Higashino K, Chikawa T, Nagamachi A, Sairyo K : Anatomical considerations of the iliac crest on percutaneous endoscopic discectomy using a transforaminal approach. *Spine J* 17 : 1875-1880, 2017
18. Kamada M, Manabe H, Yamashita K, Sakai T, Maeda T, Koichi S : Full-endoscopic decompression of foraminal stenosis caused by facet hypertrophy contralateral to the dominant hand in a baseball pitcher : A case report. *NMC CRJ* 7 : 173-177, 2020
19. Yoshinari H, Tezuka F, Yamashita K, Manabe H, Hayashi F, Ishihama Y, Sugiura K, Takata Y, Sakai T, Maeda T, Sairyo K : Transforaminal full-endoscopic lumbar discectomy under local anesthesia in awake and aware conditions : the inside-out and outside-in techniques. *Curr Rev Musculoskelet Med* 12(3) : 311-317, 2019
20. Sasani M, Ozar AF, Oktenoglu T, Cosar M, Karaarslan E, Sarioglu AC : Recurrent radiculopathy caused by epidural gas after spinal surgery. *Spine* 32 : 320-32, 2007
21. Salpietro FM, Alafaci C, Collufio D, Passalacqua M, Puglisi E, Tripodo E, Pietro GD, Tomasello F : Radicular compression by lumbar intraspinal epidural gas pseudocyst in association with lateral disc herniation. Role of the posterior longitudinal ligament. *J Neurosurg Sci* 46 : 93-95, 2002