

**ORIGINAL****Clinical application of virtual imaging guided Robot-assisted partial nephrectomy**

Keito Shiozaki<sup>1</sup>, Yasuo Kawanishi<sup>2</sup>, Yutaro Sasaki<sup>1</sup>, Kei Daizumoto<sup>1</sup>, Megumi Tsuda<sup>1</sup>, Kazuyoshi Izumi<sup>2</sup>, Yoshito Kusuhara<sup>1</sup>, Tomoya Fukawa<sup>1</sup>, Yasuyo Yamamoto<sup>1</sup>, Kunihiisa Yamaguchi<sup>1</sup>, Masayuki Takahashi<sup>1</sup>, and Hiroomi Kanayama<sup>1</sup>

<sup>1</sup>Department of Urology, Tokushima University Graduate School of Biomedical Sciences, Tokushima, Japan, <sup>2</sup>Department of Urology, Takamatsu Red Cross Hospital, Takamatsu, Japan

**Abstract :** **Objectives :** To evaluate whether virtual partial nephrectomy images could help surgeons identify vascular and collecting system around tumors during actual surgery. **Materials & methods :** We retrospectively analyzed 36 patients who underwent robot-assisted partial nephrectomy (RAPN) between 2016 and 2017. Virtual partial nephrectomy images were created from preoperative CT images using computer software, and then analyzed. For analysis, blood vessels and collecting system portions within a 5-mm-thick safety margin around the tumor were examined. During analysis, we predicted whether targeted vasculature around the tumor would require clipping or suturing during surgery, and also whether the collecting system would require opening during resection. Surgical outcomes for virtual partial nephrectomy analyses and actual RAPNs were compared and analyzed for sensitivity and specificity. **Results :** In 36 cases, 119 arteries and 100 veins were targeted on virtual partial nephrectomy images. Arterial suturing or clipping for hemostasis showed a sensitivity and specificity of 83.3% and 84.5%, respectively. For veins, the sensitivity and specificity were 39.1% and 92.2%, respectively. Collecting system opening prediction sensitivity was 85.7%, and specificity was 65.2%. **Conclusion :** Virtual partial nephrectomy imaging is useful for RAPN planning, particularly regarding arteries and the collecting system. It is hoped that techniques for visualizing veins will improve. *J. Med. Invest.* 69:237-243, August, 2022

**Keywords :** *imaging, partial nephrectomy, robot-assisted surgery*

**INTRODUCTION**

Partial nephrectomy (PN) is often used to treat smaller renal cancers to both achieve cancer control and preserve postoperative renal function to the greatest extent possible (1-3). As kidney cancer can occur in any part of the kidney, PN requires more accurate three-dimensional (3D) information than does surgery for prostate or bladder cancer. The kidney is also a relatively high-blood-flow organ, further necessitating exact anatomical information about the main vasculature to complete cancer resection. Additionally, an assessment must be made regarding preserving arteries, veins, and portions of the renal collecting system needed to maintain postoperative renal function. All such information can be obtained by 3D computed tomography (3DCT) (4-8). Moreover, because image analysis technology has made remarkable progress, it is possible to provide detailed information that can meet the high precision of robot-assisted partial nephrectomy (RAPN). In particular, preoperative simulation and intraoperative navigation have deepened the anatomical understanding of the positional relationships between tumors, renal blood vessels, and the urinary tract (9-11). However, because 3D images like that seen in Figure 1a also contain the reconstructed tumor, there is a lack of information about the vessels and urinary tract sections that appear when the tumor is dissected deeply from the kidney surface. Therefore, prior to actual surgery, we perform virtual PN analysis using

the software, Synapse Vincent, version 4 (Fujifilm Corporation, Tokyo, Japan). Virtual PN analysis shows the blood vessels that require cutting, collecting system sections that require opening, morphology of the kidney after excision, and which blood vessels and areas of the collecting system can be preserved (Fig. 1b). There are some reports on the usefulness of such preoperative virtual surgery simulations for partial hepatectomy in the field of surgery, but not for partial nephrectomy in the field of urology (12, 13). Furthermore, the reliability of preoperative 3DCT analysis of the vasculature and collecting system remains unclear when compared with actual surgical findings. By comparing virtual PN analysis findings to actual surgical findings, we report the reliability of 3DCT imaging for preoperative virtual PN planning.

**PATIENTS AND METHODS**

Subjects were 36 consecutive patients who underwent PN at our institution between May 2016 and October 2017. Patients for whom a virtual nephrectomy image could not be constructed without performing contrast-enhanced CT before surgery were excluded. In addition, all cases that were transitioned from PN to radical nephrectomy intraoperatively were excluded.

Blood vessels and urinary tract sections near the tumor were identified using virtual PN analyses from these 36 cases.

Virtual PN images were created using a multi-detector CT system (Aquilion 64 ; Toshiba Medical, Tochigi, Japan). Slice thickness was 0.5 mm, scan rate was 0.5 s/rotation, and imaging was performed in three phases : arterial, venous, and excretory. After contrast medium administration, imaging began 5 seconds after the aortic Hounsfield units (HU) at the renal artery level reached 100 HU (arterial phase), and at 70 seconds (venous

Received for publication February 17, 2022 ; accepted May 24, 2022.

Address correspondence and reprint requests to Hiroomi Kanayama, Department of Urology, Tokushima University Graduate School of Biomedical Sciences, 3-18-15 Kuramoto, Tokushima, 770-8503, Japan and Fax : +81-88-633-7160. e-mail : kanayama.hiroomi@tokushima-u.ac.jp

phase) and 5 minutes after injecting the contrast medium (excretory phase). The obtained 3D image data were reconstructed with Synapse Vincent, version 4, to create a virtual PN image. Using a 5-mm-thick safety margin of normal tissue around the renal tumor, the blood vessels and collecting system sections contained in that area were given different colors to facilitate the preoperative analysis (Fig. 1b).

So, three surgeons (one as surgeon and two as surgical assistants) preoperatively discussed and predicted whether treatment, i.e., clipping or suturing, would be required for tumor resection according to changes in color of blood vessels and urinary tract in each virtual PN analysis.

While sharing intraoperative findings and postoperative surgical videos, the three surgeons determined whether the targeted vasculature and urinary tract sections would require treatment. Surgical outcomes for virtual PN analyses and actual RAPNs were compared and analyzed for sensitivity and specificity for each of the arteries, veins, and urinary collecting systems.

## SURGICAL PROCEDURE

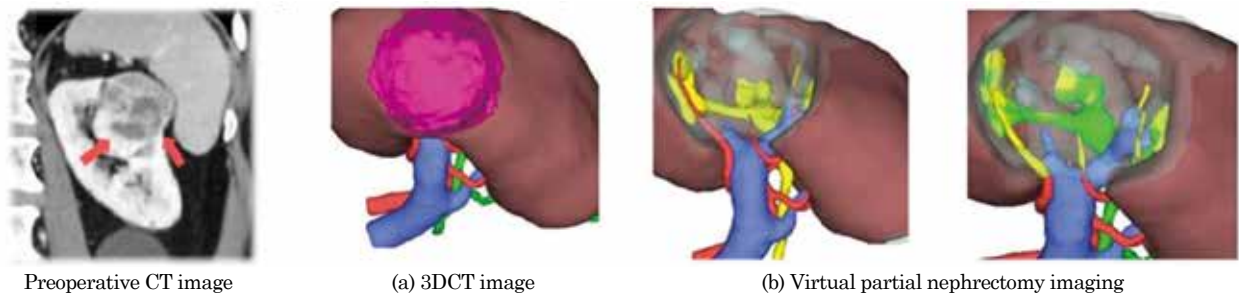
All cases underwent RAPN using soft coagulation without

renorrhaphy, which is a technique to suture the renal parenchyma for hemostasis after resection of a renal tumor.

The rim of the tumor was confirmed with an ultrasonographic device (ARIETTA 70 probe; Hitachi, Tokyo, Japan), the artery was clamped, and the tumor was then resected with a 5-mm rim. After tumor excision, soft coagulation (VIO 300D; ERBE Elektromedizin GmbH, Tübingen, Germany) was used to stop bleeding from the cut surface instead of suturing renal parenchyma (Fig. 2). When the collecting system was opened, 3-0 Biosyn™ (Covidien, Minneapolis, MN, USA) was used to close the urinary tract.

## STATISTICAL ANALYSIS

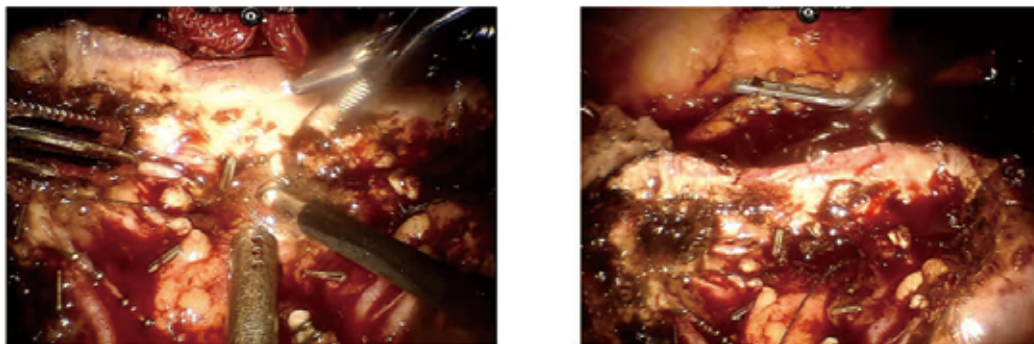
All continuous variables are represented as median (interquartile range). All statistical analyses were performed using EZR (Saitama Medical Center, Jichi Medical University, Saitama, Japan), which is a graphical user interface for R (The R Foundation for Statistical Computing, Vienna, Austria).



**Figure 1.** Virtual partial nephrectomy imaging

(a) A three-dimensional model was reconstructed showing the kidney, the tumor, renal arteries, renal veins and urinary tract.

(b) Virtual surgical planning image was created using the Synapse Vincent System version 4 (FUJIFILM Corporation, Tokyo, Japan). Excisional volume loss was taken into consideration, including a 5 mm-thick safety margin of normal tissue around renal tumor (left image). If renal vasculature or urinary tract were within excisional volume loss including the safety margin, the color of cut surface in renal vasculature or urinary tract would change (right image).



**Figure 2.** Partial nephrectomy using soft coagulation without renorrhaphy

After the tumor was removed, soft coagulation (VIO 300D; ERBE Elektromedizin GmbH) was used for controlling hemostasis on the cut surface. The Soft coagulation system has a high ability for hemostasis, which generates joule heat and causes protein degeneration because peak voltage in soft coagulation is under 200Vp. Bleeding vessels communicating with the tumor required clipping (Aesculap® Challenger® Ti) or suturing. If the urinary collection system was opened, it was sutured with 3-0 Biosyn™.

RESULTS

The patients' clinical and surgical data are shown in Tables 1 and 2. The average tumor size was 2.6 cm, and two surgical approaches were used : 14 transperitoneal and 22 retroperitoneal.

Warm ischemic time was 21 minutes. No patients had Clavien–Dindo grade III or IV postoperative complications, and negative surgical margins were achieved in all cases.

The median estimated glomerular filtration rate (eGFR) 1 month after surgery was 69 ml/min/1.73 (34.5–119) m<sup>2</sup>, and the rate of change in renal function 1 month after surgery was 88.9% (69%–142%). The average follow-up period was 33 months (27–41), and no patients developed cancer recurrence during this period.

Using virtual PN analysis, it was estimated that 119 arteries, 100 veins, and 44 collecting system sections would be involved in the actual PN (Table 3), and all of these were confirmed in surgical videos.

In Figure 3, it was assumed that artery1 would require treatment during tumor resection because the color of the cut surface in this artery had changed in the virtual PN imaging ; however, in the actual operation, artery1 did not require clipping (Fig. 3a). Artery2 was also predicted to require clipping and did in fact require clipping during tumor resection in the actual operation (Fig. 3b). It was assumed that collection system2 would require opening during tumor resection, and in the actual operation, this collection system was opened during resection and required suturing (Fig. 3c).

Of the 119 arteries, 51 were predicted to require cutting during surgery ; however, only 40 were cut during the actual surgery (Table 3). Sixty-eight arteries were predicted not to require cutting, and of these 68, 60 arteries were preserved as expected. For the arteries, virtual PN analysis sensitivity was 83.3%, specificity was 84.5%, positive predictive value (PPV) was 78.4%, and negative predictive value (NPV) was 88.2%.

Table 1. Patient (n=36) clinical characteristics

Variable	N=36
Age, median (range)	71 (40-87)
Male, n (%)	24 (66.6)
BMI (kg/m <sup>2</sup> ), median (range)	22.6 (18.4-32.9)
Side (right), n (%)	16 (44.4)
Clinical tumor size (cm), median (range)	2.6 (0.8-6.4)
Preoperative eGFR (ml/min/1.73m <sup>2</sup> ), median (range)	77.2 (37.5-117)
R.E.N.A.L. nephrometry score, median (range)	8 (4-10)
Diabetes mellitus, n (%)	10 (27.7)
Hypertension, n (%)	24 (66.6)
Smoking, n (%)	15 (41.6)
BMI = body mass index ; eGFR = estimated glomerular filtration rate.	

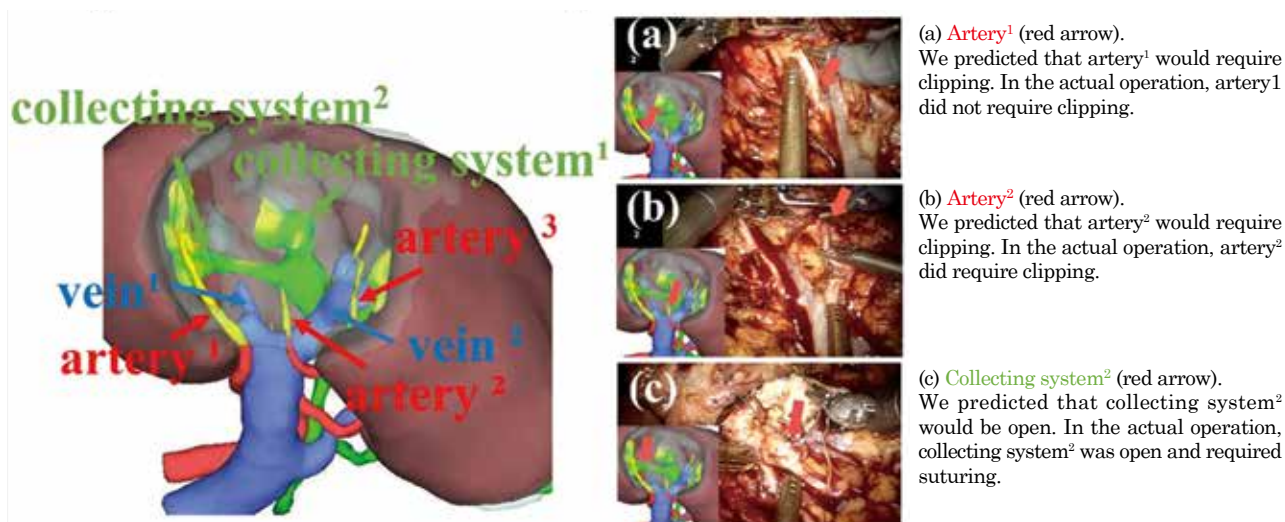
Table 2. Perioperative outcomes

Variable	N=36
Surgical approach	
transperitoneal, n (%)	14 (39)
retroperitoneal, n (%)	22 (61)
Console time (min), median (range)	155 (63-272)
Warm ischemia time (min), median (range)	21 (0-41)
Positive surgical margin, n (%)	None
Postoperative 1-month eGFR (ml/min/1.73m <sup>2</sup> ), median (range)	69 (34.5-119)
Changes of eGFR at 1-month after operation (%), median (range)	88.9 (69-142)
EBL (ml), median (range)	20 (10-900)
Transfusion, n (%)	None
Postoperative complication, n (%)	None
Pathology stage	
pT1a, n (%)	31 (86.1)
pT1b, n (%)	3 (8.3)
pT2, n (%)	0 (0)
Benign, n (%)	2 (5.6)
eGFR = estimated glomerular filtration rate ; EBL = estimated blood loss	

**Table 3.** Sensitivity and specificity of virtual partial nephrectomy analysis for the prediction of blood vessel cutting and urinary collecting system opening during surgery

	Arteries around tumors (n = 119)	
	Cut in actual surgery	Not cut in actual surgery
Cut in virtual PN analysis	40	11
Not cut in virtual PN analysis	8	60
Sensitivity	83.3% (95% CI 74.0-90.0%)	
Specificity	84.5% (95% CI 78.2-89.0%)	
	Veins around tumors (n = 100)	
	Cut in actual surgery	Preserved in actual surgery
Cut in virtual PN analysis	9	6
Preserved in virtual PN analysis	14	71
Sensitivity	39.1% (95% CI 24.8-51.2%)	
Specificity	92.2% (95% CI 87.9-95.8%)	
	Urinary collecting system (n = 44)	
	Opened in actual surgery	Not opened in actual surgery
Opened in virtual PN analysis	18	8
Not opened in virtual PN analysis	3	15
Sensitivity	85.7% (95% CI 71.7-94.5%)	
Specificity	65.2% (95% CI 51.8-73.2%)	

PN : Partial Nephrectomy

**Figure 3.** Virtual Partial Nephrectomy analysis

Of the 100 veins examined, 15 were predicted to require cutting during surgery; 9 were cut during actual surgery (Table 3). From the virtual PN analysis, it was determined that 85 veins would not require cutting; 71 were preserved in the actual surgery (Table 3). For veins, virtual PN analysis sensitivity was 39.1%, specificity was 92.2%, PPV was 60.0%, and NPV was 83.5%.

Regarding collecting system opening, 44 sites were predicted

to be involved in PN. Of these, 26 were estimated to be opened during surgery, while in actual surgery, only 18 were opened and required sutures. In addition, virtual PN analysis showed that 18 collecting system sections were located near the tumor but were determined to be preservable. Fifteen of these, as predicted, were not opened during actual PN (Table 3). For collecting system opening, virtual PN analysis sensitivity was 85.7%, specificity was 65.2%, PPV was 69.2%, and NPV was 83.3%.

## DISCUSSION

PN is often selected, currently, as a treatment for T1a renal cancer, perhaps owing to available data showing that PN provides both a satisfactory level of cancer control and better survival than radical nephrectomy (2, 3, 14-16). Cancer control and maximum renal function preservation are two important aspects of PN. With the advent of the da Vinci robotic surgery system, PN is now even more likely to be performed. RAPN has been shown to have several favorable perioperative outcomes compared to laparoscopic partial nephrectomy (LPN). Compared to LPN a decreased likelihood of conversion to open surgery, better postoperative renal function, shorter hospital stays, and shorter preservation ischemia times have been reported (27, 28).

The presence of pseudocapsules in small-diameter renal cell carcinoma is important for cancer control in PN, and the prevalence has been reported to be 80%–90% (17-19). In the case of stage T1a, the tumor infiltration rate into pseudocapsules is said to be 36% (19). Based on this rate, it has been reported that PN is possible even with a safety margin of approximately 5 mm, and it is possible to aim for a negative excision margin (20-22). This is the basis for the 5-mm safety margin set in our virtual PN analyses.

Another feature of PN is the maintenance of residual renal function. The most important factor when considering residual renal function in PN is the extent and duration of ischemia. Depending on the nature of the tumor and its location regarding the vasculature, PN without ischemia can be performed safely (5, 23); however, ischemia is often required. Anatomical information about vascular and collecting system architecture involved in tumor resection is needed to reduce ischemia extent and time. Michiels *et al.* reported that the trifecta achievement rate was higher in the 3D-image-guided RAPN group than in the control RAPN group (24). In addition to an expected reduction in ischemic time, appropriate preoperative information makes the resection plan more objective, improves coordination with the assistant surgeon, and allows blood vessels to be cut without hesitation (25). Furthermore, advanced knowledge of which blood vessels are to be cut and which are to be preserved can maximize residual renal function.

Advances in imaging technology have made it possible to determine the microstructure of blood vessels buried in organs, before surgery. This is a particularly important advance in PN. There have already been many reports on the usefulness of 3DCT imaging in RAPN (5, 9, 10). It is possible to determine the positional relationship between renal arteries, renal veins, and tumors using 3D imaging (11, 24, 25). Porpiglia *et al.* reported that, compared with standard two-dimensional (2D) imaging, 3D virtual models more precisely identified anatomical information according to nephrometry score/category (26). Tumor resection lines can also be determined (5-7, 9-11). However, what has not been known is the probability of important renal architecture to appear in actual surgery as predicted on 3D images obtained by contrast-enhanced CT. According to our study, arterial sensitivity and specificity were both sufficiently high, at over 80%; meaning that tumor-feeding arteries requiring cutting can be easily identified, allowing focus on the detachment and preservation of adjacent non-feeding arteries. This is expected to improve the quality of PN.

Unlike the sensitivity and specificity for arteries, virtual PN analysis could not sufficiently predict venous architecture

around the tumor. One of the causes may be that venous angiography is worse than arterial angiography, but the reason may also be related to the fact that veins are low-pressure blood vessels. That is, suppression of venous dilation during laparoscopic surgery under pneumoperitoneum may be associated with a reduced concordance rate. In addition, compared to preoperative navigation images, veins may have been more difficult to identify in actual surgery than arteries, with the exception of the main renal vein and its first branch veins.

Collecting system opening occurred more frequently in actual PN than was predicted in virtual PN analyses. This may be related to the practice of suturing the pelvis as a precaution if there is any concern about opening the urinary collecting system, as it is difficult to tell whether the urinary tract has been opened during surgery. Additionally, the difference between predicted and actual opening may be related to the tendency to actively open the urinary tract wall to avoid tumor retention when the tumor appears to be close to the wall.

This study has limitations. Contrast-enhanced CT is performed for almost all scheduled PN cases. The contrast-enhanced CT image data can be used to create virtual nephrectomy images; therefore, the patient does not need to undergo further examination to obtain this information. However, an issue is the length of time required to create these images. A radiologist who is accustomed to the process can save time, but approximately 1 hour of work would likely be required for a less proficient radiologist. We hope that the development of artificial intelligence (AI) technology will enable automation of image reconstruction and decrease the required time. In addition, at 36, the number of subjects in this study was small. Only 3 cases were T1b, and 90% were T1a cases. The usefulness of virtual PN images may be even greater in cases where the tumor size is large as in T1b cases, or the tumor is located in the renal hilum, but this is a topic for future study. It is necessary to accumulate more cases.

Virtual PN imaging has been shown to have some reliability for depicting important anatomical structures involved in PN; i.e., arteries, veins, and the collecting system. Inexperienced surgeons tend to be distracted by the tumor's prominence during tumor resection. However, skilled surgeons perform tumor resection by determining the resection line while visualizing in their minds the position of the tumor in relation to the vessels and the urinary tract, as well as the shape of the tumor. Virtual PN images provide visual representations of the images that skilled surgeons create in their minds during RAPN. Therefore, the virtual PN images will be very useful not only for skilled surgeons but also for inexperienced surgeons. Currently, long hours of work to obtain the images are a problem, but automation and time reduction by AI technology is expected.

## ACKNOWLEDGMENTS

We thank Ryan Johns from ACADEME ([aca-deme.com](http://aca-deme.com)) and Jane Charbonneau, DVM, from Edanz (<https://jp.edanz.com/ac>) for editing a draft of this manuscript.

## ETHICS STATEMENTS

Takamatsu Red Cross Hospital review board approved this study (approval number : 21-015).

## DECLARATIONS OF INTEREST

Keito Shiozaki, Yasuo Kawanishi, Yutaro Sasaki, Kei Daizumoto, Keisuke Ozaki, Yoshiteru Ueno, Megumi Tsuda, Kazuyoshi Izumi, Yoshito Kusuhara, Tomoya Fukawa, Yasuyo Yamamoto, Kunihisa Yamaguchi, Masayuki Takahashi, and Hiroomi Kanayama declare that they have no competing interests.

## REFERENCES

- Gratzke C, Seitz M, Bayrle F, Schlenker B, Bastian PJ, Haseke N, Bader M, Tilki D, Roosen A, Karl A, Reich O, Khoder WY, Wyler S, Stief CG, Staehler M, Bachmann A: Quality of life and perioperative outcomes after retroperitoneoscopic radical nephrectomy (RN), open RN and nephron-sparing surgery in patients with renal cell carcinoma. *BJU International* 104(4) : 470-475, 2009. <https://doi.org/10.1111/j.1464-410X.2009.08439.x>
- Miller DC, Schonlau M, Litwin MS, Lai J, Saigal CS: Renal and cardiovascular morbidity after partial or radical nephrectomy. *Cancer* 112(3) : 511-520, 2008. <https://doi.org/10.1002/encr.23218>
- van Poppel H, da Pozzo L, Albrecht W, Matveev V, Bono A, Borkowski A, Marechal JM, Klotz L, Skinner E, Keane T, Claessens I, Sylvester R: A Prospective Randomized EORTC Intergroup Phase 3 Study Comparing the Complications of Elective Nephron-Sparing Surgery and Radical Nephrectomy for Low-Stage Renal Cell Carcinoma. *European Urology* 51(6) : 1606-1615, 2007. <https://doi.org/10.1016/j.eururo.2006.11.013>
- Hayn MH, Schwaab T, Underwood W, Kim HL: RENAL nephrometry score predicts surgical outcomes of laparoscopic partial nephrectomy. *BJU International* no-no, 2011. <https://doi.org/10.1111/j.1464-410X.2010.09940.x>
- Ukimura O, Nakamoto M, Gill IS: Three-Dimensional Reconstruction of Renovascular-Tumor Anatomy to Facilitate Zero-Ischemia Partial Nephrectomy. *European Urology* 61(1) : 211-217, 2012. <https://doi.org/10.1016/j.eururo.2011.07.068>
- Thompson RH, Lane BR, Lohse CM, Leibovich BC, Fergany A, Frank I, Gill IS, Blute ML, Campbell SC: Every Minute Counts When the Renal Hilum Is Clamped During Partial Nephrectomy. *European Urology* 58(3) : 340-345, 2010. <https://doi.org/10.1016/j.eururo.2010.05.047>
- Weld KJ, Bhayani SB, Belani J, Ames CD, Hrubby G, Landman J: Extrarenal vascular anatomy of kidney: Assessment of variations and their relevance to partial nephrectomy. *Urology* 66(5) : 985-989, 2005. <https://doi.org/10.1016/j.urology.2005.05.023>
- Su LM, Vagvolgyi BP, Agarwal R, Reiley CE, Taylor RH, Hager GD: Augmented Reality During Robot-assisted Laparoscopic Partial Nephrectomy: Toward Real-Time 3D-CT to Stereoscopic Video Registration. *Urology* 73(4) : 896-900, 2009. <https://doi.org/10.1016/j.urology.2008.11.040>
- Ukimura O, Gill IS: Image-Fusion, Augmented Reality, and Predictive Surgical Navigation. *Urologic Clinics of North America* 36(2) : 115-123, 2009. <https://doi.org/10.1016/j.ucl.2009.02.012>
- Teber D, Guven S, Simpfendorfer T, Baumhauer M, Guven EO, Yencilek F, Gözen AS, Rassweiler J: Augmented Reality: A New Tool To Improve Surgical Accuracy during Laparoscopic Partial Nephrectomy? Preliminary In Vitro and In Vivo Results. *European Urology* 56(2) : 332-338, 2009. <https://doi.org/10.1016/j.eururo.2009.05.017>
- Isotani S, Shimoyama H, Yokota I, China T, Hisasue S, Ide H, Muto S, Yamaguchi R, Ukimura O, Horie S: Feasibility and accuracy of computational robot-assisted partial nephrectomy planning by virtual partial nephrectomy analysis. *International Journal of Urology* 22(5) : 439-446, 2015. <https://doi.org/10.1111/iju.12714>
- Saito S, Yamanaka J, Miura K, Nakao N, Nagao T, Sugimoto T, Hirano T, Kuroda N, Iimuro Y, Fujimoto J: A novel 3D hepatectomy simulation based on liver circulation: Application to liver resection and transplantation. *Hepatology* 41(6) : 1297-1304, 2005
- Aoki T, Murakami M, Fujimori A, Koizumi T, Enami Y, Kusano T, Matsuda K, Yamada K, Nogaki K, Wada Y, Hakozaiki T, Goto S, Watanabe M, Otsuka K: Routes for virtually guided endoscopic liver resection of subdiaphragmatic liver tumors. *Langenbeck's Archives of Surgery* 401(2) : 263-273, 2016. <https://doi.org/10.1007/s00423-016-1385-4>
- Huang WC, Elkin EB, Levey AS, Jang TL, Russo P: Partial Nephrectomy Versus Radical Nephrectomy in Patients With Small Renal Tumors—Is There a Difference in Mortality and Cardiovascular Outcomes? *Journal of Urology* 181(1) : 55-62, 2009. <https://doi.org/10.1016/j.juro.2008.09.017>
- Fergany AF, Hafez KS, Novick AC: Long-term results of nephron sparing surgery for localized renal cell carcinoma: 10-year followup. *The Journal of Urology* 163(2) : 442-445, 2000
- Thompson RH, Boorjian SA, Lohse CM, Leibovich BC, Kwon ED, Chevillie JC, Blute ML: Radical nephrectomy for pT1a renal masses may be associated with decreased overall survival compared with partial nephrectomy. *The Journal of Urology* 179(2) : 468-471; discussion 472-3, 2008. <https://doi.org/10.1016/j.juro.2007.09.077>
- Takagi T, Yoshida K, Kondo T, Kobayashi H, Iizuka J, Okumi M, Ishida H, Nagashima Y, Tanabe K: Peritumoral pseudocapsule status according to pathological characteristics from robot-assisted laparoscopic partial nephrectomy for localized renal cell carcinoma. *International Journal of Urology: Official Journal of the Japanese Urological Association* 26(4) : 446-450, 2019. <https://doi.org/10.1111/iju.13901>
- Jacob JM, Williamson SR, Gondim DD, Leese JA, Terry C, Prignon DJ, Boris RS: Characteristics of the Peritumoral Pseudocapsule Vary Predictably With Histologic Subtype of T1 Renal Neoplasms. *Urology* 86(5) : 956-961, 2015. <https://doi.org/10.1016/j.urology.2015.06.015>
- Azhar RA, de Castro Abreu AL, Broxham E, Sherrod A, Ma Y, Cai J, Gill TS, Desai M, Gill IS: Histological analysis of the kidney tumor-parenchyma interface. *The Journal of Urology* 193(2) : 415-422, 2015. <https://doi.org/10.1016/j.juro.2014.08.010>
- Chen X, Zhang Z, Du J, Bi X, Sun G, Yao X: Optimal surgical margin in nephron-sparing surgery for T1b renal cell carcinoma. *Urology* 79(4) : 836-839, 2012. <https://doi.org/10.1016/j.urology.2011.11.023>
- Berdjic N, Hakenberg OW, Zastrow S, Oehlschläger S, Novotny V, Wirth MP: Impact of resection margin status after nephron-sparing surgery for renal cell carcinoma. *BJU International* 97(6) : 1208-1210, 2006. <https://doi.org/10.1111/j.1464-410X.2006.06157.x>
- Li QL, Guan HW, Zhang QP, Zhang LZ, Wang FP, Liu YJ: Optimal margin in nephron-sparing surgery for renal cell carcinoma 4 cm or less. *European Urology* 44(4) : 448-451, 2003. [https://doi.org/10.1016/s0302-2838\(03\)00310-5](https://doi.org/10.1016/s0302-2838(03)00310-5)
- Gill IS, Eisenberg MS, Aron M, Berger A, Ukimura O, Patil MB, Campese V, Thangathurai D, Desai MM: "Zero

- ischemia” partial nephrectomy : novel laparoscopic and robotic technique. *European Urology* 59(1) : 128-134, 2011. <https://doi.org/10.1016/j.eururo.2010.10.002>
24. Michiels C, Khene ZE, Prudhomme T, Boulenger de Hauteclocque A, Cornelis FH, Percot M, Simeon H, Dupitout L, Bensadoun H, Capon G, Alezra E, Estrade V, Bladou F, Robert G, Ferriere JM, Grenier N, Doumerc N, Bensalah K, Bernhard JC : 3D-Image guided robotic-assisted partial nephrectomy : a multi-institutional propensity score-matched analysis (UroCCR study 51). *World Journal of Urology* : 2021. <https://doi.org/10.1007/s00345-021-03645-1>
25. Kobayashi S, Cho B, Huauilmé A, Tatsugami K, Honda H, Jannin P, Hashizume M, Eto M : Assessment of surgical skills by using surgical navigation in robot-assisted partial nephrectomy. *International Journal of Computer Assisted Radiology and Surgery* 14(8) : 1449-1459, 2019. <https://doi.org/10.1007/s11548-019-01980-8>
26. Porpiglia F, Amparore D, Checcucci E, Manfredi M, Stura I, Migliaretti G, Autorino R, Ficarra V, Fiori C : Three-dimensional virtual imaging of renal tumours : a new tool to improve the accuracy of nephrometry scores. *BJU International* 124(6) : 945-954, 2019. <https://doi.org/10.1111/bju.14894>
27. Choi JE, You JH, Kim DK, Rha KH, Lee SH : Comparison of perioperative outcomes between robotic and laparoscopic partial nephrectomy : a systematic review and meta-analysis. *European Urology* 67(5) : 891-901, 2015. <https://doi.org/10.1016/j.eururo.2014.12.028>
28. Leow JJ, Heah NH, Chang SL, Chong YL, Png KS : Outcomes of Robotic versus Laparoscopic Partial Nephrectomy : an Updated Meta-Analysis of 4,919 Patients. *The Journal of Urology* 196(5) : 1371-1377, 2016. <https://doi.org/10.1016/j.juro.2016.06.011>