

CASE REPORT

Retroperitoneal hemorrhage in a patient with coronavirus disease 2019 (COVID-19) : A case report

Takuya Yoshioka¹, Kei Daizumoto¹, Kouki Tada¹, Masato Mima², Kozo Kagawa², Tomoya Fukawa¹, Kunihisa Yamaguchi¹, Masayuki Takahashi¹, Yasuhiko Nishioka², and Hiroomi Kanayama¹

¹Department of Urology, Tokushima University Graduate School of Biomedical Sciences, Tokushima, Tokushima, Japan, ²Department of Respiratory Medicine and Rheumatology, Tokushima University Graduate School of Biomedical Sciences, Tokushima, Tokushima, Japan

Abstract : Introduction: Early prophylactic administration of anticoagulants is recommended in patients with coronavirus disease 2019 (COVID-19). A case of retroperitoneal hemorrhage during inpatient treatment for COVID-19 is reported. Case Presentation : A 69-year-old man was diagnosed with COVID-19 6 days after symptom onset. After admission for difficulty of breathing, he was treated with steroid pulse therapy, remdesivir, and heparin sodium. On day 16 after admission, his hemoglobin and blood pressure dropped. Computed tomography showed a left retroperitoneal hematoma and multiple areas of extravasation in bilateral iliopsoas muscles. Anticoagulation therapy was stopped, and blood transfusion therapy was chosen by considering poor general condition caused by severe pneumonia. On day 19, the hemoglobin and blood pressure improved, and blood transfusion was stopped. However, he died on day 25 due to pneumonia. Conclusion : When retroperitoneal hemorrhage occurs as a complication of COVID-19, appropriate treatment decision, transcatheter arterial embolization or conservative treatment, should be chosen based on patient's condition. *J. Med. Invest.* 69:148-151, February, 2022

Keywords : anticoagulants, COVID-19, nafamostat, retroperitoneal hemorrhage, TAE

INTRODUCTION

Prophylactic or therapeutic anticoagulation is currently recommended for patients with severe COVID-19. However, anticoagulation has also been associated with serious hemorrhagic complications such as intracranial hemorrhage (1). Retroperitoneal hemorrhage is not widely recognized because of its low incidence, despite its high mortality. Retroperitoneal hemorrhage and its treatment in patients with COVID-19 are discussed based on the case presented.

CASE PRESENTATION

A 69-year-old man had difficulty of breathing and was rushed to a nearby hospital. The COVID-19 antigen quantitative test was positive, and the patient was diagnosed with COVID-19 pneumonia and transported to our hospital. During his stay in the emergency room, his respiratory condition deteriorated, and he was intubated. His medical history included diabetes mellitus and hypertension. The blood test results for that day were as follows : white blood cells 5800/ μ L ; hemoglobin 14.2 g/dL ; platelets 91,000/ μ L ; PT-INR(prothrombin time-international normalized ratio) 1.17 ; APTT 37.2 sec ; D-dimer 2.2 μ g/mL ; HbA1c : NGSP 7.7% ; CRP 7.43 mg/dl ; creatinine 0.75

mg/dl ; and BUN 18 mg/dl. The patient was given steroid therapy for its anti-inflammatory effect and remdesivir for the infection. The remdesivir was switched to a combination of favipiravir and nafamostat due to worsening renal function. As anticoagulant therapy, heparin was administered (Figure 1).

On day 16, his hemoglobin was 6.2 g/dL, and his systolic blood pressure dropped to 60 mmHg. Whole-body contrast computed

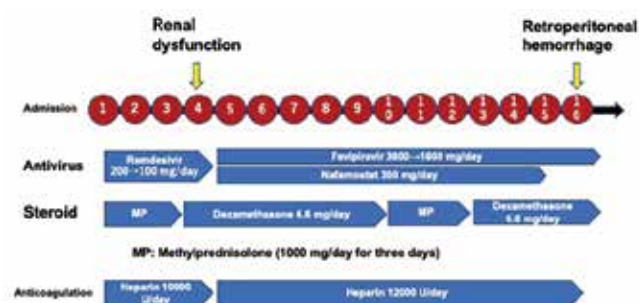


Figure 1. The patient was given steroid therapy for its anti-inflammatory effect and remdesivir for the infection. The remdesivir was switched to a combination of favipiravir and nafamostat due to worsening renal function. As anticoagulant therapy, heparin was administered 10000 units per day, and the dose was increased to 12000 units due to poor APTT prolongation.

Abbreviations and Acronyms

COVID-19, coronavirus disease 2019

CT, computed tomography

RBC, red blood cells

FFP, fresh frozen plasma

TAE, transcatheter arterial embolization

PT-INR, prothrombin time-international normalized ratio

APTT, activated partial thromboplastin time

HbA1c : NGSP, hemoglobin A_{1c} : National Glycohemoglobin Standardization Program

CRP, C-reactive protein

BUN, blood urea nitrogen

Received for publication December 20, 2021 ; accepted January 18, 2022.

Address correspondence and reprint requests to Masayuki Takahashi MD Ph.D., Department of Urology, Tokushima University, 3-18-15 Kuramoto-cho, Tokushima, Tokushima, 770-8503, Japan and Fax : +81-88-633-7160.

tomography (CT) was performed to search for the cause, and retroperitoneal hemorrhage was seen (Figure 2). After consultation with each department, anticoagulation therapy was discontinued, and conservative treatment with blood transfusion was selected. On the same day, 10 units of red blood cells (RBCs) and 8 units of fresh frozen plasma (FFP) were administered, and 10 units of platelets were administered on day 17. On day 18, 4 units of RBCs and 2 units of FFP were administered. On day 19, his hemoglobin improved to 11.3 g/dL, indicating improvement, and blood transfusion was discontinued. Though the patient's vital signs remained unchanged, he died on day 25 due to the primary disease.

DISCUSSION

Recent studies have shown that COVID-19 patients admitted to the intensive care unit (ICU) have a high incidence (17-25%) of venous thromboembolism (1). This hypercoagulability is due to an increase in inflammatory cytokines, leading to hemodynamic changes with local inflammation, microvascular thrombosis, multi-organ failure, and death. Few studies have evaluated the incidence of retroperitoneal hemorrhage in patients receiving anticoagulant therapy, which has been reported to range from 0.1% to 0.6% (2). A retrospective study of COVID-19 patients reported an incidence of 3.8 cases of retroperitoneal hemorrhage per 1,000 ICU admissions. In another report, the rate was 7.6 per 1000 admissions. These reports indicate that the rate is higher than previously reported (3, 4).

Although the exact etiology of retroperitoneal hemorrhage is unknown, it is most commonly considered a complication of anticoagulation. In addition, minor trauma from severe coughing or vomiting, bed transfer, or repositioning may also be a cause, although this hypothesis has not been confirmed by pathological examination (5). Whether COVID-19 directly affects vascular endothelial cells to cause the bleeding is unclear. However, it has been hypothesized that COVID-19 may have an affinity for angiotensin-converting enzyme 2 receptors on vascular endothelial cells, thereby directly damaging blood vessels and causing vessel wall rupture, or that dysregulation of the renin-angiotensin-aldosterone system may contribute to elevated blood pressure and cause hemorrhagic events (6). In addition, thrombocytopenia (platelet count $< 150 \times 10^3/\mu\text{L}$) and an elevated D-dimer level ($> 2.5 \mu\text{g/mL}$) at the time of initial diagnosis are said to be predictors of bleeding-related complications during hospitalization (7).

Nafamostat, which has an anticoagulant effect, is sometimes used in the treatment of COVID-19 pneumonia to prevent the invasion of viruses into cells and to prevent disseminated intravascular coagulation. Nafamostat was also used in the present case and may have contributed to the bleeding (8). Table 1 shows the treatment of reported cases (7, 9-16). Hemorrhage has been seen with both low molecular weight heparin and unfractionated heparin. Many patients survived after TAE, but those who were treated conservatively died. The present patient was in hemorrhagic shock, which may have led to deterioration of his general condition due to multiple organ failure. In the present case, CT showed a large retroperitoneal hematoma and contrast extravasation from the iliolumbar arteries, iliac circumflex arteries, and

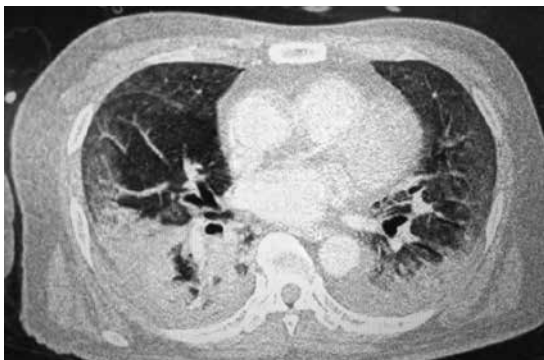

Figure 2A. Contrast-enhanced CT on day 16 after admission. Widespread pneumonia image is noted in both lung fields.

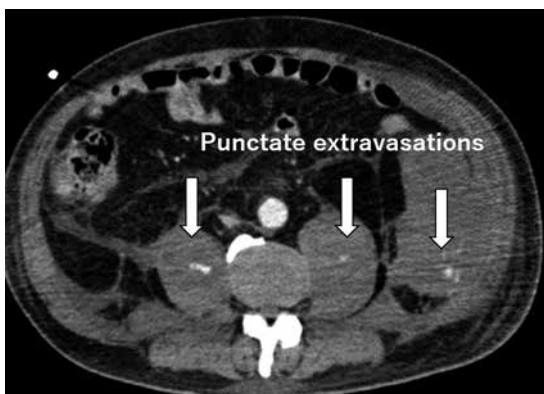


Figure 2B. There are multiple punctate extravasations within the iliopsoas muscle and retroperitoneal hematoma.

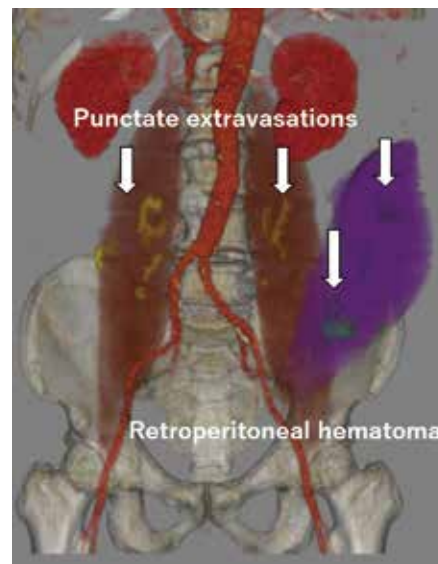


Figure 2C. The cause of bleeding is thought to be disruption of the iliolumbar artery, iliac circumflex artery, or bilateral lumbar arteries. We created this image using ZIOSTATION2 plus Type1000 software Ver 2.9.7.2.

Table 1. Summary of case reports on retroperitoneal hemorrhage in patients with COVID-19

Case	Reference	Age(y)	Sex	Location of hemorrhage	Anticoagulation	Treatment for hemorrhage	Bleeding artery	Outcome
1	Nakamura <i>et al.</i> ⁷⁾	62	M	Left iliopsoas muscle	Enoxaparin (40 mg bid subcutaneous injection)	TAE	Left L3 and L4 lumbar arteries and common iliac arteries	Alive
2	Nakamura <i>et al.</i> ⁷⁾	79	M	Right iliopsoas muscle	Therapeutic unfractionated heparin	Noninvasive treatment	ND	Died (during preparation for TAE)
3	Amir Javid <i>et al.</i> ⁹⁾	65	M	Right psoas muscle	Therapeutic unfractionated heparin 10000 U/day	Noninvasive treatment	ND	Alive
4	Erdinc and Raina ¹⁰⁾	58	F	Left iliopsoas muscle	None	Noninvasive treatment	No extravasation	Died
5	Angileri <i>et al.</i> ¹¹⁾	59	M	Right iliopsoas muscle	Prophylactic enoxaparin (60 mg/day)	ND	Lateral lumbar artery	ND
6	Patel <i>et al.</i> ¹²⁾	69	M	Right psoas muscle	Enoxaparin (1 mg/kg)	TAE	Branches of the right L3 and L4 lumbar arteries.	Alive
7	Scialpi <i>et al.</i> ¹³⁾	57	M	Right iliopsoas muscle	ND	TAE	Right ileo-lumbar artery	Alive
8	Guo <i>et al.</i> ¹⁴⁾	71	M	ND	ND, but presumably on anticoagulants because of ECMO	TAE	Right internal iliac artery	Alive
9	Conti <i>et al.</i> ¹⁵⁾	76	M	Left iliopsoas muscle	LMWH 6,000 U/day	TAE	Left inferior epigastric artery	ND
10	Conti <i>et al.</i> ¹⁵⁾	72	F	Right iliopsoas muscle	LMWH 100 U/kg, bid	TAE	Right epigastric inferior artery,	ND
11	Bargellini <i>et al.</i> ¹⁶⁾	71	M	Left iliopsoas muscle	LMWH 6,000 U/12 hour	TAE	Left lumbar arteries	Alive
12	Present case	69	M	Left iliopsoas muscle	Therapeutic unfractionated heparin 12000 U/day	Noninvasive treatment	Lumbar artery Iliolumbar artery iliac circumflex arteries	Died

bid = bis in die ; ECMO = extracorporeal membrane oxygenation ; F = female ; LMWH = low-molecular-weight heparin ; M = male ; ND = not described ; TAE = transarterial embolization ; U = units

bilateral lumbar arteries. Because the patient had been treated for COVID-19 pneumonia and his vital signs were unstable, it was decided to treat him conservatively with RBC and platelet transfusions. We did not performed CT afterwards, but blood tests and blood pressure improved, so we considered the retroperitoneal hemorrhage was well controlled. The outcome was death due to the primary disease. According to other reports, patients with bleeding from the iliolumbar artery or lumbar artery were treated with TAE with good results. In the present case, TAE could not be performed due to poor general condition caused by severe pneumonia, but based on the hemorrhage site and the arteries, TAE could have been applied. However, there is no consensus on the treatment of retroperitoneal hemorrhage, and more cases need to be studied.

CONFLICT OF INTERESTS

The authors declare no conflicts of interest.

ACKNOWLEDGEMENTS

I am deeply grateful to Momoyo Azuma, infection control team and Masao Yuasa, division of clinical technology.

APPROVAL OF THE RESEARCH PROTOCOL BY AN INSTITUTIONAL REVIEWER BOARD

Clinical research for urology was approved by the Institutional Review Board of Tokushima University Hospital (IRB No. 2004).

INFORMED CONSENT

Informed consent was obtained in the form of opt-out

REGISTRY AND THE REGISTRATION NO. OF THE STUDY/TRIAL

Not applicable

REFERENCES

1. Dogra S, Jain R, Cao M, Bilaloglu S, Zagzag D, Hochman S, Lewis A, Melmed K, Hochman K, Horwitz L, Galetta S, Berger J : Hemorrhagic stroke and anticoagulation in COVID-19. *J. Stroke Cerebrovasc Dis* 29 : 104984, 2020
2. Estivill Pallejà X, Domingo P, Fontcuberta J, Féllez J : Spontaneous retroperitoneal hemorrhage during oral anticoagulant therapy. *Arch Intern Med* 145 : 1531-4, 1985

3. Artzner T, Clere-Jehl R, Schenck M, Greget M, Merdji H, Marini PD, Tuzin N, Helms J, Meziani F : Spontaneous ilio-psoas hematomas complicating intensive care unit hospitalizations. *PLoS One* 14 : e0211680, 2019
4. Vergori A, Pianura E, Lorenzini P, D'Abramo A, Stefano FD, Grisetti S, Vita S, Pinnetti C, Donno DR, Marini MC, Nicastrì E, Ianniello S, Antinori A, ReCOVeRI Study Group : Spontaneous ilio-psoas haematomas (IPHs) : a warning for COVID-19 inpatients. *Annals of Medicine* 53 : 295-301, 2021
5. Cattaneo M, Bertinato EM, Birocchi S, Brizio C, Malavolta D, Manzoni M, Muscarella G, Orlandi M : Pulmonary embolism or pulmonary thrombosis in COVID-19? Is the recommendation to use high-dose heparin for thromboprophylaxis justified? *Thromb Haemost* 120 : 1230-2, 2020
6. Nannoni S, de Groot R, Bell S, Markus HS : Stroke in COVID-19 : a systematic review and meta-analysis. *Int. J Stroke* 16(2) : 137-149, 2021
7. Nakamura H, Ouchi G, Miyagi K, Higure Y, Otsuki M, Nishiyama N, Kinjo T, Nakamatsu M, Tateyama M, Kukita I, Fujita J : Case report : Iliopsoas hematoma during the clinical course of severe COVID-19 in two male patients. *Am J Trop Med Hyg* 104 : 1018-21, 2021
8. Doi K, Ikeda M, Hayase N, Moriya K, Morimura N, COVID-UTH Study Group : Nafamostat mesylate treatment in combination with favipiravir for patients critically ill with Covid-19 : a case series. *Critical Care* 24 : 392, 2020
9. Javid A, Kazemi R, Dehghani M, Samani HB : Catastrophic retroperitoneal hemorrhage in COVID-19 patients under anticoagulant prophylaxis. *Urology Case Reports* 36101568, 2021
10. Erdinc B, Raina JS : Spontaneous retroperitoneal bleeding coincided with massive acute deep vein thrombosis as initial presentation of COVID-19. *Cureus* 12 : e9772, 2020
11. Angileri SA, Petrillo M, Meglio LD, Arrichiello A, Rodà GM, Ierardi AM, Uberoi R, Carrafiello G : Adverse events in coronavirus disease patients management : a pictorial essay. *J Clin Imaging Sci* 10 : 42, 2020
12. Patel I, Akoluk A, Douedi S, Upadhyaya V, Mazahir U, Costanzo E, Flynn D : Life-threatening psoas hematoma due to retroperitoneal hemorrhage in a COVID-19 patient on enoxaparin treated with arterial embolization : a case report. *J Clin Med Res* 12 : 458-61, 2020
13. Scialpi M, Russo P, Piane E, Gallo E, Scalera GB : First case of retroperitoneal hematoma in COVID-19. *Turk J Urol* 46 : 407-9, 2020
14. Guo SH, Zhu SM, Yao YX : Giant retroperitoneal hematoma during extracorporeal membrane oxygenation in a patient with coronavirus disease-2019 pneumonia. *J Cardiothorac Vasc Anesth* 34 : 2839-40, 2020
15. Conti CB, Henchi S, Coppeta GP, Testa S, Grassia R : Bleeding in COVID-19 severe pneumonia : the other side of abnormal coagulation pattern? *Eur J Intern Med* 77 : 147-9, 2020
16. Bargellini I, Cervelli R, Lunardi A, Scandiffio R, Daviddi F, Giorgi L, Cicorelli A, Crocetti L, Cioni R : Spontaneous bleedings in COVID-19 patients : an emerging complication. *Cardiovasc Intervent Radiol* 17 : 1095-6, 2020