

CASE REPORT

Ataxia with vitamin E deficiency in the Philippines : A case report of two siblings

Ma. Daisy Tabuena¹, Ryoma Morigaki^{2,3}, Ryosuke Miyamoto⁴, Hideo Mure^{3,5}, Nobuaki Yamamoto^{2,4}, Kazuhisa Miyake³, Taku Matsuda³, Yuishin Izumi⁴, Yasushi Takagi^{2,3}, Rollin P. Tabuena⁶, and Toshitaka Kawarai⁴

¹Outpatient Neurology Clinic, Asclepius Drugstore, Med Lab and Allied Services Corp., Iloilo City, Philippines, ²Department of Advanced Brain Research, Institute of Biomedical Sciences, Graduate School of Medicine, Tokushima University, Tokushima, Japan, ³Department of Neurosurgery, Institute of Biomedical Sciences, Graduate School of Medicine, Tokushima University, Tokushima, Japan, ⁴Department of Neurology, Institute of Biomedical Sciences, Graduate School of Medicine, Tokushima University, Tokushima, Japan, ⁵Neuromodulation Center, Kurashiki Heisei Hospital, Okayama, Japan, ⁶Outpatient Pulmonary Clinic, Asclepius Drugstore, Med Lab and Allied Services Corp., Iloilo City, Philippines

Abstract : Here we report two siblings with ataxia and peripheral neuropathy. One patient showed head tremors. Genetic analysis revealed a mutation in the hepatic α -tocopherol transfer protein (α -TTP) gene (*TTPA*) on chromosome 8q13. They were diagnosed with ataxia with vitamin E deficiency which is firstly reported in the Philippines. As the symptoms of ataxia with vitamin E deficiency can be alleviated with lifelong vitamin E administration, differential diagnosis from similar syndromes is important. In addition, ataxia with vitamin E deficiency causes movement disorders. Therefore, a common hereditary disease in the Philippines, X-linked dystonia-parkinsonism, could be another differential diagnosis. The Philippines is an archipelago comprising 7,107 islands, and the prevalence of rare hereditary diseases among the populations of small islands is still unclear. For neurologists, establishing a system of genetic diagnosis and counseling in rural areas remains challenging. These unresolved problems should be addressed in the near future. *J. Med. Invest.* 68 : 400-403, August, 2021

Keywords : ataxia with vitamin E deficiency, movement disorders, genetic medicine, alpha-tocopherol transfer protein

INTRODUCTION

Ataxia with vitamin E deficiency (AVED) is a rare autosomal recessive inherited disease characterized by ataxia and peripheral neuropathy with a massive decrease in plasma vitamin E levels (1). Epidemiological studies have shown that the prevalence of this condition is 0.6 and 3.5 per 1,000,000 people in southeast Norway and Italy, respectively (2, 3). The causative mutations have been identified in the hepatic α -tocopherol transfer protein (α -TTP) gene (*TTPA*) on chromosome 8q13 (4).

Vitamin E is a fat-soluble antioxidant and includes 10 homologs, namely, four tocopherols, four tocotrienol isoforms, and two tococomonols (5, 6). In the liver, α -tocopherol has the highest biological activity among these isoforms, and dietary vitamin E requirements in humans are limited only to α -tocopherol because other forms of vitamin E are poorly recognized by hepatic α -TTP (7, 8). After intestinal absorption and transportation with chylomicrons, α -tocopherol is transferred to parenchymal cells of the liver where most of the fat-soluble vitamins are stored. α -TTP has a high binding affinity for α -tocopherol and facilitates its incorporation into very-low-density lipoproteins (VLDL) and high-density lipoprotein (HDL) for secretion from the liver into the circulation system (9-11). All tocopherols and tocotrienols act as free radical scavengers in the membranes and lipoproteins, quenching fatty acid peroxy radicals.

Only α -tocopherol has been tested for its potent antioxidative

properties, which show beneficial effects against AVED (6). Patients with AVED are unable to maintain normal plasma levels of α -tocopherol due to impaired incorporation into VLDL and HDL, which may cause excessive oxidative stress on the body, including neural tissues, over time (11). Clinically, AVED generally manifests as progressive ataxia, clumsiness of the hands, and loss of proprioception as the first symptom between the ages 5 and 15 years (12). Interestingly, patients with AVED experience movement disorders such as head tremors in one-third of individuals and, in rare instances, myoclonus or dystonia (12-15). Here, we report two siblings with AVED, which are the first case from the island of Panay, the Philippines, where a hereditary neurodegenerative disorder, X-linked dystonia-parkinsonism, also known as *DYT/PARK-TAF1* or "Lubag" disease, is endemic (16, 17). The differential diagnosis of movement disorders is especially important and challenging for neurologists in this island.

CASE DESCRIPTION

We report two siblings with AVED, a 24-year-old male and a 30-year-old female. The symptoms began at approximately 16 years of age for the male patient and 19 years of age for the female patient, and they initially sought medical help 5 years ago due to difficulty in walking, frequent falls, and slurring of speech at a local neurology clinic on Panay Island, the Philippines. They had no family history of ataxia or movement disorders (Fig. 1A). Physical examination revealed cerebellar dysarthria, gait and limb ataxia, mild weakness of the distal extremities, areflexia, positive Romberg sign, and extensor plantar response in both patients. The female patient also experienced neck and head tremors. The mental status of the patients was normal. Head titubation with Friedreich-like symptoms and early-onset cerebellar ataxia in

Received for publication March 4, 2021 ; accepted August 29, 2021.

Address correspondence and reprint requests to Ryoma Morigaki, MD, PhD., Department of Advanced Brain Research, Institute of Biomedical Sciences, Graduate School of Medicine, Tokushima University, 3-18-15 Kuramoto, Tokushima 770-8503, Japan and Fax : +81-88-632-9464.

combination with peripheral neuropathy suggested AVED. Laboratory tests showed normal lipid and lipoprotein profiles, and undetectable plasma α -tocopherol concentrations (< 0.2 mg/L). The analysis of *TTPA* at Tokushima University (ethical committee approval number: R2-10) revealed a homozygous missense mutation, c.358G > A, in *TTPA*, leading to amino acid substitutions p.A120T. We performed genetic testing of other family members (Fig. 1B). The siblings received genetic counseling on the island of Panay and started receiving lifelong high-dose oral vitamin E supplementation (800 IU daily). Their symptoms improved after a 2-year follow-up. Currently, the severity of ataxia in the male patient is very mild. He can perform the activities of daily life without assistance as well as heavy exercise. Presently, the female patient has residual very mild dysarthria; her head tremors have decreased in intensity by 50%. The assessment and rating of ataxia scores before and after vitamin E treatment were 18 and 7 for the male, and 16 and 10 for the female patients, respectively.

DISCUSSION

Depending on the pathogenic variants of *TTPA*, there are differences in the AVED phenotype. If the amino acid substitutions caused by variants of *TTPA* occur in non- or semi-conserved amino acids, they cause a mild phenotype, whereas substitutions in highly conserved amino acids, cause severe symptoms (12). Different mutations have been reported in North Africa (c.744delA), Italy (c.744delA and c.513insTT), North Europe (c.513insTT), the Netherlands (c.175C > T and c.437delT), and Japan (c.552G > A) (18-20). The prevalence of the missense mutation in the patients, c.358G > A (p.A120T), is relatively low and caused mild symptoms. This mutation has been reported in Norwegian and Belgian patients with AVED (3, 18) (Table 1). All patients associated with this mutation manifested cerebellar ataxia, loss of proprioceptive and vibratory sensation, and hyporeflexia. Our patients had mild weakness possibly due to skeletal myopathies (1). Head titubation was observed only in two female patients suffering for a relatively longer period. Further studies are necessary to reveal the prevalence of AVED in

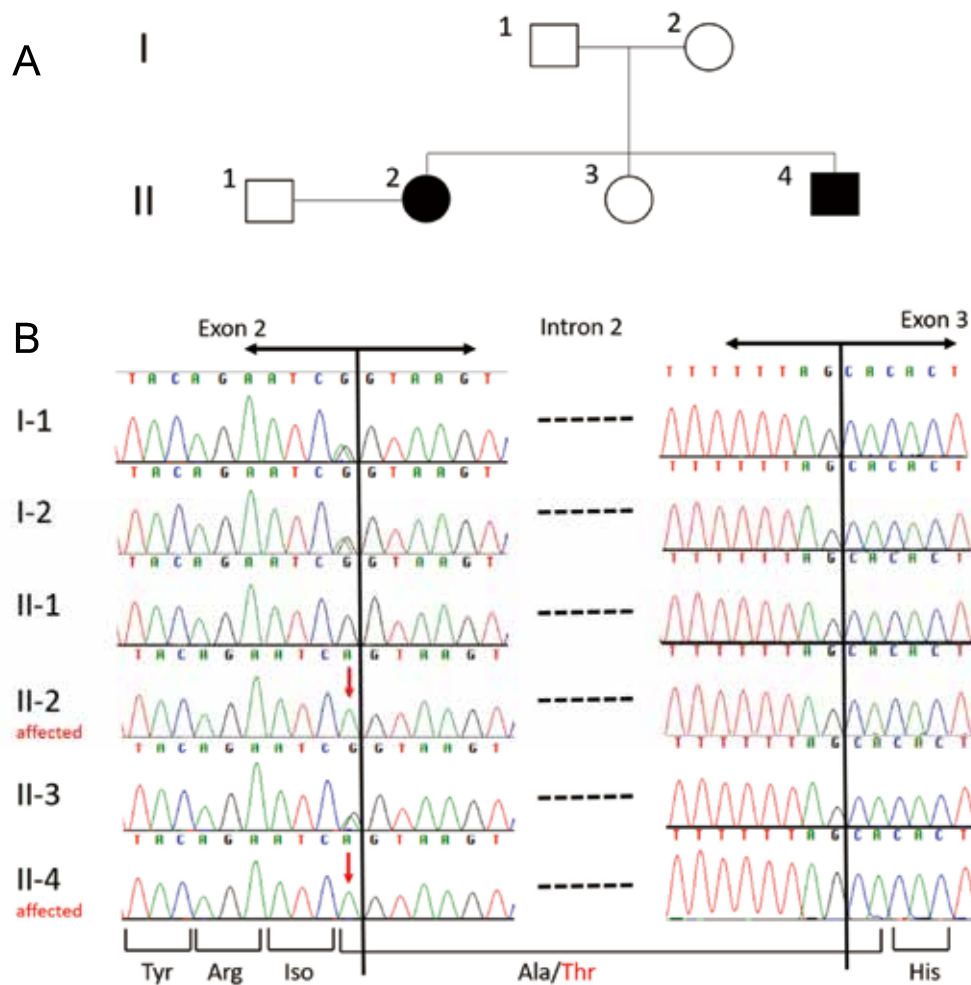


Figure 1. Pedigree chart and sequence of the patients and other family members. A: Pedigree of the sibling patients with a homozygous missense mutation in *TTPA*. Solid symbols, affected individuals; circles, females; squares, males. B: Fluorescent chromatograms of *TTPA* exon 2 and 3 sequences of the family members. The homozygous nucleotide variant c.358G > A (p.Ala418Thr) is indicated by the red arrows. Nucleotide and amino acid numbers are based on the longest isoform (NM_000370).

Table 1. Clinical characteristics of ataxia with vitamin E deficiency due to p.A120T mutation

	Sex	Age at onset (y.o.)	Age at diagnosis (y.o.)	Neurological symptoms	V.E. level at diagnosis (mg/L)	Dosage of V.E. (mg/day)	SARA scores b/a
Cavalier <i>et al.</i> 1998 (18)	N.A.	21	N.A.	Cerebellar ataxia, vibration-sense disturbance, partially decreased deep tendon reflexes	1	N.A.	N.A.
Koht <i>et al.</i> 2009 (23), Elkamil <i>et al.</i> 2015 (3)	F	5	45	Truncal and extremities ataxia, loss of proprioceptive sense, severe sensory neuropathy, titubation of the head, dysarthria, pes cavus, extensor plantar response, decreased deep tendon reflexes	Undetectable	1,000	30/30
Present case 1	M	16	24	Cerebellar ataxia, dysarthria, mild weakness of the distal extremities, positive Romberg sign, extensor plantar response, areflexia	Undetectable (< 0.2)	800	18/7
Present Case 2	F	19	30	Same as above except titubation of the head	Undetectable (< 0.2)	800	16/10

F : female, M : male, N.A. : not available, V.E. : vitamin E, SARA : Scale for assessment and rating of ataxia, b/a : before/after the treatments

the Philippines and its pathogenic variants.

According to previous reports, administering a daily high dosage of vitamin E resulted in the cessation of progression of the neurological symptoms, and amelioration of established neurological abnormalities (18, 20, 21). Furthermore, vitamin E treatment prevented disease progression over 30 years (22). It is advocated that earlier administration of vitamin E after the onset might be important for improvements in neurological deficits (23). In a previous study, patients with the same mutation as our cases did not show any symptomatic improvement when vitamin E administration was started 40 years after disease onset (23).

Differential diagnosis is important because some symptoms of AVED can be alleviated if the treatment is initiated early during the pathogenesis of the disease (12). Friedreich ataxia is a primary differential diagnosis. However, other diseases that cause vitamin E deficiency, such as abetalipoproteinemia, hypobetalipoproteinemia, and malnutrition due to reduced vitamin E uptake, could be other candidate diagnoses. Rare diseases, such as Refsum disease, Charcot-Marie-Tooth neuropathy type 1A, ataxia with oculomotor apraxia type 1 and 2, ataxia-telangiectasia, Marinesco-Sjögren syndrome, and chylomicron retention disease, should be considered if serum vitamin E levels are normal (12). In the Philippines, another important aspect should be considered. AVED patients can manifest movement disorders, such as tremors and/or dystonia (12). X-linked dystonia-parkinsonism, which is also endemic to this area, can manifest as tremors and/or dystonia depending on the clinical stage (17). From the perspective of movement disorders, AVED is an important differential diagnosis for X-linked dystonia-parkinsonism in this area.

To the best of our knowledge, the present study reports the first cases of AVED in the Philippines. Interestingly, *TTPA* knockout mice are resistant to cerebral malaria, which could explain the comparatively high prevalence of *TTPA* pathogenic variants in areas around the Mediterranean Sea (12, 24). In the Philippines, 6,604 cases of malaria were reported in 2016 (25). Given that *TTPA* mutations help protect against malaria, AVED

might be more prevalent and underestimated in the Philippines. The country comprises numerous small islands (26). The island of Panay is the sixth-largest island of the Philippines. The lack of genetic diversity in these islands might induce a relatively high risk of genetic diseases, as represented by the prevalence of X-linked dystonia-parkinsonism on the island of Panay (27).

The Philippines still has difficulties in conducting genetic research and counseling due to limited resources, geographical issues, and cultural barriers (26). Genetic testing is an imperative step in the process of securing a diagnosis for patients. Thus, it is important to establish a system for diagnosing rare hereditary diseases, even in rural areas with support from the public and government. Increase in genetic screening of the suspected population groups by geneticists is not only beneficial for patients but will facilitate regular updating of clinical information, including epidemiological data; development in genetic counseling system; and establishment of the education system for patients, family members, health professionals, and society in general, leading to comprehensive benefit in national public health (26, 28).

CONFLICT OF INTEREST-DISCLOSURE

Ma. Daisy Tabuena ; none declared, Ryoma Morigaki ; none declared, Ryosuke Miyamoto ; none declared, Hideo Mure ; none declared, Nobuaki Yamamoto ; none declared, Kazuhisa Miyake ; none declared, Taku Matsuda ; none declared, Yuishin Izumi ; none declared, Yasushi Takagi ; none declared, Rollin P. Tabuena ; none declared, Toshitaka Kawai ; none declared.

ACKNOWLEDGMENT

This work is supported by the Kanae Foundation for the promotion of medical science, JSPS KAKENHI Grant Numbers 20K17932, 20K07904, and 16KK0182. Department of Advanced Brain Research is supported by Beautylife corporation.

REFERENCES

1. Trotta E, Bortolotti S, Fugazzotto G, Gellera C, Montagnese S, Amodio P : Familial vitamin E deficiency : Multiorgan complications support the adverse role of oxidative stress. *Nutrition* 63-64 : 57-60, 2019
2. Zortea M, Armani M, Pastorello E, Nunez GF, Lombardi S, Tonello S, Rigoni MT, Zuliani L, Mostacciolo ML, Gellera C, Di Donato S, Trevisan CP : Prevalence of inherited ataxias in the province of Padua, Italy. *Neuroepidemiology* 23 : 275-280, 2004
3. Elkamil A, Johansen KK, Aasly J : Ataxia with vitamin E deficiency in Norway. *J Mov Disord* 8 : 33-36, 2015
4. Arita M, Sato Y, Miyata A, Tanabe T, Takahashi E, Kayden HJ, Arai H, Inoue K : Human alpha-tocopherol transfer protein : cDNA cloning, expression and chromosomal localization. *Biochem J* 306 : 437-443, 1995
5. Drevon CA : Absorption, transport and metabolism of vitamin E. *Free Radic Res Commun* 14 : 229-246, 1991
6. Azzi A : Tocopherols, tocotrienols and tocopherols : Many similar molecules but only one vitamin E. *Redox Biol* 26 : 101259, 2019
7. Kayden HJ, Traber MG : Absorption, lipoprotein transport, and regulation of plasma concentrations of vitamin E in humans. *J Lipid Res* 34 : 343-358, 1993
8. Mustacich DJ, Bruno RS, Traber MG : Vitamin E. *Vitam Horm* 76 : 1-21, 2007
9. Herrera E, Barbas C : Vitamin E : action, metabolism and perspectives. *J Physiol Biochem* 57 : 43-56, 2001
10. Galli F, Azzi A, Birringer M, Cook-Mills JM, Eggersdorfer M, Frank J, Cruciani G, Lorkowski S, Ozer NK : Vitamin E : Emerging aspects and new directions. *Free Radic Biol Med* 102 : 16-36, 2017
11. Traber MG, Sokol RJ, Burton GW, Ingold KU, Papas AM, Huffaker JE, Kayden HJ : Impaired ability of patients with familial isolated vitamin E deficiency to incorporate alpha-tocopherol into lipoproteins secreted by the liver. *J Clin Invest* 85 : 397-407, 1990
12. Schuelke M : Ataxia with Vitamin E Deficiency. In : Adam MP, Ardinger HH, Pagon RA, Wallace SE, Bean LJH, Mirzaa G, Amemiya A, eds. *GeneReviews* (Internet). Seattle (WA), University of Washington, Seattle, 1993-2021
13. Pradeep S, Ali T, Guduru Z : Ataxia with vitamin E deficiency with predominant cervical dystonia. *Mov Disord Clin Pract* 7 : 100-103, 2020
14. Zea Vera A, Liu W, Thomas C, Gilbert DL : Pearls & Oysters : A novel presentation of ataxia with vitamin E deficiency Caused by *TTPA* Gene Mutation. *Neurology* 96 : e640-e642, 2021
15. Becker AE, Vargas W, Pearson TS : Ataxia with vitamin E deficiency may present with cervical dystonia. *Tremor Other Hyperkinet Mov (NY)* 6 : 374, 2016
16. Morigaki R, Nakataki M, Kawarai T, Lee LV, Teleg RA, Tabuena MD, Mure H, Sako W, Pasco PM, Nagahiro S, Iga J, Ohmori T, Goto S, Kaji R : Depression in X-linked dystonia-parkinsonism : a case-control study. *Parkinsonism Relat Disord* 19 : 844-846, 2013
17. Kawarai T, Morigaki R, Kaji R, Goto S : Clinicopathological phenotype and genetics of X-Linked dystonia-parkinsonism (XDP ; DYT3 ; Lubag). *Brain Sci* 7 : 72, 2017
18. Cavalier L, Ouahchi K, Kayden HJ, Di Donato S, Reutenauer L, Mandel JL, Koenig M : Ataxia with isolated vitamin E deficiency : heterogeneity of mutations and phenotypic variability in a large number of families. *Am J Hum Genet* 62 : 301-310, 1998
19. Gabsi S, Gouider-Khouja N, Belal S, Fki M, Kefi M, Turki I, Ben Hamida M, Kayden H, Mebazaa R, Hentati F : Effect of vitamin E supplementation in patients with ataxia with vitamin E deficiency. *Eur J Neurol* 8 : 477-481, 2001
20. Yokota T, Shiojiri T, Gotoda T, Arita M, Arai H, Ohga T, Kanda T, Suzuki J, Imai T, Matsumoto H, Harino S, Kiyosawa M, Mizusawa H, Inoue K : Friedreich-like ataxia with retinitis pigmentosa caused by the His101Gln mutation of the alpha-tocopherol transfer protein gene. *Ann Neurol* 41 : 826-832, 1997
21. Kohlschutter A, Hubner C, Jansen W, Lindner SG : A treatable familial neuromyopathy with vitamin E deficiency, normal absorption, and evidence of increased consumption of vitamin E. *J Inher Metab Dis* 11 : 149-152, 1988
22. Kohlschutter A, Finckh B, Nickel M, Bley A, Hubner C : First recognized patient with genetic vitamin E deficiency stable after 36 years of controlled supplement therapy. *Neurodegener Dis* 20 : 35-38, 2020
23. Koht J, Bjornara KA, Jorum E, Tallaksen CM : Ataxia with vitamin E deficiency in southeast Norway, case report. *Acta Neurol Scand Suppl* 189 : 42-45, 2009
24. Suzuki H, Kume A, Herbas MS : Potential of vitamin E deficiency, induced by inhibition of alpha-tocopherol efflux, in murine malaria infection. *Int J Mol Sci* 20 : 64, 2018
25. Reyes RA, Fornace KM, Macalinao MLM, Boncayao BL, De La Fuente ES, Sabanal HM, Bareng APN, Medado IAP, Mercado ES, Baquilod MS, Luchavez JS, Hafalla JCR, Drakeley CJ, Espino FEJ : Enhanced health facility surveys to support malaria control and elimination across different transmission settings in the Philippines. *Am J Trop Med Hyg* 2021, Online ahead of print.
26. Padilla CD, Cutiongco-de la Paz EM : Genetics and genomic medicine in the Philippines. *Mol Genet Genomic Med* 4 : 494-503, 2016
27. Abad PJ, Tan ML, Baluyot MM, Villa AQ, Talapian GL, Reyes ME, Suarez RC, Sur AL, Aldemita VD, Padilla CD, Laurino MY : Cultural beliefs on disease causation in the Philippines : challenge and implications in genetic counseling. *J Community Genet* 5 : 399-407, 2014
28. Angural A, Spolia A, Mahajan A, Verma V, Sharma A, Kumar P, Dhar MK, Pandita KK, Rai E, Sharma S : Review : understanding rare genetic diseases in low resource regions like Jammu and Kashmir-India. *Front Genetics* 11 : 415, 2020