

## CASE REPORT

# Insertion of a Fogarty catheter through a slip joint section for neonatal and infantile one-lung ventilation : a report of two cases

Hiroki Yonezawa, M.D.<sup>1</sup>, Ryosuke Kawanishi, M.D.<sup>1</sup>, Hideto Sasaki, M.D.<sup>1</sup>, Yohei Sogabe, M.D.<sup>1</sup>, Kentaro Hirota, M.D.<sup>1</sup>, Yasuto Honda, M.D.<sup>1</sup>, and Katsuya Tanaka, M.D., Ph.D.<sup>2</sup>

<sup>1</sup>Department of Anesthesiology, Tokushima University Hospital, Tokushima City, Tokushima, Japan, <sup>2</sup>Department of Anesthesiology, Institute of Health Bioscience, the University of Tokushima Graduate School, Tokushima City, Tokushima, Japan

**Abstract :** Here, we report two cases involving a neonate and child in which a slip joint section was used to thread a Fogarty catheter into the endotracheal tube for one-lung ventilation (OLV). Both the neonate and infant required OLV, and were placed under general anesthesia. A Fogarty catheter was used for OLV. The Fogarty catheter was passed into the intraluminal side of the endotracheal tube through a slip joint section. OLV was maintained successfully without severe air leakage or Fogarty catheter displacement. The neonate had been intubated pre-operatively with a 3.5-mm inner diameter endotracheal tube, and we used that tube. These cases indicate that the technique can be applied to pre-operatively intubated patients and does not require surgeons to exchange endotracheal tubes. Use of the slip joint section technique facilitates Fogarty catheter fixation without additional dead space. *J. Med. Invest.* 68:209-212, February, 2021

**Keywords :** neonatal and infantile one-lung ventilation, slip joint section, Fogarty catheter

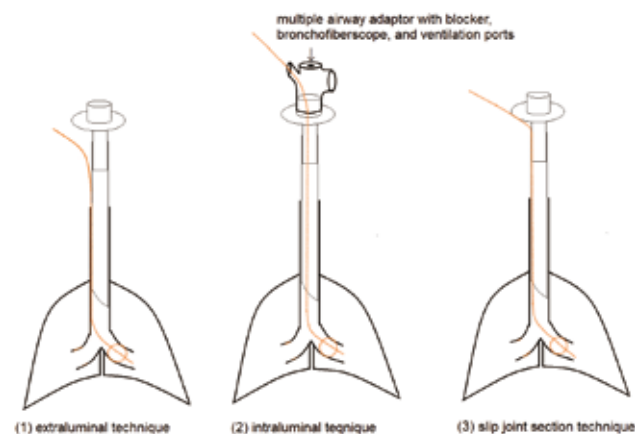
## INTRODUCTION

One-lung ventilation (OLV) provides a better surgical view than two-lung ventilation in patients undergoing thoracic surgery (1). Bronchial blockers have been administered in neonates and infants requiring OLV (2). Although the Weili endobronchial blocker has been reported to be useful (2), the device has a minimal size of 4 French and requires an endotracheal tube with an inner diameter > 4 mm. Because neonates sometimes require a narrow endotracheal tube with an inner diameter of 3.5 mm, a Weili endobronchial blocker cannot be administered. To treat these patients, Fogarty catheters have been used as endobronchial blockers based on empirically tested methods. Fogarty catheters can be inserted into an endotracheal tube (intraluminal technique) or into the trachea alongside an endotracheal tube (extraluminal technique). This clinical report describes both a neonate and an infant who underwent OLV via Fogarty catheter insertion through a slip joint section (Figure 1).

### Procedure of the slip joint section technique

Following intubation, an endotracheal tube and a slip joint were detached, and a Fogarty catheter was inserted into the endotracheal tube. The endotracheal tube and slip joint were reattached, and the position of the balloon of the Fogarty catheter was confirmed via use of a fiberscope through the elbow connector with a fiberscope port. After the Fogarty catheter balloon was inflated under fiberscope guidance, the elbow connector with a fiberscope port was removed and OLV was initiated. This technique can be used to anchor a Fogarty catheter and requires no additional dead space. Moreover, it can be applied to neonates who were intubated before arrival in the operating room, which

eliminates the risk associated with exchanging endotracheal tubes.



**Figure 1.** Three methods for inserting a Fogarty catheter include extraluminal, intraluminal, and the slip joint section techniques. A Fogarty catheter is shown as an orange line. In the extraluminal technique, a Fogarty catheter must be inserted into the trachea before intubation, and an endotracheal tube must be intubated through its side.

The intraluminal technique requires Fogarty catheter insertion into the trachea through a multiple airway adaptor with a Fogarty catheter port and fiberscope port after intubation. This adaptor cannot be removed while the Fogarty catheter is in use. When using the slip joint section technique, the Fogarty catheter is inserted into the trachea through the slip joint's connection after intubation. This method requires a multiple airway adaptor with a fiberscope port. After the Fogarty catheter is positioned and adjusted, the adaptor can be removed. The catheter is held in place by the slip joint, and no intraoperative misalignment occurred in the abovementioned two cases.

Received for publication November 19, 2020 ; accepted February 14, 2021.

Address correspondence and reprint requests to Ryosuke Kawanishi, Department of Anesthesiology, Tokushima University Hospital, 3-18-15 Kuramoto, Tokushima City, Tokushima, 770-8503, Japan.

## CASE DESCRIPTION

This off-label use of a Fogarty catheter for OLV in a neonate was approved by the local Ethics Committee of Tokushima University (Approval Number : R2-1). Written informed consent was obtained from the parents of each patient.

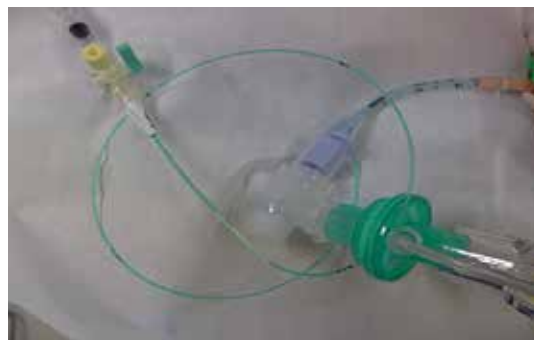### Case 1

A 4-day-old boy with a congenital diaphragmatic hernia (left Bochdalek hernia) was scheduled for diaphragmatic repair using a thoracoscopic surgery technique. He did not have any coexisting systemic illnesses. After delivery, he was intubated in the neonatal intensive care unit using a single-lumen endotracheal tube with an inner diameter of 3.5 mm, and it was determined that the patient required mechanical ventilation. He entered the operating room while being ventilated using a bag-valve unit providing 5 L/min oxygen. His vital signs at that time were as follows : 100% oxygen saturation (SpO<sub>2</sub>) and 30 mmHg carbon dioxide. General anesthesia comprised sevoflurane, midazolam, and rocuronium, with intermittent boluses of fentanyl. After he lost spontaneous respiration, mechanical pressure-controlled ventilation with a fraction of inspired oxygen of 1.0, an inspiratory pressure of 20 cmH<sub>2</sub>O, and a respiration rate of 30 breaths/min was initiated.

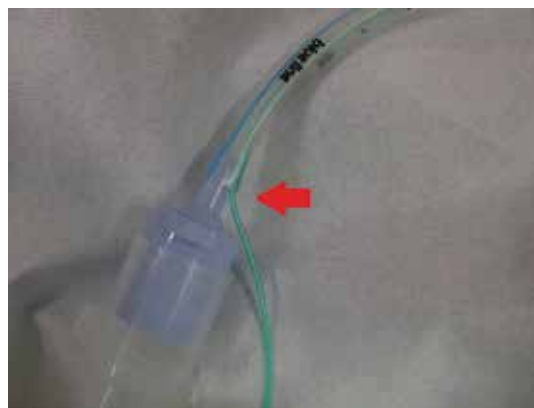The slip joint was detached, and a 3-French Fogarty catheter was inserted into the endotracheal tube. The slip joint and endotracheal tube were reconnected (Figure 2A, B), and mechanical ventilation was reinitiated. A fiberscope was inserted into the endotracheal tube using an elbow connector with a fiberscope port. The Fogarty catheter was advanced into the left bronchus under fiberscope guidance. The balloon was inflated with 1 mL of air. After the slip joint was tightened and the Fogarty catheter was fixed, the elbow connector was removed to reduce mechanical dead space and OLV was initiated. Throughout this procedure, the patient had an SpO<sub>2</sub> of 100%. The leakage of air around the Fogarty catheter was low enough to maintain mechanical ventilation. The patient was placed in the right lateral position. The position of the Fogarty catheter was rechecked using a fiberscope. Intraoperatively, an artificial pneumothorax was used, and pneumothorax pressure was initially 4 mmHg. Throughout the operation, the Fogarty catheter remained fixed, and severe desaturation did not occur. During OLV the lung of operative side was not inflated and the intraoperative collapse of the lung was good that the hernia was repaired thoracoscopically.

### Case 2

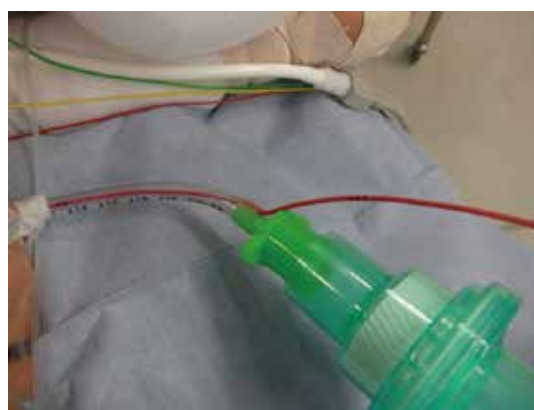A 1-year-old girl with left pulmonary sequestration was scheduled to undergo sequestered lung removal on the left side via thoracoscopic surgery. After slow induction of general anesthesia, the patient was intubated with a single-lumen endotracheal tube with an inner diameter of 4.5 mm. We selected a 4-French Fogarty catheter for this patient, and we separated the left lung using the same procedure as described in Case 1. While first attempting to advance the Fogarty catheter to the left bronchus, the procedure failed because the Fogarty catheter contacted the right bronchus. In another attempt, we bent the Fogarty catheter chip by about 30° and twisted the Fogarty catheter to the left bronchus. Using this technique, we facilitated Fogarty catheter entry to the left bronchus. After inflating the balloon of the Fogarty catheter, OLV was successfully maintained (Figure 3). Air leakage around the Fogarty catheter was minimal enough to maintain mechanical ventilation. In this case, artificial pneumothorax was also used. However, it was somewhat difficult to maintain sufficient pneumothorax pressure due to port area leakage. However, during OLV the lung of operative side was not inflated and the lung collapse was good enough to keep surgical



**Figure 2A.** Fogarty catheter inserted through the slip joint to the endotracheal tube. The Fogarty catheter is inserted into an endotracheal tube through the slip joint section. An elbow connector with a fiberscope port is inserted between the slip joint and artificial nose to facilitate the assessment of balloon position with a fiberscope. First, the slip joint is detached from the endotracheal tube. Second, a Fogarty catheter is inserted into the endotracheal tube. The slip joint is loosely connected, and mechanical ventilation reinitiated. A fiberscope is then inserted into the endotracheal tube through an elbow connector port. The Fogarty catheter is advanced into the bronchus under fiberscope guidance, and the balloon is inflated with air.



**Figure 2B.** Closer view of the slip joint section. Red arrow shows the slip joint section.



**Figure 3.** Magnified image of a Fogarty catheter that is inserted through a slip joint into the tracheal tube in case 2. A 4-French Fogarty catheter is inserted into an inner diameter 4.5 mm cuffed tracheal tube via the slip joint. The tip of the Fogarty catheter is guided into the left bronchus using a fiberscope that is inserted through an elbow joint removed to reduce mechanical dead space. One lung ventilation is successfully maintained with a small volume of air leakage.

view, and the operation was completed thoroscopically.

## DISCUSSION

We reported neonatal and infantile cases who underwent OLV using the slip joint section technique.

Video-assisted thoracic surgery in neonates and infants is becoming a standard procedure (3), thus increasing the need for OLV in these patients. A Fogarty catheter may be inserted directly into an endotracheal tube (intraluminal technique) or into the trachea alongside an endotracheal tube (extraluminal technique).

Several techniques have been described for the extraluminal placement of Fogarty catheters (4, 5). Extraluminal techniques, which require insertion of a Fogarty catheter into the trachea before intubating an endotracheal tube, require a long unventilated time, with an attendant risk of severe desaturation (6). When using the extraluminal technique, however, use of a Fogarty catheter is prone to mispositioning (5).

The intraluminal technique requires a multiple airway adaptor with a blocker, fiberoptic, and ventilation ports (7, 8). This adaptor constitutes a relatively large mechanical dead space for neonates. Another intraluminal technique uses a small hole close to the slip joint on the endotracheal tube side (9). However, this technique requires that the hole be made before intubation, necessitating an exchange of endotracheal tubes in patients intubated before being brought to the operating room.

In this report, the method of threading the Fogarty catheter through the slip joint section (the slip joint section technique) did not require formation of a new hole in the tube. Further, the method did not require additional elbow adapters during OLV. Therefore, the Fogarty catheter may be passed through a slip joint section after intubation, and the duration of ventilation disruption is relatively short.

It has been reported that Fogarty catheters may dislodge easily when a fiberoptic is inserted into or removed from an endotracheal tube. We used a fiberoptic with an outer diameter of 2.1 mm (Olympus). We felt some resistance during fiberoptic insertion and removal without intraluminal Fogarty catheter slippage. Insertion through a slip joint section may anchor the Fogarty catheter and may prevent its intraoperative migration.

This report describes a neonate and an infant who required insertion of a Fogarty catheter into the left bronchus. In case 2, insertion of the Fogarty catheter into the left bronchus was challenging, and our first attempt was unsuccessful. To overcome difficulties, we bent the tip of the Fogarty catheter about 30° and tried again, twisting the tip of the Fogarty catheter toward the left bronchus to facilitate its advance. As a result of these changes, the attempt was successful.

There are two types of thoroscopic surgery: pure thoroscopic surgery (under artificial pneumothorax) and video-assisted thoroscopic surgery (with small chest opening). Both cases involve pure thoroscopic surgeries. Congenital esophageal atresia and other diseases are treated with right thoroscopic surgery. In most cases, patients may undergo artificial pneumothorax and two-lung ventilation. When the artificial pneumothorax works correctly, the lung expands only minimally, even with two-lung ventilation. Therefore, it may be possible to operate without OLV. The two cases reported may not have absolutely required OLV. In addition, in neonatal Bochdalek hernia, the left side of the lung is often hypoplastic and inflates only minimally. Therefore, it is necessary to consider whether there is a need for OLV.

It is thought that even a small amount of collapse will have a positive impact on surgery. The method is associated with

reduced risk of hypoxia; therefore, it is worth attempting at least once. In addition, when video-assisted thoroscopic surgery is used or when it is difficult to maintain an artificial pneumothorax due to a leak, the positive impact of OLV is particularly significant and attempting the method is considered useful. The slip joint section technique may also help reduce gastric distention in cases of type C congenital esophageal atresia via tracheal-esophageal fistula closure using a Fogarty catheter.

The technique described in this study has some limitations. First, because Fogarty catheters are not designed for use in the airways, they have high pressure and low volume cuffs. Using a low-pressure, high-volume occlusive cuff may be safer than using a high-pressure cuff (10). To avoid trauma to the airway, the balloon was inflated after careful inspection of the fiberoptic. Second, because a Fogarty catheter does not have a lumen, it does not allow for the surgical lung to be adequately deflated. Moreover, severe desaturation cannot be treated using continuous positive airway pressure or high-frequency jet ventilation.

In conclusion, the slip joint section technique can be used to anchor a Fogarty catheter without requiring additional dead space. Moreover, it can be applied to a neonate who has been intubated before arrival to the operating room and eliminates the risk associated with exchanging endotracheal tubes. This technique may solve issues caused by additional dead spaces and allows for Fogarty catheter fixation using an intraluminal technique for OLV.

## CONFLICTS OF INTEREST OF EACH AUTHOR

none

## FUNDING EACH AUTHOR

none

## ACKNOWLEDGEMENTS

none

## REFERENCES

1. Hammer GB: Pediatric thoracic anesthesia. *Anesth Analg* 92: 1449-1464, 2001
2. Guo X, Song X, Chen X, Liu W, Wang H, Xia H: A novel technique for endobronchial blocker placement for one-lung ventilation in children under 2 years. *Acta Anaesthesiol Scand* 62: 765-772, 2018
3. Hammer GB, Fitzmaurice BG, Brodsky JB: Methods for single-lung ventilation in pediatric patients. *Anesth Analg* 89: 1426-1429, 1999
4. Stephenson LL, Seefelder C: Routine extraluminal use of the 5F Arndt Endobronchial Blocker for one-lung ventilation in children up to 24 months of age. *J Cardiothorac Vasc Anesth* 25: 683-686, 2011
5. Sutton CJ, Naguib A, Puri S, Spenker CJ, Camporesi EM: One-lung ventilation in infants and small children: blood gas values. *J Anesth* 26: 670-674, 2012
6. Seok JH, Kim EJ, Ban JS, Lee SG: Severe desaturation while attempting one-lung ventilation for congenital cystic adenomatoid malformation with respiratory distress syndrome in neonate-A case report. *Korean J Anesthesiol* 65: 80-84, 2013

7. Schmidt C, Rellensmann G, Van Aken H, Semik M, Brussel T, Enk D : Single-lung ventilation for pulmonary lobe resection in a newborn. *Anesth Analg* 101 : 362-364, 2005
8. Larson CE, Gasior TA : A device for endotracheal blocker placement during one-lung anesthesia. *Anesth Analg* 71 : 311-312, 1990
9. Takashi A, Ikeda S, Shingu K : Insertion of a Fogarty catheter through an endotracheal tube for one-lung ventilation : a new method. *Anesthesiology* 93 : 909, 2000
10. Borchardt RA, LaQuaglia MP, McDowall RH, Wilson RS : Bronchial injury during lung isolation in a pediatric patient. *Anesth Analg* 87 : 324-325, 1998