

CASE REPORT

A CASE OF VAGUS NERVE SCHWANNOMA DIFFICULT TO DISTINGUISH FROM LYMPH NODAL METASTASIS OF ESOPHAGEAL CANCER

Naoki Miyamoto¹, Seiya Inoue¹, Takeshi Nishino¹, Masakazu Goto¹, Takahiro Yoshida¹, Tomoko Kobayashi², Yoshimi Bando², Hiromitsu Takizawa¹, and Akira Tangoku¹

¹Department of Thoracic, Endocrine Surgery and Oncology, Tokushima University Graduate School, ²Division of Pathology, Tokushima University Hospital, Tokushima, Japan

Abstract : In this report, we describe a rare case of vagus nerve schwannoma associated with esophageal cancer. A 70-year-old man visited our hospital complaining of worsening dysphagia. His upper gastrointestinal endoscopy revealed a mass in the esophagus. A contrast-enhanced chest computed tomography also detected a 15 mm nodule attached to the tracheal membrane. This nodule was diagnosed as a metastatic lymph node. Although the primary tumor reduced after neoadjuvant chemotherapy, the nodule remained intact ; it showed fluorodeoxyglucose accumulation on positron emission tomography. We had a clinical diagnosis of stage III after neoadjuvant chemotherapy and underwent surgery. Intraoperatively, the nodule could not be detached from the right vagus nerve ; therefore, we excised the nodule along with the adjacent vagus nerve. The nodule was pathologically diagnosed as a vagus schwannoma. The nodule was not a regional lymph node metastasis of esophageal cancer. His postoperative course was uneventful, and he is currently undergoing outpatient follow-up without recurrence. *J. Med. Invest.* 68:205-208, February, 2021

Keywords : vagus nerve, schwannoma, esophageal cancer, lymph node metastasis

INTRODUCTION

Most of the neurogenic tumors originate from the sympathetic trunk and intercostal nerves, and intrathoracic vagal schwannomas are rare (1). When an intrathoracic vagal schwannoma co-exists with a malignant tumor in the chest, it becomes difficult to distinguish the tumor from regional lymph node metastasis. We report a case of vagal schwannoma, which was initially diagnosed as lymph node metastasis of esophageal cancer.

CASE REPORT

A 70-year-old man presented to us with a history of dysphagia for two months. He reported a weight loss of about 7 kg in the past one month. He had a history of descending colon cancer (T3N0M0 StageIIA) and appendicitis. A mass lesion had been found in the lower esophagus during upper gastrointestinal endoscopy at the previous hospital, following which he was referred to our hospital and admitted for further evaluation. On physical examination, vital signs were normal and there was no superficial lymphadenopathy or hoarseness.

Laboratory biochemical tests were normal. The tumor markers carcinoembryonic antigen (CEA) (1.6 ng/mL) and squamous cell carcinoma related antigen (SCC) (0.88 ng/mL) were not elevated. Upper gastrointestinal endoscopy revealed a 3/4-circumferential type 3 tumor in the lower esophagus, 28-37 cm from the dentition (Fig. 1a). Although there was resistance, we

could pass the endoscope through the tumor. Contrast-enhanced computed tomography showed circumferential wall thickening in the lower esophagus (Fig. 1b). A nodule (15.0 × 13.9 mm) enhancing with contrast was observed over the tracheal membrane (Fig. 1c). The nodule in contact with the trachea was diagnosed as a lymph node metastasis of No.105. The patient was eventually diagnosed with lower thoracic esophageal cancer, T3N1M0, Stage III according to UICC 7th edition (2), and one course of neoadjuvant chemotherapy (3) was administered. The esophageal tumor showed good response and a marked reduction in size was observed (Fig. 2a), but the nodule in contact with the tracheal membrane remained intact (Fig. 2b). Fluorodeoxyglucose accumulation on positron emission tomography (FDG-PET) after chemotherapy showed standardized uptake value (SUV) max : 9.4 (Fig. 2c) FDG accumulation in the primary lesion and SUVmax : 5.2 (Fig. 2d) accumulation in the No. 105 lesion.

Surgery was performed based on the determination of stable disease (SD) in the therapeutic effect assessment according to RECIST ver.1.1 (4). Esophageal resection was performed in the left lateral decubitus position and a complete thoracoscopic examination was performed. The lymph node of No.105 was identified as a white-colored mass on the caudal side of the azygos arch (Fig. 3a). There was no observed invasion to the azygos vein or trachea, but the vagus nerve could not be delineated from the nodule, and dissection was difficult. Taking into consideration the apparent nerve invasion, the right vagus nerve was transected at the level of the azygos arch and the tumor was excised (Fig. 3b). Subsequently, the surgery was completed uneventfully with subtotal esophagectomy and reconstruction of the gastric tube through the retrosternal route.

The pathological findings were : esophageal cancer from the middle to the lower esophagus, 9 cm, moderately to well-differentiated squamous cell carcinoma, T2, INFb, ly0, v1, IMX, PM0, DM0, RM0, N0(0/58), M0, StageII, and treatment effect judgment Grade 1a.

Received for publication November 1, 2020 ; accepted February 15, 2021.

Address correspondence and reprint requests to Naoki Miyamoto, MD, Department of Thoracic, Endocrine Surgery and Oncology, Institute of Biomedical Sciences, Tokushima University Graduate School, 3-18-15 Kuramoto-cho, Tokushima 770-8503, Japan.

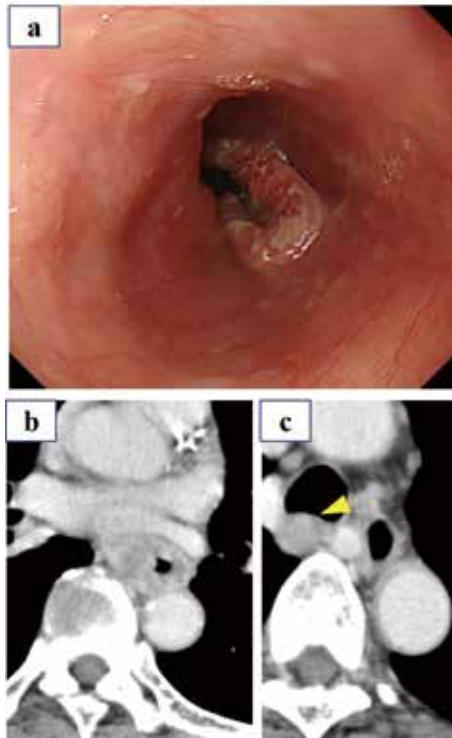


Fig 1. Endoscopic and imaging findings before chemotherapy.
 (a) Upper gastrointestinal endoscopic findings: A 3/4 circumference type 3 tumor was found.
 (b) Thoracic computed tomography: Circumferential wall thickening was found in the lower thoracic esophagus.
 (c) A 15.0 × 13.9 mm well-defined mass (arrowhead) in contact with the trachea was observed.

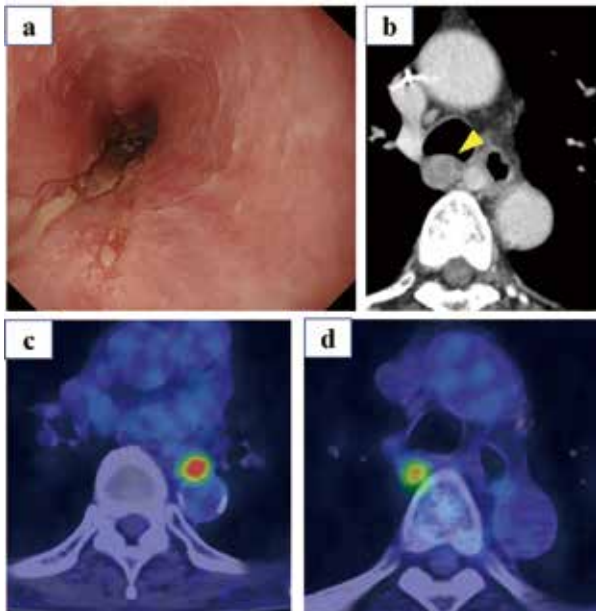


Fig 2. Endoscopic and imaging findings after chemotherapy
 (a) Upper gastrointestinal endoscopy: The primary lesion had significantly reduced.
 (b) Thoracic computed tomography: Nodule (arrowhead) in contact with the trachea remained unchanged.
 (c) and (d) PET/CT: Primary lesion FDG accumulation with standardized uptake value (SUV) max: 9.40 and FDG accumulation of SUVmax: 5.17 was observed in the nodule on the dorsal side of the trachea.

The tumor adjacent to trachea that was assumed to be a lymph node, had a high density of spindle-shaped palisade arrangement of cells, and no necrosis or mitotic figures were observed (Fig.4a). S-100 immunostaining showed diffuse staining in spindle-shaped palisade arrangements (Fig. 4b). The tumor was diagnosed as a schwannoma.

The postoperative course was uneventful. There was no hoarseness after surgery, oral feeds were started on day 7, and the patient was discharged on day 33. Postoperative adjuvant chemotherapy was not administered. The patient is currently on follow-up on outpatient basis without recurrence.

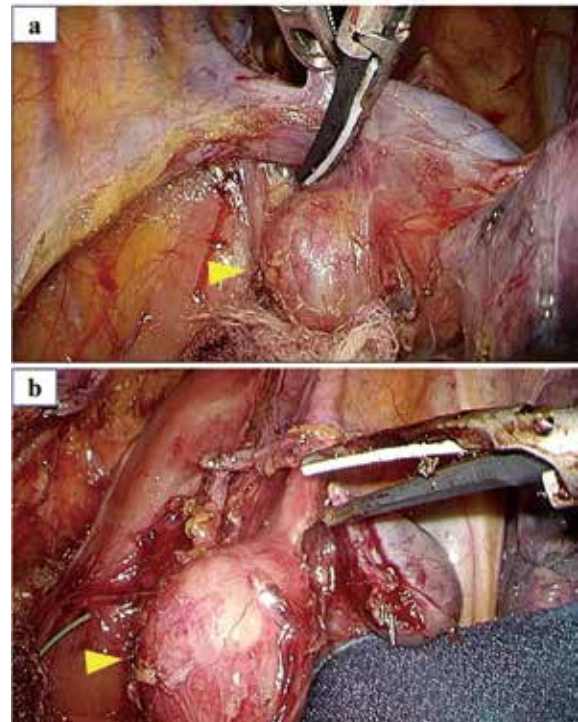


Fig 3. Intraoperative findings
 (a) The lesion appeared as a white nodule (arrowhead) on the caudal side of the azygos vein, with no invasion.
 (b) The vagus nerve was cut at the periphery of the recurrent laryngeal nerve bifurcation and the lesion was excised.

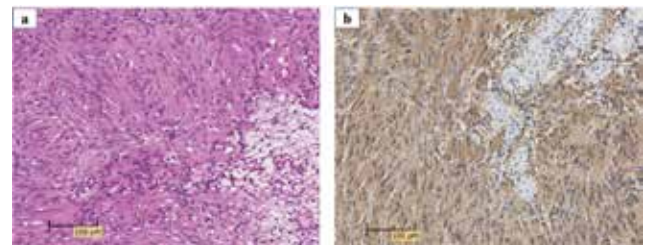


Fig 4. Histopathological findings
 (a) HE staining: A mixed pattern of spindle-shaped cells showing a high-density palisade arrangement (Antoni A type) and cells having a viscous substrate (Antoni B type).
 (b) S-100. Immunostaining: The cytoplasm of the area showing the palisade sequence diffusely stained.

DISCUSSION

Over 90% of intrathoracic neurogenic tumors are benign and the most common histological type is schwannoma, originating from the Schwann cells (3). The most common site of schwannomas is the head and neck (45% of cases), with intrathoracic cases accounting for only 9%. Intrathoracic vagal nerve schwannomas are rare, constituting only 1.4% of the cases (5).

There are reports of endobronchial ultrasound bronchoscopy being useful for the definitive diagnosis of intrathoracic vagal nerve schwannoma. However, in many cases, definitive diagnosis is made based on postoperative histopathology (5, 6).

On searching PubMed for publications in English using the keyword "intrathoracic schwannoma" between 2000 and 2020, we found 318 reports. Among these, there were no reports on esophageal tumors with intrathoracic schwannoma; however, we found a case report about lung cancer with intrathoracic schwannoma (7). In this case, the schwannoma was considered to be a metastatic lymph node and resected.

In the present case, the lymph node of No.105 had not shrunk after the patient underwent preoperative chemotherapy and therefore, it was determined as SD. In the preoperative initial examination when intrathoracic vagal schwannoma was diagnosed, the esophageal cancer clinical staging was T3N0M0, Stage II and there would have been no change in the treatment strategy of preoperative chemotherapy. If chemotherapy and radiation therapy had been additionally performed on the lymph node of No.105, the timing of the operation might have been delayed and may have increased the incidence of postoperative complications.

Post-chemotherapy PET/CT confirmed high accumulation in the primary lesion and the vagal schwannoma. Since schwannomas express high levels of glucose transporter type 3 (GLUT-3), a transport protein to incorporate glucose into cells, they exhibit high uptake in FDG-PET (8). Togano (9) examined FDG-PET images of esophageal schwannoma from 10 cases, confirmed high accumulation or significant accumulation in all cases, and reported that the average SUVmax was 6.6. In addition, magnetic resonance imaging (MRI) is often used to diagnose schwannoma, with low signals exhibited on T1WI, high signals on T2WI, and with gadolinium contrast (10). Although MRI imaging was not performed in the present case, since metastatic lymph node was suspected, preoperative PET/CT was necessary to eliminate distant metastasis and for post-chemotherapy assessment of the disease. Endoscopic ultrasound-guided fine-needle aspiration (EUS-FNA) or endobronchial ultrasound-guided transbronchial needle aspiration (EBUS-TBNA) is often used for the diagnosis of intrathoracic schwannoma. These modalities have been reported to be useful for diagnosis (11). In our case, the schwannoma was the behind trachea, and we might have diagnosed the schwannoma by using EBUS-TBNA. However, we considered radical surgery for esophageal cancer; hence, it was not necessary to diagnose schwannoma by EBUS-TBNA.

During the surgical procedure, we were able to preserve the right recurrent laryngeal nerve as the lesion was located caudal to the bifurcation of the recurrent laryngeal nerve. There are no lateral differences reported in the site of occurrence of vagal schwannomas. On the right, it tends to occur distal to the recurrent laryngeal nerve bifurcation, while on the left, it usually occurs more medial than the bifurcation (12). Adverse events from vagus nerve transection distal to the recurrent laryngeal nerve bifurcation are limited. In the present case, preservation of the vagus nerve was difficult owing to the complete resection of the esophageal cancer. Transecting lesions that develop on the medial side of the bifurcation of the recurrent laryngeal nerve cause hoarseness. Thus, the surgeon has to decide between resection

and enucleation. No consensus has been reached on this issue; it has been reported that the recurrent laryngeal nerves can be preserved while performing enucleation (13), whereas another reported case had hoarseness despite conserving the recurrent laryngeal nerve (14). Although rare, intrathoracic neurogenic tumors could be malignant schwannomas (15); close attention should be paid to such residual tumors.

We discussed a case of vagal schwannoma in which differential diagnosis from mediastinal lymph node metastasis of esophageal cancer was difficult. Intrathoracic vagus nerve schwannoma associated with a malignant tumor could easily be diagnosed as lymph node metastasis, resulting in erroneous staging that could lead to radical surgery. Therefore, careful attention is required for diagnosis. To that end, comprehensive imaging assessment with both PET/CT and MRI must be performed in such cases and differential diagnosis should be made based on histopathology of the lesion, other than the primary tumor, especially for lesions that do not respond to chemotherapy.

CONCLUSION

We encountered a rare case of intrathoracic vagal schwannoma associated with esophageal cancer. It was difficult to distinguish schwannomas from metastatic lymph nodes when they are associated with malignant tumors. Accurate diagnosis requires comprehensive evaluation, such as comparing imaging findings, and assessing responsiveness to treatment along with the main lesion.

CONFLICTS OF INTEREST

All authors have no conflicts of interest associated with this study.

ACKNOWLEDGEMENTS

The abstract of this paper was presented at the 40th Shikoku Esophageal Disease Study Group (February 2020, Ehime).

REFERENCES

1. Sugio K, Inoue T, Tateishi M, Ishida T, Sugimachi K: Neurogenic tumors of the mediastinum originated from the vagus nerve. *Eur J Surg Oncol* 21: 214-216, 1995
2. Leslie HS, Mary KG, Christian W, editors: TNM Classification of Malignant Tumours, 7th Edition. Wiley-Blackwell, Hodoken, 2009
3. Yoshida T, Seike J, Miyoshi T, Yamai H, Takechi H, Yuasa Y, Furukita Y, Yamamoto Y, Umemoto A, Tangoku A: Preoperative chemotherapy with weekly docetaxel plus low-dose cisplatin and 5-fluorouracil for stage II/III squamous cell carcinoma of the esophagus. *Esophagus* 7: 95-100, 2010
4. Eisenhauer EA, Therasse P, Bogaerts J, Schwartz LH, Sargent D, Ford R, Dancey J, Arbuck S, Gwyther S, Mooney M, Rubinstein L, Shankar L, Dodd L, Kaplan R, Lacombe D, Verweij J. New response evaluation criteria in solid tumours: revised RECIST guideline (version 1.1). *Eur J Cancer* 45: 228-247, 2009
5. Yamauchi S, Tamaoka M, Okamoto T, Ogata T, Tsuchiya K, Sakashita H, Miyazaki Y, Inase N: A superior mediastinal schwannoma successfully diagnosed by endobronchial ultrasound-guided transbronchial needle aspiration

- (EBUS-TBNA). *J Jpn Soc Resp Endosc* 34 : 616-620, 2012
6. Takahashi K, Ikeda M, Ohnishi R, Kato T, Fujinaga T : A patient with a vagal nerve schwannoma in whom endobronchial ultrasound-guided transbronchial needle aspiration (EBUS-TBNA) was useful for preoperative diagnosis. *J Jpn Soc Resp Endosc* 37 : 382-387, 2015
 7. Fernando LW, Luiz CL, José CL, Michel AT, Felipe SM : Lung cancer and schwannoma--the pitfalls of positron emission tomography. *J Bras Pneumol* 40 : 319-21, 2014
 8. Beaulieu S, Rubin B, Djang D, Conrad E, Turcotte E, Eary JF : Positron emission tomography of schwannomas : emphasizing its potential in preoperative planning. *AJR Am J Roentgenol* 182 : 971-974, 2004
 9. Togano S, Kubo N, Sakurai K, Toyokawa T, Ohira M, Hirakawa K : A case of a benign esophageal schwannoma with high uptake of 18F-FDG on FDG-PET scans. *J Jpn Surg Assoc* 76 : 720-725, 2015
 10. Isobe K, Shimizu T, Akahane T, Kato H : Imaging of ancient schwannoma. *AJR Am J Roentgenol* 183 : 331-336, 2004
 11. Lae HK, Dong HS, Seong HY : Schwannoma arising in mediastinal lymph node diagnosed by endobronchial ultrasound. *Respirol Case Rep* 7 : e00481, 2019
 12. Ohshiro S, Kugai T, Sunagawa K, Tomori H, Nakama T, Sunagawa T : Two cases of mediastinal schwannoma originating from the intrathoracic vagal nerve. *J Jpn Surg Assoc* 61 : 2302-2307, 2000
 13. Furusawa T, Oda M, Matsumoto I, Yachi T, Saito K, Watanabe G : A case of vagal nerve neurinoma with nerve preservation by video-assisted thoracic surgery. *Jpn J Chest Surg* 23 : 602-605, 2009
 14. Ohno T, Suzuki Y, Kadonaga T : A case of left intrathoracic vagal nerve schwannoma located proximal to a branch of the recurrent laryngeal nerve. *Jpn J Chest Surg* 28 : 730-734, 2014
 15. Mizutani T, Koh H, Sudo A, Kamiishi N, Kimura Y, Tajima A, Chiyotani A : A Case of mediastinal malignant peripheral nerve sheath tumor originated from vagus nerve which complicated with neurofibromatosis type 1. *J Jpn Soc Resp Endosc* 35 : 49-55, 2013