

CASE REPORT

A case report of super responder of critical COVID-19 pneumonia

Tomoo Kishaba¹, Akiko Maeda¹, Shou Fukuoka², Toru Imai², Shunichi Takakura³, Shuhei Yokoyama³, Soichi Shiiki³, Masashi Narita³, Daijiro Nabeya¹, and Hiroaki Nagano¹

¹Department of Respiratory Medicine, Okinawa Chubu Hospital, Japan, ²Department of Internal medicine, Okinawa Chubu Hospital, Japan, ³Department of Infectious Disease, Okinawa Chubu Hospital, Japan

Abstract : This report presents a case of a 74-year-old man who showed dramatic therapeutic response to treatment of coronavirus infectious disease-19 (COVID-19) pneumonia. He reported four-day history of sustained fever and acute progressive dyspnea. He developed severe respiratory failure, underwent urgent endotracheal intubation and showed marked elevation of inflammatory and coagulation markers such as c-reactive protein (CRP), ferritin, lactate dehydrogenase (LDH) and D-dimer. Chest computed tomography (CT) demonstrated diffuse consolidation and ground glass opacity (GGO). We diagnosed critical COVID-19 pneumonia with detailed sick contact history and naso-pharyngeal swab of a reverse-transcriptase-polymerase-chain reaction (RT-PCR) assay testing. He received anti-viral drug, anti-interleukin (IL-6) receptor antagonist and intravenous methylprednisolone. After commencing combined intensive therapy, he showed dramatic improvement of clinical condition, serum biomarkers and radiological findings. Early diagnosis and rapid critical care management may provide meaningful clinical benefit even if severe case. *J. Med. Invest.* 68:192-195, February, 2021

Keywords : ARDS, COVID-19, methylprednisolone, PCR, tocilizumab

INTRODUCTION

Coronavirus infectious disease-19 (COVID-19), caused by severe acute respiratory syndrome coronavirus-2 (SARS-CoV-2) has spread and over four million people have been infected throughout the world. SARS-CoV-2 infection has several risk factors for disease progression, including age, male sex, underlying comorbid disease, and obesity (1). Although optimal therapy has not been defined conclusively, anti-viral drugs and anti-inflammatory agents are the cornerstones of treatment (2). Elderly men with severe COVID-19 pneumonia often have a very poor prognosis. In 40% of symptomatic patients, they usually report dyspnea 7 days after development of initial symptoms (3). 5% of the COVID-19 patients presents critical illness. We herein report a case of a critically ill elderly man with COVID-19 pneumonia who was a super-responder to combination therapy. Written informed consent was obtained from the patient.

CASE REPORT

A 74-year-old Japanese man presented to our hospital with severe dyspnea and a sustained low-grade fever. He had a sick contact through meeting with a known index case of COVID-19 ten days prior to admission. His past medical history was hypertension. He had a 54-pack-year history of tobacco exposure and was a current smoker with heavy alcohol consumption. His initial vital signs were : blood pressure, 154/82 mmHg ; heart rate, 158 beats/minute ; respiratory rate, 20 breaths/minute ; body tem-

perature, 38.8°C. His SpO₂ was only 46% on a reservoir oxygen mask at 15 liters per minute, but his consciousness was clear. Body mass index was 22.6 kg/m². Physical examination showed severe acute distress. There was no lymphadenopathy. Chest auscultation revealed no adventitious sounds. Cardiovascular examination showed no murmurs, rubs and gallops. There were no rashes, petechiae, muscle pain and joint pain on the extremities. Chest radiography revealed bilateral peripheral dominant infiltration. Initial chest computed tomography (CT) showed diffuse extensive consolidation and ground glass opacity (GGO) with vascular enhancement. Over 80% of total lung parenchyma had interstitial features (Figure 1A and 1B). Laboratory

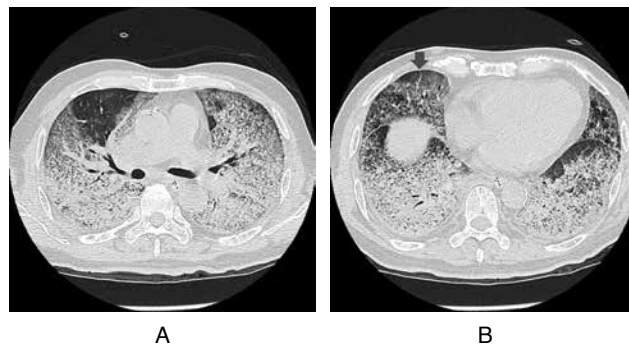


Figure 1. Chest CT during acute phase of illness
(a) Bilateral extensive GGO and consolidation at the subcarinal level.
(b) Inter-lobar fissure level, there were more dense consolidation in dorsal area. In addition, there was vascular enhancement sign (arrow).

Abbreviations

ARDS : acute respiratory distress syndrome, ALT : alanine aminotransferase, AST : aspartate aminotransferase, COVID-19 : coronavirus infectious disease-19, CRP : c-reactive protein, CT : computed tomography, FiO₂ : fraction of inspiratory oxygen, GGO : ground glass opacity, ICU : intensive care unit, IL-6 : interleukin-6, LDH : lactate dehydrogenase, MP : methylprednisolone, P/F ratio : ratio of arterial oxygen partial pressure to fractional inspired oxygen, RT-PCR : Reverse-transcriptase-polymerase-chain reaction, SARS-CoV-2 : severe acute respiratory syndrome coronavirus-2

Received for publication May 25, 2020 ; accepted September 16, 2020.

Address correspondence and reprint requests to Tomoo Kishaba, Department of Respiratory Medicine, Okinawa Chubu Hospital, Japan, Miyazato 281, Uruma City, Okinawa, Japan and Fax : +81-98-974-5165

tests showed : white blood cell count, 15900/mm³ ; lymphocytes 1065/mm³ ; c-reactive protein (CRP) 32 mg/dL ; lactate dehydrogenase (LDH), 801 U/L ; Ferritin 2767 ng/mL ; D-dimer 2.1 µg/mL. A reverse-transcriptase-polymerase-chain reaction (RT-PCR) assay detected the presence of SARS-CoV-2 RNA in nasopharyngeal swab (Table 1). Based on the result of PCR and medical interview, chest CT findings and laboratory examination, we diagnosed this case as critical COVID-19 pneumonia.

The patient underwent urgent endotracheal intubation and was admitted to the intensive care unit (ICU) for comprehensive management. Initial ratio of arterial oxygen partial pressure to fractional inspired oxygen (P/F ratio) was 115 in fractional inspired oxygen (FiO₂) 100% with positive end-expiratory pressure was 14 cm H₂O in the setting of pressure 20 cm H₂O and tidal volume was 360 ml with volume-controlled assist ventilation mode.

Due to the severity of disease in this patients, intensive therapy was initiated immediately, consisting of oral favipiravir 3600 mg/day, intravenous tocilizumab 480 mg (8 mg/kg/day) and intravenous methylprednisolone (MP) 60 mg/kg/day (1 mg/kg/day). Informed consent for treatment was obtained from the patient's family. Intravenous MP continued for five days and favipiravir continued at a maintenance dose with 1600 mg/day until he developed new erythema over his trunk and arms a few days after starting the regimen. Favipiravir was stopped on day 5 due to concern for possible adverse drug reaction, although the possibility of cutaneous manifestation of COVID-19 was possible. His clinical condition and oxygenation had improved significantly with intensive anti-inflammatory drugs and lung protective ventilation. On day 12, he was successfully extubated without complications such as respiratory muscle exhaustion or secretion difficulty. The clinical course is outlined in Figure 2, showing that serum CRP, ferritin, and D-dimer revealed marked decrease over the first week. In addition, the peripheral lymphocyte count increased to normal level accompanied by clinical improvement. A repeat chest CT performed on the day of extubation demonstrated dramatic improvement of his diffuse infiltrates (Figure 3A and 3B). After transfer to medical ward, he recovered uneventfully without supplemental oxygen and underwent rehabilitation. He was discharged home after two consecutive nasopharyngeal swabs were negative by PCR.

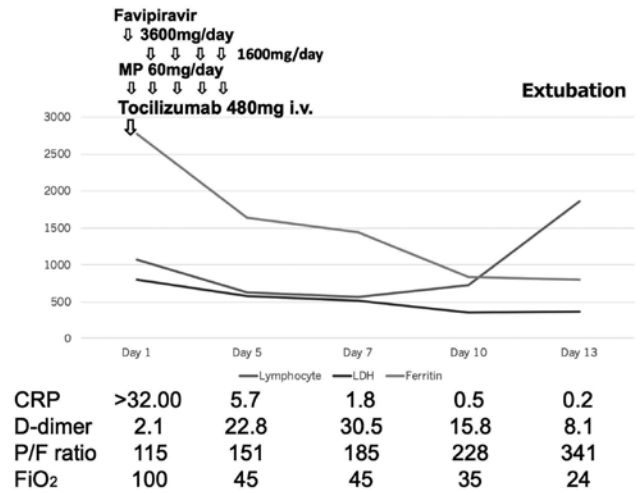


Figure 2. Clinical course

Definitions of abbreviations : MP = methylprednisolone ; CRP = c-reactive protein ; P/F ratio = ratio of arterial oxygen partial pressure to fractional inspired oxygen ; FiO₂ = fractional inspired oxygen.

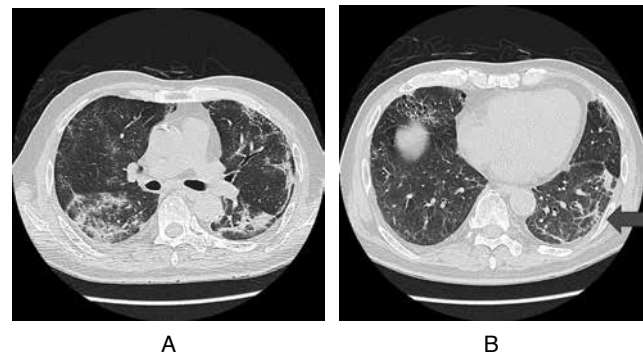


Figure 3. Chest CT during the recovery phase

- (a) Marked improvement in the extensive infiltrates at the subcarinal level.
- (b) At the inter-lobar fissure level, dense consolidation was dramatically improved with organization (arrow).

Table 1. Laboratory findings on admission

Hematology		Chemistry	
White blood cell	15900/µL	Blood urea nitrogen	26 mg/dL
Neutrophil	89.1%	Creatinine	0.94 mg/dL
Lymphocyte	6.7%	Sodium	139 mmol/L
Eosinophil	0%	Potassium	4.1 mmol/L
Red blood cell	4.33 × 10 ⁶ /µL	LDH	801 U/L
Hemoglobin	14.3 g/dL	AST	170 U/L
Hematocrit	42.3%	ALT	144 U/L
Platelet	196000/µL	C-reactive protein	32 mg/dL
		Ferritin	2767 ng/mL
Coagulation		Infection panel	
D-dimer	2.1 µg/mL	Nasopharyngeal COVID-19 RT-PCR (+)	

Definition of abbreviations : LDH = lactate dehydrogenase ; AST = aspartate aminotransferase ; ALT = alanine aminotransferase ; COVID-19 = Coronavirus infectious disease-19 ; RT-PCR = Reverse-transcriptase-polymerase-chain reaction.

DISCUSSION

SARS-CoV-2 was identified in China during December 2019. This virus causes disease of variable severity, ranging from asymptomatic cases to critical illness requiring mechanical ventilation and vasopressor support, complicated by multi organ failure (4). Approximately 80% of infected patients present with mild disease, 15% cases have more severe presentations, and 5% are critically ill (5). Several risk factors have been reported for development of COVID 19 such as age, male, obesity, smoking, hypertension, diabetes mellitus, chronic kidney disease, cardiovascular disease, chronic lung disease, malignancy and immunosuppression (6). Furthermore, the risk factors for overwhelming of COVID-19 progression have also been clarified, including elevated CRP, ferritin, and D-dimer, and decreased lymphocyte counts (7). Our case had four risk factors including age, male sex, tobacco exposure, and hypertension. Regarding hypertension, our case received amlodipine besilate. During admission, his blood pressure was relatively well controlled without anti-hypertension drug. In patients with COVID-19, there is a

report that ACE2 is down-regulated after the SARS-CoV-2 is infected through ACE2, resulting in continuous hypertension by persistent activation of Renin-Angiotensin-Aldosterone System (8). Hypertension is risk factor. However, any medication class had no association with severe illness of COVID-19. Therefore, adequate management of blood pressure is important. In addition, his laboratory risk factors for disease progression included elevated CRP, ferritin, and D-dimer. Furthermore, his initial chest CT demonstrated diffuse extensive consolidation and GGO which resembled severe acute respiratory distress syndrome (ARDS). Therefore, he showed very severe COVID-19 pneumonia initially with potential for a poor outcome. However, his actual outcome was favorable after a dramatic clinical response to intensive therapy with favipiravir, tocilizumab, and MP. At April 2020, remdesivir was not available in Japan. Therefore, we used favipiravir, methylprednisolone and tocilizumab for our case. We feel that early intervention with this regimen may provide effective rescue therapy for similar cases of critical COVID-19 pneumonia.

From clinical and imaging response of our case, what appeared to be extensive consolidation and GGO might have been reversible organizing diffuse alveolar damage (DAD) with vascular invasion. In addition, bronchial dilatation was not significant on the initial chest CT. Therefore, this patient's clinical stage coincided with the organizing phase rather than the fibrotic phase of ARDS (9, 10).

Anti-viral and anti-inflammatory medications are the two core pillars of the management of severe COVID-19 pneumonia. Favipiravir is an anti-viral agent that blocks replication of RNA-viruses. Several reports have shown clinical effectiveness of favipiravir for COVID-19 pneumonia (11). Favipiravir may be used with careful monitoring of liver function and uric acid. Pregnancy is a contraindication for favipiravir due to the possibility of fetal anomalies. We hypothesize that early introduction of favipiravir can promote more effective suppression of virus replication.

Tocilizumab is an interleukin-6 (IL-6) receptor antagonist which is usually used for IL-6 mediated diseases such as rheumatoid arthritis, and multi-centric Castleman disease. For critical COVID-19 pneumonia, IL-6 associated cytokine storm often plays a major role in disease progression, so tocilizumab likely contributes by reducing the chance of virus associated cytokine storm in COVID-19 severe pneumonia (12, 13). Recently, two retrospective cohort study about effectiveness of tocilizumab for severe COVID-19 pneumonia were reported. Guaraldi *et al.*, reported that tocilizumab treatment was associated with a reduced risk of invasive mechanical ventilation or death (adjusted hazard ratio 0.61, 95% confidence interval [CI] 0.40-0.92; $p = 0.020$). 24 (13%) of 179 patients treated with tocilizumab were diagnosed with new infections, versus 14 (4%) of 365 patients treated with standard of care alone ($p < 0.0001$) (14). Kewan *et al.* also reported that the median time to clinical improvement in tocilizumab vs. no tocilizumab cohorts was 8 days (Interquartile range [IQR]: 6.25-9.75 days) vs. 13 days (IQR: 9.75-15.25 days) among patients who required mechanical ventilation at any time (Hazard ratio for clinical improvement: 1.83, 95% CI: 0.57-5.84). The median duration of vasopressor support and invasive mechanical ventilation were 2 days (IQR: 1.75-4.25 days) vs. 5 days (IQR: 4-8 days), $p = 0.039$, and 7 days (IQR: 4-14 days) vs. 10 days (IQR: 5-15 days) in tocilizumab vs. no tocilizumab cohorts, $p = 0.11$, respectively (15). Our case showed marked elevation of CRP, LDH and ferritin and very severe ARDS status. Based on these clinical information, we considered our case as virus associated cytokine storm state. When tocilizumab is used, monitoring for the development of bacterial infection and decreased CRP is essential.

The use of intravenous corticosteroids is controversial for viral pneumonia. Intravenous corticosteroids showed no clinical benefit for SARS or Middle East respiratory syndrome, because of delayed viral clearance and secondary infection due to corticosteroid (16). There are no controlled clinical trials of corticosteroids in COVID-19 pneumonia. However, several reports have shown that low dose, short-term methylprednisolone was associated with shorter durations of supplemental oxygen or reduction of need for mechanical ventilation in COVID-19 and community-acquired pneumonia with septic shock (17, 18). Based on these data, Infectious Disease Society of America guideline panel recommends the use of corticosteroids in the context of a clinical trial for ARDS due to COVID-19. Our experience suggests that low dose, short-term use of methylprednisolone might be beneficial in cases of COVID-19 pneumonia with severe ARDS.

In conclusion, we observed a super-responder to intensive therapy for critical COVID-19 pneumonia. Early introduction of intensive combination therapy requires suppression of both viral replication and inflammation, especially control of cytokine storm, in order to secure good outcomes in patients with critical COVID-19 pneumonia.

CONFLICT OF INTEREST DISCLOSURE

All authors have no conflict of interest.

ACKNOWLEDGEMENTS

We thank for all ICU, infection medical ward and emergency department staff of Okinawa Chubu Hospital.

In addition, we thank Dr. Rita McGill, Division of Nephrology, University of Chicago and Kenneth Sumida, Department of Oncology, Hawaii University for English editing.

AUTHORS' CONTRIBUTIONS

T.K.: This author helped the conception, design, acquisition of data, interpretation of data and drafting article of the study.

A.K.: This author helped the conception, acquisition and interpretation of data of the study.

S.F.: This author helped acquisition of data of the study.

T.I.: This author helped acquisition of data of the study.

S.T.: This author helped the conception, design, acquisition of data, interpretation of data of the study.

S.Y.: This author helped the conception, acquisition of data, interpretation of data of the study.

S.S.: This author helped the conception, design of the study.

M.N.: This author helped the conception, design, interpretation of data of the study.

D.N.: This author helped the conception, acquisition of data, interpretation of data of the study.

H.N.: This author helped the conception, acquisition of data, interpretation of data of the study.

REFERENCES

1. Yu T, Cai S, Zheng Z, Cai X, Liu Y, Yin S, Peng J, Xu X: Association Between Clinical Manifestations and Prognosis in Patients With COVID-19. *Clin Ther*: S0149-2918(20)30197-1, 2020
2. Douedi S, Miskoff J: Novel Coronavirus 2019 (COVID-19): A Case Report and Review of Treatments. *Medicine*

- (Baltimore) 99(19) : e20207, 2020
3. Berlin DA, Gulick RM, Martinez FJ : Severe Covid-19. *New Engl J Med*, 2020 online ahead of print.
 4. Feng Y, Ling Y, Bai T, Xie Y, Huang J, Li J, Xiong W, Yang D, Chen R, Lu F, Lu Y, Liu X, Chen Y, Li X, Li Y, Summah HD, Lin H, Yan J, Zhou M, Lu H, Qu J : COVID-19 With Different Severity : A Multi-center Study of Clinical Features. *Am J Respir Crit Care Med*, 2020 Online ahead of print
 5. Chen N, Zhou M, Dong X, Qu J, Gong F, Han Y, Qiu Y, Wang J, Liu Y, Wei Y, Xia J, Zhang XYT, Zhang L : Epidemiological and clinical characteristics of 99 cases of 2019 novel coronavirus pneumonia in Wuhan, China : a descriptive study. *Lancet* 395(10223) : 507-513, 2020
 6. Huang R, Zhu L , Xue L, Liu L, Yan X, Wang J, Biao Z, Tianmin X, Fang J, Zhao Y, Cheng J, Wang Y, Shao H, Hong S, Cao Q, Li C, Zhao XA, Zou L, Sang D, Zhao H, Guan X, Chen X, Shan C, Xia J, Chen Y, Wei XYJ, Zhu C, Wu C : Clinical Findings of Patients With Coronavirus Disease 2019 in Jiangsu Province, China : A Retrospective, Multi-Center Study. *PLoS Negl Trop Dis* 14(5) : e0008280, 2020
 7. Hou W, Zhang W, Jin R, Liang L, Xu B, Hu Z : Risk Factors for Disease Progression in Hospitalized Patients With COVID-19 : A Retrospective Cohort Study. *Infect Dis (Lond)* : 1-8, 2020
 8. Reynolds HR, Adhikari S, Pulgarin C, Troxel AB, Iturrate E, Johnson SB, Hausvater A, Newman JD, Berger JS, Bangalore S, Katz SD, Fishman GI, Kunichoff D, Chen Y, Ogedegbe G, Hochman JS : Renin-Angiotensin-Aldosterone System Inhibitors and Risk of Covid-19. *N Engl J Med* 382(25) : 2441-2448, 2020
 9. Ichikado K, Muranaka H, Gushima Y, Kotani T, Habashi NM, Fujimoto K, Johkoh T, Iwamoto N, Kawamura K, Nagano J, Fukuda K, Hirata N, Yoshinaga T, Ichiyasu H, Tsumura S, Kohrogi H, Kawaguchi A, Yoshioka M, Sakuma T, Suga M : Fibroproliferative Changes on High-Resolution CT in the Acute Respiratory Distress Syndrome Predict Mortality and Ventilator Dependency : A Prospective Observational Cohort Study. *BMJ Open* 2(2) : e000545, 2012
 10. Liu F, Zhang Q , Huang C, Shi C, Wang L, Shi N, Fang C, Shan F, Mei X, Shi J, Song F, Zhang Z, Ding Z, Su X, Lu H, Zhu T, Zhang Z, Shi L, Shi Y : CT Quantification of Pneumonia Lesions in Early Days Predicts Progression to Severe Illness in a Cohort of COVID-19 Patients. *Theranostics* 10(12) : 5613-5622, 2020
 11. Khambholja K, Asudani D : Potential Repurposing of Favipiravir in COVID-19 Outbreak Based on Current Evidence. *Travel Medi Infect Dis* : 101710, 2020
 12. Mehta N, Mazer-Amirshahi M, Alkindi N, Pourmand A : Pharmacotherapy in COVID-19 ; A narrative review for emergency providers. *Am J Emerg Medi* : S0735-6757(20)30263-1, 2020
 13. Toniati P, Piva S, Cattalini M, Garrafa E, Regola F, Castelli F, Franceschini F, Foca E, Andreoli L, Latronico N : International Research and Training HUB (BIRTH) : Tocilizumab for the Treatment of Severe COVID-19 Pneumonia With Hyperinflammatory Syndrome and Acute Respiratory Failure : A Single Center Study of 100 Patients in Brescia, Italy. *Autoimmun Rev* : 102568, 2020
 14. Guaraldi G, Meschiari M, Lepri AC, Milic J, Tonelli R, Menozzi M, Franceschini E, Cuomo G, Orlando G, Borghi V, Santoro A, Gaetano MD, Puzzolante C, Carli F, Bedini A, Corradi L, Fantini R, Castaniere I, Tabbi L, Girardis M, Tedeschi S, Giannella M, Bartoletti M, Pascale R, Dolci G, Brugioni L, Pietrangelo A, Cossarizza A, Pea F, Clini E, Salvarani C, Massari M, Viale PL, Mussini C : Tocilizumab in patients with severe COVID-19 : a retrospective cohort study. *Lancet Rheumatol* : Published Online, 2020
 15. Kewan T, Covut F, Al-Jaghbeer MJ, Rose L, Gopalakrishna KV, Akbik B : Tocilizumab for treatment of patients with severe COVID19 : A retrospective cohort study. *EClinicalMedicine* 24 : 100418, 2020
 16. Alhazzani W, Møller MH, Arabi YM, Loeb M, Gong MN, Fan E, Oczkowski S, Levy MM, Derde L, Dzierba A, Du B, Aboodi M, Wunsch H, Cecconi M, Koh Y, Chertow DS, Maitland K, Alshamsi F, Belley-Cote E, Greco M, Laundry M, Morgan JS, Kesecioglu J, McGeer A, Mermel L, Mammen MJ, Alexander PE, Arrington A, Centofanti JE, Citerio G, Baw B, Memish ZA, Hammond N, Hayden FG, Evans L, Rhodes A : Surviving Coronavirus Disease 2019 (COVID-19). *Critl Care Med* 10 : 1097, 2020
 17. Wang Y, Jiang W, He Q, Wang C, Wang B, Zhou P, Dong N, Tong Q : Early, low-dose and short-term application of corticosteroid treatment in patients with severe COVID-19 pneumonia : single-center experience from Wuhan, China. *medRxiv* : 03.06.20032342, 2020
 18. Bhimraj A, Morgan RL, Shumaker AH, Lavergne V, Baden L, Cheng VCC, Edwards KM, Gandhi R, Muller WJ, O'Horo JC, Shoham S, Murad MH, Mustafa RA, Sultan S, Falck-Ytter Y : Infectious Diseases Society of America Guidelines on the Treatment and Management of Patients with COVID-19. *Clin Infect Dis* : 2020 Online ahead of print