

CASE REPORT

Early Diagnosis of the Cardiopulmonary Collapse Type of Amniotic Fluid Embolism with Obstetrical Disseminated Intravascular Coagulation during Elective Cesarean Section : A Case Report

Yuki Ishikawa¹, Yuki Hari¹, Chiaki Murakami¹, Yasuhiro Honda¹, Takuro Oyama¹, Ryosuke Kawanishi¹, Nami Kakuta¹, Yoko Sakai¹, Takashi Kaji², Yasuo M. Tsutsumi³, and Katsuya Tanaka¹

¹Department of Anesthesiology, Tokushima University Graduate School, Tokushima, Japan, ²Department of Obstetrics and Gynecology, Tokushima University Graduate School, Tokushima, Japan, ³Department of Anesthesiology and Critical Care, Hiroshima University, Hiroshima, Japan

Abstract : Two types of amniotic fluid embolism (AFE) have been described: cardiopulmonary collapse type and disseminated intravascular coagulation (DIC) type, with the latter proposed as uterine type. This report describes a healthy 28-year-old woman who developed AFE during a cesarean section. Because of a previous cesarean section, the patient underwent an elective cesarean section, under combined spinal-epidural anesthesia, at 38 weeks of pregnancy. She began coughing 5 minutes after delivery of the fetus, subsequently becoming unconscious and developing glossoptosis and bradycardia. Her blood pressure decreased to 76/43 mmHg, and AFE was suspected. Her uterus was atonic, and she experienced persistent noncoagulant bleeding, with a final blood loss of 6300 ml. Considerable blood transfusion was required. The patient survived, and she and her baby were discharged without any sequelae on the eighth postoperative day. This patient met the Japanese criteria for clinical AFE, with an obstetrical DIC score of 21 meeting the criteria for obstetrical DIC. Early diagnosis and treatment likely resulted in patient survival. *J. Med. Invest.* 67:207-210, February, 2020

Keywords : amniotic fluid embolism, cardiopulmonary collapse type, cesarean section, disseminated intravascular coagulation

INTRODUCTION

Amniotic fluid embolism (AFE) is a rare disease caused by the flow of amniotic fluid or fetal components into the maternal bloodstream. Two types of AFE have been described: cardiopulmonary collapse type and disseminated intravascular coagulation (DIC) type, with the latter proposed as uterine type (1). Cardiopulmonary collapse type starts with pulmonary/respiratory symptoms but uterine type starts with atonic bleeding/DIC (2).

This report describes a patient with cardiopulmonary collapse type AFE and obstetrical DIC during an elective cesarean section under combined spinal-epidural anesthesia. The patient developed dyspnea and hypotension 5 minutes after cesarean delivery, followed by DIC, suggesting AFE. Transesophageal echocardiography (TEE) indicated collapse of the right heart, but not right ventricular failure. The patient was effectively treated for AFE, and she and her baby were able to leave the hospital safely.

CASE REPORT

A 28-year-old woman underwent an elective cesarean section at 38 weeks of pregnancy because of a previous cesarean section. Her preoperative general condition was good. At 22 weeks of

pregnancy, she had undergone fetal thoracoamniotic shunting under general anesthesia for fetal pleural fluid, but her subsequent course was good. Preoperative laboratory findings were as follows: hemoglobin concentration 10.5 g/dl, platelet count $34.3 \times 10^4/\mu\text{L}$, prothrombin time-international normalized ratio (PT-INR) 0.94, activated partial thromboplastin time (APTT) 25.3 sec, and fibrinogen (FIB) concentration 672 mg/dl. Preoperative electrocardiogram and chest X-ray were normal.

Surgery was performed under combined spinal-epidural anesthesia. Before anesthesia, her blood pressure (BP) was 114/67 mmHg and her heart rate (HR) was 102 bpm. An epidural catheter was placed on Th11/Th12, and 2.0 ml of 0.5% hyperbaric bupivacaine 10 mg and 10 μg fentanyl were administered to the spinal subarachnoid space from L3/L4. Surgery was started 10 minutes after anesthesia, and the fetus was delivered 10 minutes later. The patient began coughing 5 minutes after delivery of the fetus, subsequently becoming unconscious and developing glossoptosis. Her HR dropped to about 30 bpm for a few seconds, spontaneously recovering a few seconds later to 73 bpm, and her BP decreased to 76/43 mmHg, suggesting AFE. Although she returned to consciousness 5 minutes later, general anesthesia was induced. Sedation was started and her trachea was intubated. Eight minutes later, hemodynamics were assessed by TEE, which showed that her entire heart was hyperkinetic and that her right heart had collapsed. Approximately 30 minutes after delivery of the fetus, she had lost approximately 800 ml blood. Her BP decreased to 56/32 mmHg and her HR increased to 125 bpm, making her Shock Index ≥ 2 . Her uterus was atonic, and noncoagulant bleeding persisted. Blood transfusion and adrenaline treatment were started. After two bolus injections of 0.1 mg adrenaline, she was started on continuous infusion of 0.1 $\mu\text{g}/\text{kg}/\text{min}$ adrenaline, along with 0.3 $\mu\text{g}/\text{kg}/\text{min}$ noradrenaline.

Received for publication September 13, 2019; accepted October 31, 2019.

Address correspondence and reprint requests to Yuki Ishikawa, M.D., Clinical Fellow, Department of Anesthesiology, Tokushima University Graduate School, 3-18-15 Kuramoto, Tokushima 770-8503, Japan and Fax: +81-886-33-7182.

When her fibrinogen concentration dropped to 106 mg/dl, she was administered a cryoprecipitate made of 12 units of fresh frozen plasma (FFP), along with platelet concentrate (PC). After attainment of a degree of surgical hemostasis and stabilization of vital signs, the operation was completed. Her uterus was saved, and she was transferred to the ICU without extubation and without treatment with catecholamines. Her final blood loss was 6300 ml. During the surgery, which lasted 5 hours and 55 minutes, she was administered 18 units of red blood cells (RBC), 18 units of FFP, 10 units of PC, and cryoprecipitate made from 12 units of FFP. Intraoperative anesthetic course is shown in Figure 1.

Blood samples were obtained immediately after the sudden change in patient condition. Intraoperative serum laboratory findings were as follows: zinc coproporphyrin-1 (Zn-CP1) < 1.6 pmol/mL (normal, < 1.6 pmol/mL), sialyl-Tn antigen (STN) 36 U/mL (normal, < 45 U/mL), complement factor 3 (C3) 111.0 mg/dL (normal, 80–140 mg/dL), C4 11.0 mg/dL (normal, 11.0–34.0 mg/dL), and C1 inhibitor activity < 25% (normal, > 42.0%) (Table 1). Zn-CP1 and STN are markers indicating that amniotic fluid has flowed into maternal blood. C1 inhibitor activity and C3 and C4 concentrations are often low in patients with AFE. In the present case, Zn-CP1 and STN concentrations were within normal ranges, with only C1 inhibitor activity being below the standard value.

Two hours after admission to the ICU, her vital signs became stable and the patient was extubated. She was conscious, with no neurological abnormalities. She was administered four units of FFP and 10 units of PC on the first postoperative day, with no further blood transfusions required. She and her baby showed good progress, and both were discharged on the eighth postoperative day.

DISCUSSION

AFE is a very rare disease, with an incidence of approximately 1 in 40,000 deliveries, but has a high mortality rate, ranging

from 20% to 60% (3). The cardiopulmonary collapse type of AFE is thought to be due to mechanical obstruction of the pulmonary artery by amniotic fluid, whereas the uterine type is thought to be due primarily to anaphylactoid reaction mechanisms (4, 5).

The characteristics of this patient met the Japanese criteria for clinical AFE (Table 2) (6). Moreover, her obstetrical DIC score was 21 (Table 3), indicating that she met the criteria for

Table 1. Auxiliary diagnostic markers of AFE in blood

Inspection items	Results	Normal values
Zn-CP1	< 1.6 pmol/ml	< 1.6 pmol/ml
STN	36.0 U/ml	< 45.0 U/ml
Complement C3	111.0 mg/dl	80-140 mg/dl
Complement C4	11.0 mg/dl	11.0-34.0 mg/dl
C1 inhibitor activity	< 25.0 %	> 42.0 %

AFE, amniotic fluid embolism; STN, Sialyl-Tn; Zn-CP1, Zinc-coproporphyrin-1. Only C1 inhibitor activity was outside the normal value.

Table 2. Japanese criteria of amniotic fluid embolism (AFE)

- (1) If symptoms appeared during pregnancy or within 12 h of delivery.
- (2) If any intensive medical intervention was conducted to treat one or more of the following symptoms/diseases:
 - A) Cardiac arrest
 - B) Severe bleeding of unknown origin within 2 h of delivery (≥ 1500 mL)
 - C) Disseminated intravascular coagulation
 - D) Respiratory failure
- (3) If the findings or symptoms obtained cannot be explained by other diseases.

A clinical diagnosis of AFE can be made if the pathological condition meets the above three criteria.

Because these diagnostic criteria serve the purpose of making a clinical diagnosis and being able to promptly provide treatment, the pathological conditions that meet them may include those other than AFE.

This case met (1), (2) C, (3) above.

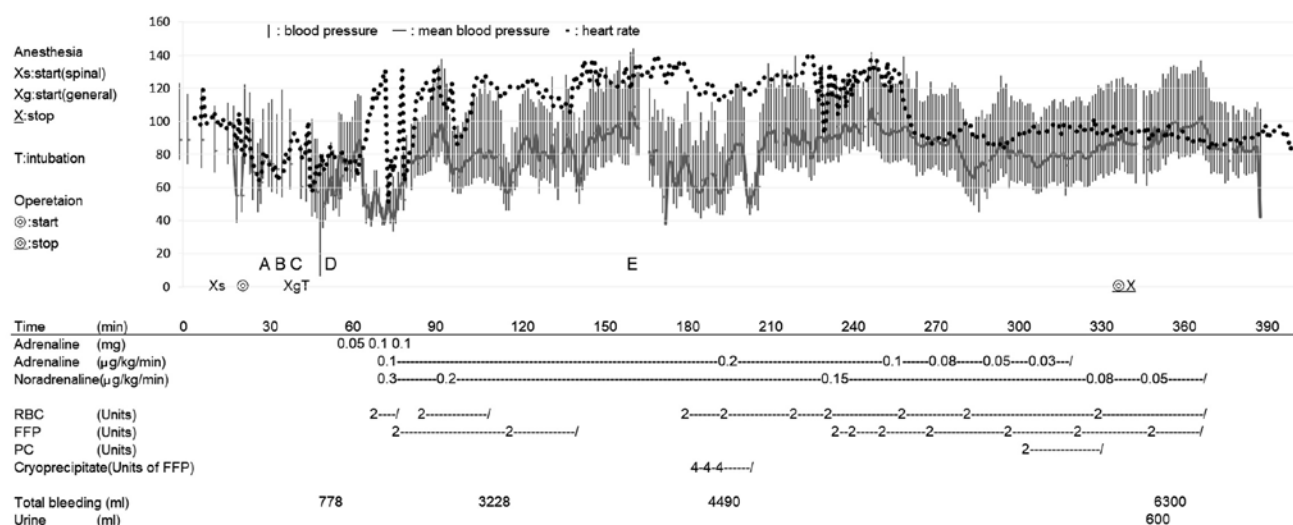


Figure 1. Intraoperative anesthetic course. FFP, fresh frozen plasma; PC, platelet concentrate; RBC, red blood cell. A: Fetal delivery, the Apgar score was 7 (one minute) and 10 (five minutes). B: Suddenly she began coughing, subsequently becoming unconscious. The heart rate dropped to about 30 bpm for a few seconds. C: She returned to consciousness, but general anesthesia was induced. D: Hemodynamics was assessed by transesophageal echocardiography. E: Hemoglobin concentration 4.9 g/dl, platelet count $17.4 \times 10^9/\mu\text{L}$, prothrombin time-international normalized ratio (PT-INR) 2.22, activated partial thromboplastin time (APTT) 67.4 sec, fibrinogen (FIB) concentration 106 mg/dl, and antithrombin III activity 43.9%.

Table 3. Obstetrical DIC score

	(Score)
1. Underlying diseases ; Only one of these items will be adopted as the score of underlying diseases.	
a. Placental abruption	
• Stiffening of the uterus, death of the fetus	(5)
• Stiffening of the uterus, survival of the fetus	(4)
• Confirmatory diagnosis of placental abruption by ultrasonic tomographic findings and CTG findings	(4)
b. Amniotic fluid embolism	
• Acute cor pulmonale	(4)
• Artificial ventilation	(3)
• Assisted respiration	(2)
• Oxygen flux alone	(1)
c. DIC-type postpartum hemorrhage	
• In case the blood from the uterus has low coagulability	(4)
• Hemorrhage of 2000 mL ≤ (within 24 h after the start of hemorrhage)	(3)
• Hemorrhage of 1000 mL ≤ , but not exceeding 2000 mL (within 24 h after the start of hemorrhage)	(1)
d. Eclampsia	
• Eclamptic attack	(4)
e. Severe infection	
• Those with fever accompanied by shock, bacteremia, and endotoxemia	(4)
• Continued fever or remittent fever	(1)
f. Other underlying diseases	(1)
2. Clinical symptoms	
a. Acute renal failure	
• Anuria (≤ 5 mL/hr)	(4)
• Oliguria (5–20 mL/hr)	(3)
b. Acute respiratory failure (amniotic fluid embolism excluded)	
• Artificial ventilation or occasional assisted respiration	(4)
• Oxygen flux alone	(1)
c. Organ failure	
• Heart (rales or foamy sputum, etc.)	(4)
• Liver (visible jaundice, etc.)	(4)
• Brain (clouding of consciousness, convulsion, etc.)	(4)
• Digestive tract (necrotic enteritis, etc.)	(4)
• Other severe organ failure	(4)
d. Hemorrhage diathesis	(4)
Macroscopic hematuria and melena, purpura, hemorrhage from the mucous membrane, gingival bleeding, bleeding at the site of injection, etc.	
e. Shock symptoms	
• Pulse rate ≥ 100/min	(1)
• Blood pressure ≤ 90 mmHg (systolic) or blood pressure reduction of ≥ 40%	(1)
• Cold sweat	(1)
• Pallor	(1)
3. Laboratory findings	
• Serum FDP ≥ 10 µg/mL	(1)
• Platelet counts ≤ 10 × 10 ⁴ /µL	(1)
• Fibrinogen ≤ 150 mg/dL	(1)
• PT ≥ 15 (s) (≤ 50%) or heparin test ≤ 50%	(1)
• Erythrocyte sedimentation rate ≤ 4 mm/15 min or ≤ 15 mm/hr	(1)
• Bleeding time ≥ 5 min	(1)
• Other coagulation and fibrinolysis factors ; AT ≤ 18 mg/dL or ≤ 60%, prekallikrein, α ₂ -PI, plasminogen, other coagulation factors ≤ 50%	(1)

α₂-PI, α₂-plasmin inhibitor ; AT, antithrombin ; CTG, cardiotocography ; DIC, disseminated intravascular coagulation ; FDP, fibrin degradation product ; PT, prothrombin time.

Obstetrical DIC could be diagnosed to initiate therapy for DIC when the obstetrical DIC score reaches 8 points or more without waiting for the results of coagulation tests.

An obstetrical DIC score ≥ 13 points, including at least two coagulation tests, however, is compatible to the diagnostic criteria for DIC.

This case met 1b (artificial ventilation), 2b (artificial ventilator), 2c (brain), 2d, 2e (pulse rate, blood pressure), 3 (FDP, platelet, fibrinogen, PT), and the total score was 21 points.

obstetrical DIC (7). In the present case, it was diagnosed clinically as cardiopulmonary collapse type of AFE (2), because dyspnea and loss of consciousness were the first symptoms. As there was no pathological specimen, a definitive diagnosis could not be made in the present case. But the serum AFE diagnostic marker was positive for C1 inhibitor activity. Oda *et al.*, suggested that C1 inhibitor activity is superior as a pathophysiologic indicator to markers that reflect amniotic fluid influx into the maternal circulation (11). Tamura *et al.*, demonstrated that low C1 inhibitor activity levels were closely associated with the pathogenesis of AFE suggesting that C1 inhibitor activity level have potential as a prognosis factor of AFE (12).

On the other hand, this case had two contradictory findings as cardiopulmonary collapse type. One was the findings of TEE. When entry of amniotic fluid into the maternal circulation resulted in obstruction of pulmonary capillaries by amniotic fluid emboli, leading to cardiovascular collapse, the images of TEE may demonstrate severe pulmonary hypertension, acute right ventricular failure with a leftward deviation of the interatrial and interventricular septum, and a cavity-obiterated left ventricle during the early phase of AFE (8). However, intraoperative TEE showed that her right ventricle collapse and hyperkinetic movement of left ventricle, but not acute right ventricular failure. These findings suggest that anaphylaxis-like vasodilation, but not pulmonary embolism, occurred in the present case.

The other one was serum test findings. Supplemental diagnostic markers for AFE in maternal serum include Zn-CP1, STN, C3, C4, and IL-8. Zn-CP1 and STN tend to be high in patients with the cardiopulmonary collapse type of AFE. C3 and C4 are low in uterine type AFE (6). In the present case, C1 inhibitor activity was low and C4 was at the lower limit of normal, but Zn-CP 1 and STN did not meet the diagnostic criteria (Table 1). These findings suggest that the anaphylactoid reaction was central to the condition, while the influx of fetal components was small. The reaction caused vasodilation and hypotension, and combined the blood loss due to hemorrhage may also result in the Bezold-Jarisch reflex. As the results, she had bradycardia, dyspnea, and loss of consciousness. Although no histopathological diagnosis can be made due to the absence of tissue removal including the uterus, it may be possible as one of the hypotheses.

It is reported that the presence of fetal cells in the pulmonary vessels is not reliable for diagnostic criterion for AFE, as fetal components can be detected in 21% of pregnant women without AFE (1, 8). Recently, the onset of AFE is thought to require two conditions: (1) an influx of fetal components into the maternal circulation, and (2) a significant pulmonary embolus or maternal immune/anaphylactoid reaction against the amniotic fluid or fetal components (1). In the present case, immun reaction predominated, and anaphylactoid reaction and DIC were thought to be caused.

Few reports to date have described patients experiencing AFE during cesarean section. Initial symptoms of AFE include hypotension, dyspnea, loss of consciousness, and seizure-like activity (3), with the sudden appearance of these symptoms during awake cesarean section indicating suspected AFE. Early diagnosis and treatment are important for patient survival (3). Depending on the symptoms, airway and/or vascular management may be required. DIC indicates the need for blood transfusion, especially of FFP (fibrinogen). Some patients may also require extracorporeal membrane oxygenation or intra-aortic balloon pumping (9). Because a patient with AFE developed acute respiratory distress syndrome 24 hours after cesarean section, patients should be carefully monitored for several days after AFE (10).

Reported risk factors for AFE include maternal age ≥ 35 years, cesarean delivery, forceps-assisted and vacuum-assisted vaginal deliveries, placenta previa, abruption placenta, eclampsia, and fetal distress (8). The patient described in this report had undergone a cesarean delivery. Although she also underwent fetal thoracoamniotic shunting surgery at 22 weeks of pregnancy, we found no evidence indicating that fetal surgery was a risk factor for AFE. However, fetal surgery may sensitize the mother to immunologic reaction to amniotic fluid.

In the present case, the uterus was preserved and the patient survived without any sequelae because of early treatment and proper blood transfusion and whole body management. AFE should be considered if the condition of the patient changes suddenly during cesarean section.

CONFLICT OF INTEREST

The authors declare that they have no conflicts of interest.

REFERENCES

1. Tamura N, Farhana M, Oda T, Itoh H, Kanayama N : Amniotic fluid embolism : Pathophysiology from the perspective of pathology. *J Obstet Gynaecol Res* 43 : 627-632, 2017
2. Kobayashi H, Akasaka J, Naruse K, Sado T, Tsunemi T, Niuro E, Iwai K : Comparison of the Different Definition Criteria for the Diagnosis of Amniotic Fluid Embolism. *Journal of Clinical and Diagnostic Research* 11(7) : QC18-QC21, 2017
3. Clark SL : Amniotic fluid embolism. *Obstet Gynecol* 123 : 337-348, 2014
4. Clark SL, Hankins GD, Dudley DA, Dildy GA, Porter TF : Amniotic fluid embolism : Analysis of the national registry. *Am J Obstet Gynecol* 172 : 1158-1169, 1995
5. Gist RS, Stafford IP, Leibowitz AB, Beilin Y : Amniotic fluid embolism. *Anesth Analg* 108 : 1599-1602, 2009
6. Kanayama N, Tamura N : Amniotic fluid embolism : Pathophysiology and new strategies for management. *J Obstet Gynaecol Res* 40 : 1507-1517, 2014
7. Kobayashi T : Obstetrical disseminated intravascular coagulation score. *J Obstet Gynaecol Res* 40 : 1500-1506, 2014
8. Conde-Agudelo A, Romero R : Amniotic fluid embolism : an evidence-based review. *Am J Obstet Gynecol* 201 : 445.e1-13, 2009
9. Mita K, Tsugita K, Yasuda Y, Matsuki Y, Obata Y, Matsuki Y, Kamisawa S, Shigemi K : A successfully treated case of cardiac arrest after Caesarean section complicated by pheochromocytoma crisis and amniotic fluid embolism. *J Anesth* 31 : 140-143, 2017
10. Yamagishi S, Irikoma S, Kokubo S : A Case Report of Pulmonary Edema 2 Postoperative Days after Early Successful Treatment of Amniotic Fluid Embolism. *The Journal of Japan Society for Clinical Anesthesia* 34 : 86-89, 2014 (in Japanese)
11. Oda T, Tamura T, Kanayama N : Japanese viewpoint on amniotic fluid embolism. *Am J Obstet Gynecol* 217 : 91, 2017
12. Tamura N, Kimura S, Mustari F, Uchida T, Suzuki K, Sugihara K, Itoh H, Ikeda T, Kanayama N : C1 Esterase Inhibitor Activity in Amniotic Fluid Embolism. *Crit Care Med* 42 : 1392-1396, 2014