

## OTHERS

# Intraoperative analysis of the kinematics of the native knee including two-dimensional translation of the femur using a navigation system : a cadaveric study

Keizo Wada<sup>1</sup>, Daisuke Hamada<sup>1</sup>, Tomoya Takasago<sup>1</sup>, Mitsuhiro Kamada<sup>1</sup>, Tomohiro Goto<sup>1</sup>, Yoshihiro Tsuruo<sup>2</sup>, and Koichi Sairyo<sup>1</sup>

<sup>1</sup>Department of Orthopedics, Institute of Biomedical Science, Tokushima University Graduate School, Tokushima, Japan, <sup>2</sup>Department of Anatomy, Institute of Biomedical Science, Tokushima University Graduate School, Tokushima, Japan

**Abstract :** The aim of this cadaveric study was to evaluate the intraoperative kinematics of the native knee including two-dimensional translation of the femur using a navigation system. Eight native knees of 4 fresh-frozen whole-body cadavers were used for the study. The kinematics of each knee were analyzed intraoperatively using the navigation system. Although anterior-posterior translation could not be assessed directly, it could be calculated using a formula derived from the parameters in the navigation system. The native knee showed external rotation of the femur in early knee flexion, transient internal rotation in mid flexion, and gradual external rotation in late flexion. There was no marked change in the coronal rotation angle of the mechanical axis during knee flexion. The femoral center moved anteriorly in early knee flexion and posteriorly in late flexion. The distance moved in the medial-lateral direction was relatively smaller than that in the anterior-posterior direction. Two-dimensional translation of the surgical epicondylar axis showed a medial pivot-like motion. In this cadaveric study, the kinematics of the native knee, including two-dimensional translation of the femur, could be satisfactorily assessed intraoperatively using a navigation system. The intraoperative kinematics of the knee can be analyzed in more detail using this methodology. *J. Med. Invest.* 66:367-371, August, 2019

**Keywords :** knee kinematics, navigation system, cadaveric study

## INTRODUCTION

Total knee arthroplasty (TKA) is now one of the most common and successful orthopedic interventions for osteoarthritis of the knee. There has been an increasing amount of research on TKA, and its outcomes have improved year by year (1, 2). Recent technological innovations have led to the development of many computer-assisted surgical procedures, including those that include use of a navigation system (3). Using a navigation system, TKA procedures can now be performed more accurately with better reproducibility (4, 5).

Several studies have focused on the kinematics of the knee after TKA (6, 7). With increasingly widespread use of navigation systems, the kinematics of the knee have been evaluated in more detail (8, 9). However, some reports have claimed that anterior-posterior translation of the femur cannot be assessed directly using a navigation system, citing this problem as a limitation of navigation technology (10, 11). The kinematics of the knee, in particular antero-posterior translation of the femur against the tibia, have been identified as one of the most important parameters to assess after knee surgery (12). Furthermore, assessment of anterior-posterior translation of the femur enables to evaluate two-dimensional translation of the femur in combination with parameters of medial-lateral translation and axial rotation which can be assessed using a navigation system. Therefore, we attempted to evaluate anterior-posterior translation from the

parameters obtained by the navigation system.

The aim of this cadaveric study was to evaluate the intraoperative kinematics of the native knee including two-dimensional translation of the femur using a navigation system.

## MATERIAL AND METHODS

The study protocol was approved by the institutional review board at our hospital. Eight knees of four fresh-frozen whole-body cadavers were used. The cadavers (2 male, 2 female; mean age 80.5 [range, 74–93] years at the time of death) were stored at  $-20^{\circ}\text{C}$ . All the cadaveric knee specimens were macroscopically intact without gross deformity, arthritic change, contracture, or evidence of prior knee surgery. Preoperative computed tomography confirmed that none of the knees had osteoarthritis. Anterior-posterior and varus-valgus stability was confirmed manually. No specimen had macroscopic evidence of damage to or degeneration of the ligaments.

All the cadaveric knees were dissected via a midline incision and medial parapatellar arthrotomy. An image-free knee navigation system (Stryker Navigation version 1.0, Kalamazoo, MI) with infrared cameras and light-emitting diodes was set up in each knee. This system is image-free; therefore, no preoperative computed tomography examination or fluoroscopy is needed. During registration, surgeons need to digitize the positions of anatomic landmarks and axes using navigation instruments to establish the reference for alignment. The femoral rotational axis is set perpendicular to the surgical epicondylar axis (SEA) and the tibial rotational alignment is directed along the line from the medial border of the tibial tubercle to the middle of the posterior cruciate ligament (13). The hip center is detected automatically by slow circumduction of the hip while changing

Received for publication May 13, 2019; accepted July 3, 2019.

Address correspondence and reprint requests to Keizo Wada Department of Orthopedics, Institute of Biomedical Sciences, Tokushima University Graduate School, 3-18-15 Kuramoto, Tokushima 770-8503, Japan and Fax : +81-088-633-0178.

the radius. After registration, the relationship between the femur and tibia is visualized on the monitor (Figure 1). Both the axial rotation (internal-external) angle and the coronal rotation (varus-valgus) angle, as well as the sagittal rotation (knee flexion) angle, are displayed on the navigation system. The distance between the femoral center and tibial center is also displayed in the anterior-posterior, medial-lateral, and compression-distraction directions. All parameters are expressed with reference to the femoral center.

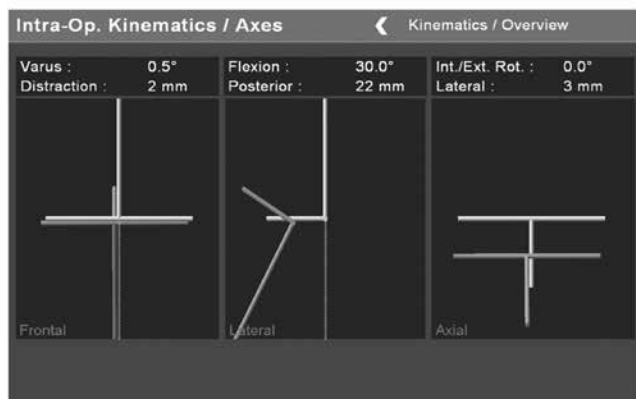


Figure 1 : Appearance of the navigation monitor. The relationship between the femur and tibia is visualized.

The dissected fascia was sutured with nylon during evaluation of the kinematics in each specimen. Kinematic analysis was performed once for each knee by the same examiner using the navigation system. The knee was flexed by placing the heel of the specimen in the examiner’s open palm to allow the tibia to rotate freely while the examiner’s other hand was placed beside the knee of the specimen for support. Care was taken to avoid intentional rotation of the knee throughout flexion. All parameters were automatically recorded by the navigation system at 10° intervals from 0° to 120° of passive knee flexion. All parameters at a knee flexion of 0° were set at 0 to limit variation in the registration for each knee. The data were collected with a measurement accuracy of 0.5° or 1 mm, and the results are reported to one decimal place. Although a previous study had confirmed that this procedure has acceptable reproducibility, we performed a preliminary study using another three cadaveric whole-body specimens to analyze the reproducibility of the rotational kinematics. The intra-class coefficient was 0.89, indicating almost perfect intra-examiner reproducibility.

To explain the translation of the femur, parameters other than the varus-valgus angle and knee flexion angle must also be calculated and expressed with reference to the tibial center. Both the internal-external angle and medial-lateral distance should be reversed. A formula based on the parameters obtained from the navigation system was derived to calculate the anterior-posterior distance. Using this formula, the anterior-posterior location of the femoral center relative to the tibial center can be calculated (Figure 2). In the present study, the femoral axis was set perpendicular to the SEA during registration ; therefore, the internal-external angle of the femoral axis could be used as the rotation angle of the SEA. A scatterplot was created using the parameters of medial-lateral distance and anterior-posterior distance, and the line of the SEA at each knee flexion angle was added on the femoral center to visualize two-dimensional translation. The length of the SEA was measured on computed tomography scans acquired preoperatively, and the femoral center was assumed to be at the middle point of the SEA.

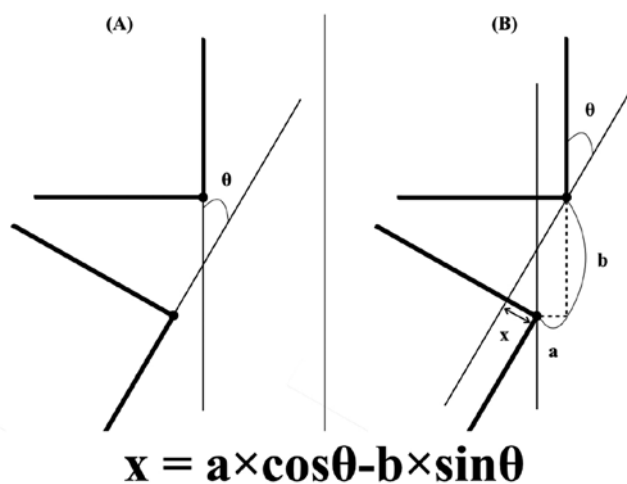


Figure 2 : Schema of the navigation monitor and the formula used to calculate the anterior-posterior distance of the femoral center relative to the tibial center (the anterior distance being a positive value) based on the parameters obtained from the navigation system (the letter “x”). θ, knee flexion angle ; a, anterior-posterior distance of the tibial center relative to the femoral center (the posterior distance being a positive value) ; b, distraction-compression distance of the tibial center relative to the femoral center (the distraction distance being a positive value).

RESULTS

The native knee showed external rotation of the femur in early knee flexion, slight internal rotation in mid-flexion, and gradual external rotation in late flexion (Figure 3). There was no marked change in the coronal rotation angle of the mechanical axis during knee flexion (Figure 4).

The center of the articular surface of the femur moved anteriorly in early knee flexion and posteriorly in late flexion (Figure 5). The distance moved in the medial-lateral direction was smaller than that in the anterior-posterior direction (Figure 6).

The SEA had a mean length of 77.7 (range, 70–85) mm. The two-dimensional translation of the femoral center relative to the tibial center with the SEA is shown in Figure 7.

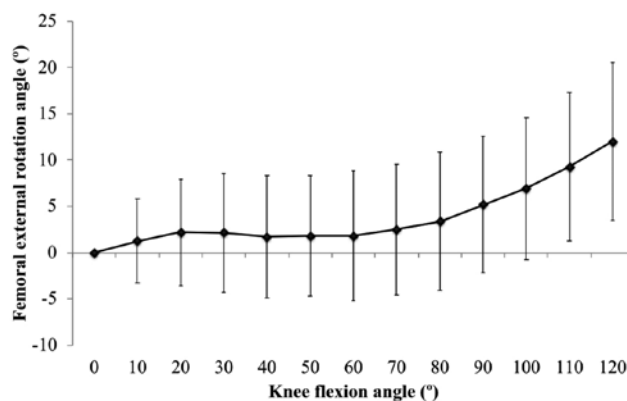


Figure 3 : External rotation angles of the femur during knee flexion.

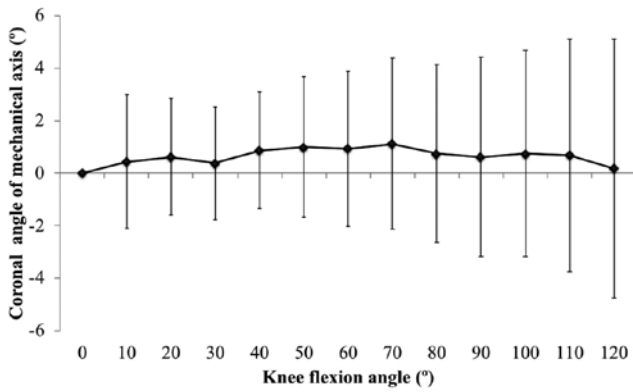


Figure 4 : Coronal angles of the mechanical axis during knee flexion.

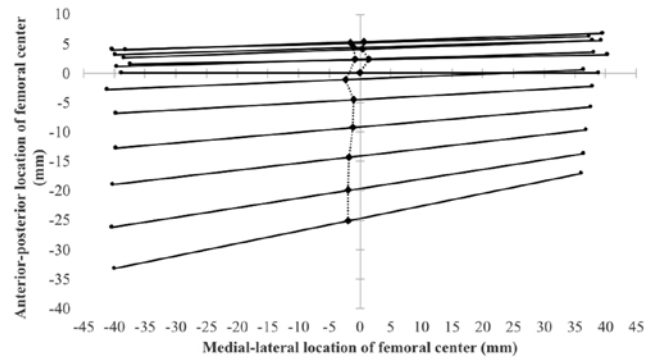


Figure 7 : Two-dimensional translation of the femoral center relative to the tibial center. The black lines indicate the surgical epicondylar axis at each knee flexion angle, and the femoral center was assumed to be at the middle point of the surgical epicondyle axis.

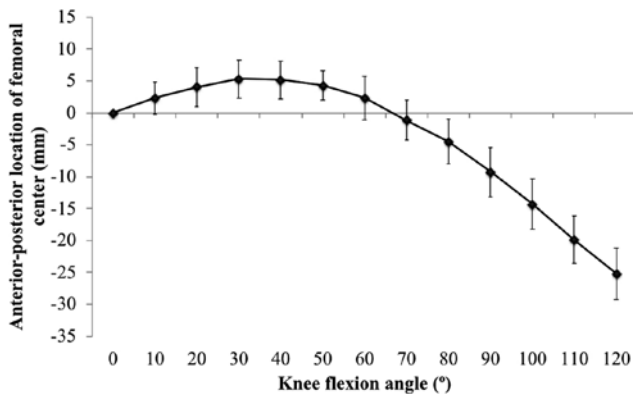


Figure 5 : Anterior-posterior translation of the femoral center relative to the tibial center.

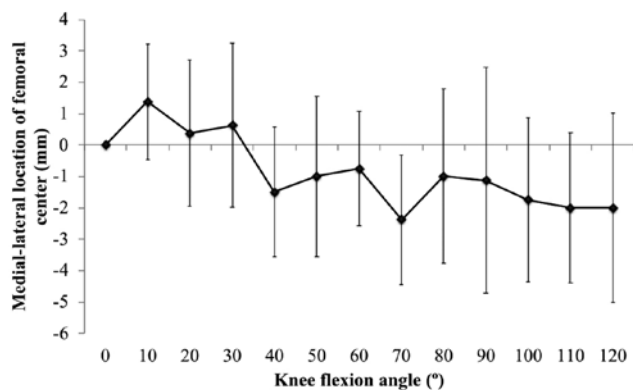


Figure 6 : Medial-lateral translation of the femoral center relative to the tibial center.

### DISCUSSION

The most important finding of the present study was that intraoperative kinematic analysis using an image-free navigation system can clarify the kinematics of the native knee, including two-dimensional translation of the femur during knee flexion. Two-dimensional translation of the femoral center with the SEA was also visualized using the parameters collected by the navigation system. Therefore, the methodology described here is useful for understanding the kinematics of the knee in detail.

Despite favorable long-term implant survival after TKA, patient-reported outcomes do not indicate satisfaction levels comparable with those reported after total hip arthroplasty (14). This dissatisfaction could be explained partly by changes in the kinematics of the knee after TKA (15); therefore, research attention has been focused on these changes. An image-matching technique has been used in previous studies for postoperative kinematic analysis in vivo (16-18). The advantage of the technique is that it can analyze the kinematics of the knee under active weight-bearing conditions. In contrast, the advantage of intraoperative kinematic analysis using a navigation system is that it relies on accurate positioning of the total knee components. Although intraoperative kinematic analysis is performed under passive non-weight-bearing conditions, a previous report indicated a correlation between passive intraoperative analysis and active postoperative kinematics (19). Furthermore, the only opportunity for adjustment of the kinematics of the knee is during surgery. Therefore, a more detailed intraoperative kinematic analysis should be important. In another study, it was demonstrated that intraoperative external femoral rotation with a medial pivot motion, which is one of the kinematic features of the native knee, correlated with the postoperative deep knee flexion angle and patient satisfaction (20). Given those findings, restoration of the kinematics of the native knee might lead to better clinical outcomes after TKA.

The kinematics of the native knee have been widely investigated (21). Previous studies have reported several features of axial rotation in the native knee. Sharp external rotation of the femur near extension has been identified and is known as the “screw-home” movement (22). Bicondylar rollback has also been found to occur at mid-flexion during various activities, and a medial pivot motion has been identified during deep knee bends (23, 24). Our present findings indicate that external rotation of the femur occurs in the early stage of knee flexion and that slight internal rotation of the tibia occurs between 60° and maximum flexion

of the knee. In terms of anterior-posterior translation, we found that the femoral center moved posteriorly in the later phase of knee flexion, potentially indicating femoral rollback. Our present results suggest that the medial side of the SEA moves less than the lateral side on two-dimensional translation, indicating a medial pivot-like motion. Furthermore, these kinematic data for passive motion of native cadaveric knees are similar to those in a previous study of the in vivo kinematics of native knees in living subjects by Murakami *et al.* (23). This similarity may be reflect the use of whole-body cadaveric specimens in the present study. More detailed cadaveric studies using the method described here are needed in order to restore the kinematics of the native knee after TKA.

This study has several limitations. First, the methodology described here cannot assess the contact point of the femorotibial joint. It should be noted that two-dimensional translation was only assessed by movement of the femoral center. Therefore, our results using the present methodology should be considered carefully and compared with the results obtained using other methods. For the same reason, articular surface contact using this method, such as lift-off, cannot be analyzed. Therefore, further studies using a contact force sensing device are needed to assess the articular surface contact. Secondly, the method described here may not be applicable to all navigation systems. The characteristics of navigation systems are variable. Therefore, it is necessary to understand the registration method of the navigation system well for application to analysis. Third, the reproducibility of the kinematic analysis was not evaluated, except for the rotational kinematics; however, this may be questionable because the analysis was performed manually. Nevertheless, in a previous study, Wada *et al.* demonstrated that intraoperative analysis of kinematics was highly reproducible (9). Therefore, we believe that our present data, which were obtained using the same method, have acceptable reproducibility. Despite these limitations, the present methodology enabled surgeons to assess knee kinematics intraoperatively in more detail.

In conclusion, in this cadaveric study, the kinematics of the native knee, including two-dimensional translation of the femur, was satisfactory assessed by intraoperative kinematic analysis using a navigation system. Surgeons should be aware that the intraoperative kinematic analysis can be conducted in more detail using the methodology described in this paper.

## CONFLICT OF INTERESTS

All authors declare that they have no conflicts of interest.

## ACKNOWLEDGEMENTS

The authors wish to acknowledge Dr. Hiroshi Mikami, Vice-President of Yoshinogawa Medical Center, for technical assistance with the navigation system experiments.

## REFERENCES

1. Jauregui JJ, Cherian JJ, Pierce TP, Beaver WB, Issa K, Mont MA : Long-term survivorship and clinical outcomes following total knee arthroplasty. *J Arthroplasty* 30 : 2164-2166, 2015.
2. De Martino I, D'Apolito R, Sculco PK, Poultsides LA, Gasparini G : Total knee arthroplasty using cementless porous tantalum monoblock tibial component : A minimum 10-year follow-up. *J Arthroplasty* 31 : 2193-2198, 2016.
3. Ueyama H, Minoda Y, Sugama R, Ohta Y, Yamamura K, Nakamura S, Takemura S, Nakamura H : An accelerometer-based portable navigation system improved prosthetic alignment after total knee arthroplasty in 3D measurements. *Knee Surg Sports Traumatol Arthrosc* 2018. doi : 10.1007/s00167-018-5082-4. [Epub ahead of print].
4. Casper M, Mitra R, Khare R, Jaramaz B, Hamlin B, McGinley B, Mayman D, Headrick J, Urish K, Gittins M, Incavo S, Neginhal V : Accuracy assessment of a novel image-free handheld robot for total knee arthroplasty in a cadaveric study. *Comput Assist Surg (Abingdon)* 23 : 14-20, 2018.
5. Sasaki H, Ishida K, Shibanuma N, Takayama K, Hayashi S, Hashimoto S, Niikura T, Kurosaka M, Kuroda R, Matsumoto T : Comparison of coronal prosthetic alignment after total knee arthroplasty using 3 computer-assisted navigation systems. *Orthopedics* 41 : e621-e628, 2018.
6. Fritzsche H, Beyer F, Postler A, Lutzner J : Different intraoperative kinematics, stability, and range of motion between cruciate-substituting ultracongruent and posterior-stabilized total knee arthroplasty. *Knee Surg Sports Traumatol Arthrosc* 26 : 1465-1470, 2018.
7. Kang KT, Koh YG, Son J, Kwon OR, Lee JS, Kwon SK : Comparison of kinematics in cruciate retaining and posterior stabilized for fixed and rotating platform mobile-bearing total knee arthroplasty with respect to different posterior tibial slope. *Biomed Res Int* 2018 : 5139074, 2018.
8. Maderbacher G, Keshmiri A, Springorum HR, Maderbacher H, Grifka J, Baier C : Reproducibility of navigation based kinematic analysis of the knee - A cadaveric investigation. *J Orthop Sci* 24 : 128-135, 2019.
9. Wada K, Mikami H, Hamada D, Yonezu H, Oba K, Sairyō K : Measurement of rotational and coronal alignment in total knee arthroplasty using a navigation system is reproducible. *Arch Orthop Trauma Surg* 136 : 271-276, 2016.
10. Wada K, Hamada D, Tamaki S, Higashino K, Fukui Y, Sairyō K : Influence of medial collateral ligament release for internal rotation of tibia in posterior-stabilized total knee arthroplasty : A cadaveric study. *J Arthroplasty* 32 : 270-273, 2017.
11. Wada K, Hamada D, Takasago T, Nitta A, Goto T, Tonogai I, Tsuruo Y, Sairyō K : The medial constrained insert restores native knee rotational kinematics after bicruciate-retaining total knee arthroplasty. *Knee Surg Sports Traumatol Arthrosc* 2018. doi : 10.1007/s00167-018-5249-z. [Epub ahead of print].
12. Mine T, Hoshi K, Gamada K, Ihara K, Kawamura H, Kuriyama R, Date R : Kinematic analysis of posterior-stabilized total knee arthroplasty during standing up from and sitting down on a chair. *J Orthop Surg Res* 11 : 142, 2016.
13. Akagi M, Mori S, Nishimura S, Nishimura A, Asano T, Hamanishi C : Variability of extraarticular tibial rotation references for total knee arthroplasty. *Clin Orthop Relat Res* (436) : 172-176, 2017.
14. Bourne RB, Chesworth B, Davis A, Mahomed N, Charron K : Comparing patient outcomes after THA and TKA : is there a difference? *Clin Orthop Relat Res* 468 : 542-546, 2010.
15. Bull AM, Kessler O, Alam M, Amis AA : Changes in knee kinematics reflect the articular geometry after arthroplasty. *Clin Orthop Relat Res* 466 : 2491-2499, 2008.
16. Tamaki M, Tomita T, Watanabe T, Yamazaki T, Yoshikawa H, Sugamoto K : In vivo kinematic analysis of a high-flexion, posterior-stabilized, mobile-bearing knee prosthesis in deep knee bending motion. *J Arthroplasty* 24 : 972-978,

- 2009.
17. Suzuki K, Hara N, Mikami S, Tomita T, Iwamoto K, Yamazaki T, Sugamoto K, Matsuno S : In vivo kinematic analysis of posterior-stabilized total knee arthroplasty for the valgus knee operated by the gap-balancing technique. *Knee* 21 : 1124-1128, 2014.
  18. Horiuchi H, Akizuki S, Tomita T, Sugamoto K, Yamazaki T, Shimizu N : In vivo kinematic analysis of cruciate-retaining total knee arthroplasty during weight-bearing and non-weight-bearing deep knee bending. *J Arthroplasty* 27 : 1196-1202, 2012.
  19. Wada K, Mikami H, Hamada D, Yamazaki T, Tomita T, Sairyo K : Can intraoperative kinematic analysis predict postoperative kinematics following total knee arthroplasty? A preliminary. *J Med Invest* 65 : 21-26, 2017.
  20. Nishio Y, Onodera T, Kasahara Y, Takahashi D, Iwasaki N, Majima T : Intraoperative medial pivot affects deep knee flexion angle and patient-reported outcomes after total knee arthroplasty. *J Arthroplasty* 29 : 702-706, 2014.
  21. Hamai S, Moro-oka TA, Dunbar NJ, Miura H, Iwamoto Y, Banks SA : In vivo healthy knee kinematics during dynamic full flexion. *Biomed Res Int* 2013 : 717546, 2013.
  22. Moglo KE, Shirazi-Adl A : Cruciate coupling and screw-home mechanism in passive knee joint during extension-flexion. *J Biomech* 38 : 1075-1083, 2005.
  23. Murakami K, Hamai S, Okazaki K, Ikebe S, Shimoto T, Hara D, Mizu-uchi H, Higaki H, Iwamoto Y : In vivo kinematics of healthy male knees during squat and golf swing using image-matching techniques. *Knee* 23 : 221-226, 2016.
  24. Nakagawa S, Kadoya Y, Todo S, Kobayashi A, Sakamoto H, Freeman MA, Yamano Y : Tibiofemoral movement 3 : full flexion in the living knee studied by MRI. *J Bone Joint Surg Br* 82 : 1199-1200, 2000.