

OTHERS

A novel three-dimensional classification system for intertrochanteric fractures based on computed tomography findings

Keizo Wada^a, Hiroshi Mikami^b, Rui Amari^a, Shunichi Toki^a, Michihiro Takai^b, and Koichi Sairyo^a

^aDepartment of Orthopedics, Institute of Biomedical Science, Tokushima University Graduate School, Tokushima, Japan

^bDepartment of Orthopaedic Surgery, Yoshinogawa Medical Center, Tokushima, Japan

Abstract : A novel three-dimensional fragment-based classification system based on computed tomography findings was established to characterize femoral intertrochanteric fractures. The intertrochanteric bone fragments were defined as follows: neck, posterior portion of the greater trochanter, anterior portion of the greater trochanter, lesser trochanter, and shaft. Each type of fracture was classified as 2-, 3-, 4-, or 5-fragment according to the number of floating bone fragments. Following the description of the fracture type, each floating bone fragment was appended, with the exception of a fragment involving the shaft. Ninety-five intertrochanteric fractures were classified by the same surgeon. The fractures occurred in 14 men and 81 women with a mean age of 84.7 years. The frequency of each type of fracture was investigated. Thirty-one fractures (32.6%) were 2-fragment and 64 (67.4%) were ≥ 3 -fragment. A fragment of the anterior portion of the greater trochanter, which cannot be classified using conventional systems, was included in 29 cases (30.5%). A 5-fragment fracture was detected in two cases (2.1%). Using this fragment-based classification system, intertrochanteric fractures can be evaluated in more detail than is possible using conventional classification systems. *J. Med. Invest.* 66:362-366, August, 2019

Keywords : intertrochanteric fracture, computed tomography, classification

INTRODUCTION

The number of intertrochanteric fractures in the elderly population has been increasing worldwide because of increasing life expectancy (1). Osteosynthesis has been widely used for intertrochanteric fractures (2). However, it is not always possible for elderly patients with unstable fractures to have good outcomes after osteosynthesis (3, 4). To address this problem, both improvement of surgical technique and advances in implant technology have been promoted (5-9). Therefore, intertrochanteric fractures need to be classified accurately to determine the most appropriate treatment method.

The Evans (10), Jensen (11), and AO/OTA (12) systems for classifying femoral intertrochanteric fractures are based on findings on two-dimensional plain radiographic images and are commonly used. There are some recent reports of computed tomography (CT) being used by surgeons to evaluate the fragments in comminuted intertrochanteric fractures in more detail. However, even with CT, the reliability was not satisfactory based on the two-dimensional classification in a previous report (13). Their results indicated that two-dimensional classification systems were not appropriate for evaluating intertrochanteric fractures on CT scans. In other words, a three-dimensional classification system would be needed to define the fragments that could not be classified by two-dimensional classifications. Therefore, our group has established a novel three-dimensional CT classification system for intertrochanteric fractures, called the fragment-based classification system.

The aim of this research was to determine the frequency of intertrochanteric fractures in the elderly population using the fragment-based classification system based on CT findings.

MATERIAL AND METHODS

The fragment-based classification system

In our experience, the fracture line of the greater trochanter often runs from the anterosuperior edge of the greater trochanter toward the lesser trochanter. The posterior portion of the greater trochanter is frequently seen as a triangular bone fragment because of the attachment of the gluteus medius and the rotator muscles, including the piriformis. On the other hand, the anterior portion of the greater trochanter is less frequently seen, but is found in double fractures or reverse oblique fractures of the greater trochanter. Therefore, we defined 5 major bone fragments in an intertrochanteric fracture as the neck (N), posterior portion of the greater trochanter (GP), anterior portion of the greater trochanter (GA), lesser trochanter (L), and shaft (S) (Figure 1). Each type of fracture was then classified as 2-, 3-, 4-, or 5-fragment according to the number of floating bone fragments. Following the description of the fracture type, each floating bone fragment was appended, with the exception of a fragment involving the shaft, with the symbol “/” between the fragments. The fracture fragment complex was marked by including the fragments that comprised it with the symbol “+” between the fragments. In cases involving 3 or more fragments, the description of the simple N fragment was omitted. A fracture with only one N fragment was described as 2-fragment (N) (Figure 2). A fracture that had an N fragment and a complex of GP and L fragments was classified as 3-fragment (GP+L) (Figure 3). If a floating N, GA, and a complex of GP and L fragments were present, the fracture was classified as 4-fragment (GP+L/GA) (Figure 4). If there were 5 floating fragments, the fracture was

Received for publication February 14, 2019; accepted May 5, 2019.

Address correspondence and reprint requests to Keizo Wada, Department of Orthopedics, Institute of Biomedical Sciences, Tokushima University Graduate School, 3-18-15 Kuramoto, Tokushima 770-8503, Japan and Fax: +81-088-633-0178.

then classified as 5-fragment (Figure 5).

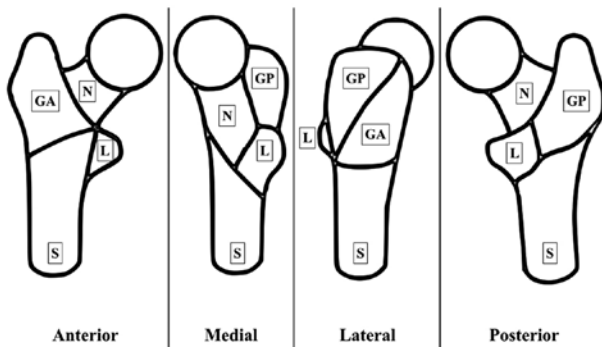
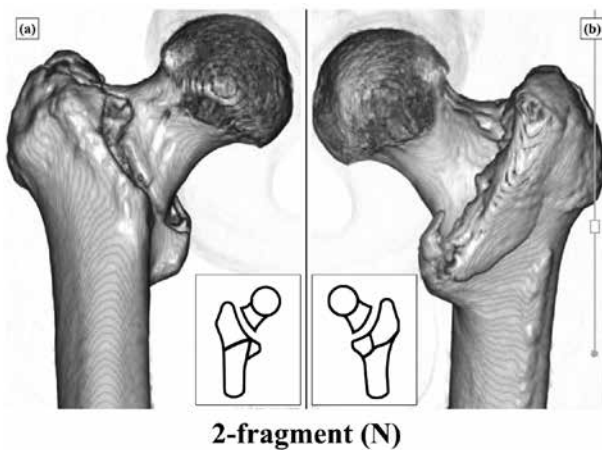


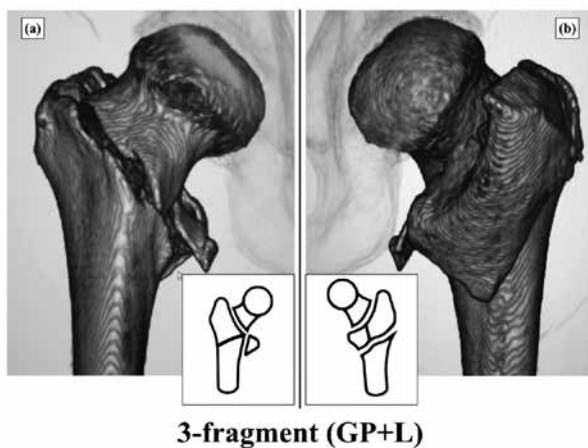
Figure 1 Schematic diagram showing the fragment-based classification.

GA, anterior portion of the greater trochanter ; GP, posterior portion of the greater trochanter ; L, lesser trochanter ; N, neck ; S, shaft



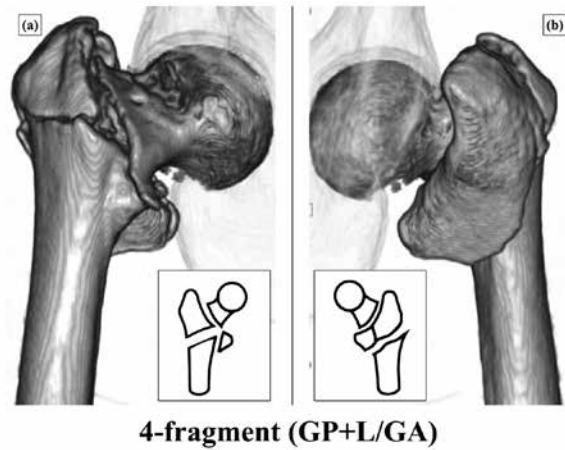
2-fragment (N)

Figure 2 Appearance of the 2-fragment (N) fracture on three-dimensional reconstruction computed tomography and a schematic image of this fracture. (a) Anterior view. (b) Posterior view.



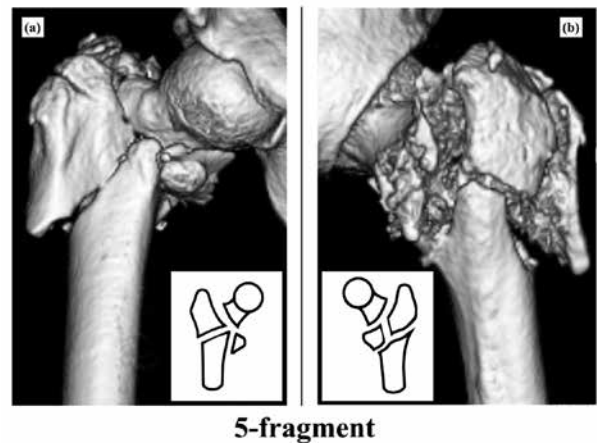
3-fragment (GP+L)

Figure 3 Appearance of the 3-fragment (GP+L) fracture on three-dimensional reconstruction computed tomography and a schematic image of this fracture. (a) Anterior view. (b) Posterior view.



4-fragment (GP+L/GA)

Figure 4 Appearance of the 4-fragment (GP+L/GA) fracture on three-dimensional reconstruction computed tomography and a schematic image of this fracture. (a) Anterior view. (b) Posterior view.



5-fragment

Figure 5 Appearance of the 5-fragment fracture on three-dimensional reconstruction computed tomography and a schematic image of this fracture. (a) Anterior view. (b) Posterior view.

The study was approved by our institutional review board. Ninety-five patients (14 male, 81 female ; mean age 84.7 [range, 54–99] years) admitted to our hospital with an intertrochanteric fracture were reviewed retrospectively. CT was performed in all cases for diagnostic purposes. The CT procedure was performed in the supine position using a high-speed scanner (multi-director CT ; Aquilion CX edition, Toshiba Medical Systems Co., Ltd., Tokyo, Japan). Three-dimensional reconstruction was performed using images with 1-mm slice thickness on an Aquarius Net Viewer workstation (TeraRecon Inc., San Mateo, CA). The fragment-based classification system was used to evaluate the intertrochanteric fractures. All evaluations were performed by the same surgeon (RA). The frequency of each type of fracture was determined.

The Mann-Whitney *U* test was used to evaluate differences in age between patients with 2-fragment fractures and those with ≥ 3 -fragment fractures. A *P*-value < 0.05 was considered statistically significant. All statistical analyses were performed using SPSS software (version 25 for Mac OS X ; IBM Corp., Armonk, NY).

RESULTS

Various combinations of the 5 fragments are possible but only 9 types of fracture were observed in the present series (Table 1).

Table 1 Frequency of each type of fracture detected by the fragment-based classification system

Classification	Cases, n	(%)
2-fragment		
(N)	10	10.5
(N+GA)	21	22.1
3-fragment		
(N+GP/L)	9	9.5
(GP)	24	25.3
(GP+GA)	5	5.3
(GP+L)	5	5.3
4-fragment		
(GP/L)	18	18.9
(GP+L/GA)	1	1.1
5-fragment		
	2	2.1

N, neck; GP, posterior portion of the greater trochanter; GA, anterior portion of the greater trochanter; L, lesser trochanter

Thirty-one patients (32.6%; 3 male, 28 female; mean age 82.8 [range, 54–98] years) had 2-fragment fractures and 64 (67.4%; 11 male, 53 female; mean age 82.8 [range, 68–99] years) had ≥ 3 -fragment fractures. There was no statistically significant difference in age between the patients with 2-fragment fractures and those with ≥ 3 -fragment fractures ($p = 0.509$).

The most common type of fracture was 3-fragment (GP) followed by 2-fragment (N+GA). Two patients (2.1%) had a 5-fragment fracture. Sixty-four (67.4%) of the 95 patients had intertrochanteric fractures that included a GP or GA fragment. A GA fragment fracture was included in 29 cases (30.5%).

DISCUSSION

The most important finding in this study is that the GA fragment, which cannot be classified by conventional intertrochanteric fracture classification systems, was detected in 30.5% of cases in the present series using the fragment-based classification system based on CT. Using this novel system, the greater trochanter fragments could be evaluated in detail. To our knowledge, this is the first study to investigate the fragment-based classification system. A 5-fragment fracture was diagnosed in two cases using this system.

Intertrochanteric fragility fractures are common in the elderly population and are becoming increasingly frequent with continued aging of populations worldwide (14). Intertrochanteric fractures are usually treated by osteosynthesis, which includes intramedullary and extramedullary fixation (2, 15). However, elderly individuals have poor bone quality, so intertrochanteric fractures in the elderly are likely to be unstable. Helin *et al.* reported that intramedullary nailing provides poorer stabilization of unstable fractures compared to stable fractures (16). In some previous reports, relatively high complication rates were noted in patients with unstable intertrochanteric fractures (3, 17). From the viewpoint of treatment methods, Chun *et al.* introduced

a unique reduction technique using a 4.2-mm Steinmann pin for unstable intertrochanteric fractures (18). Regarding implants, Sanders *et al.* compared outcomes in elderly patients with intertrochanteric hip fractures treated with either the sliding hip screw or the intramedullary device, and concluded that the intramedullary device better improved outcome in active, functioning patients with unstable intertrochanteric fracture than the sliding hip screw (6). Irgit *et al.* reported that long intramedullary nails remain the preferred option for the treatment of reverse oblique and transverse fractures, demonstrating acceptable complication rates, low reoperation rates, and high rates of healing (19). Furthermore, a recent report by Wada *et al.* suggested that hemiarthroplasty is a good surgical option for very elderly patients with unstable intertrochanteric fractures (9). Therefore, the importance of identifying the type of intertrochanteric fracture is necessary to decide the optimal treatment method.

To evaluate fracture type, CT can provide detailed information about the fracture pattern. According to Cho *et al.*, there is a high incidence of coronal fragments in intertrochanteric fractures when analyzed with three-dimensional CT reconstructions (20). Ishida *et al.* compared plain radiography and CT findings of intertrochanteric fractures to intraoperative findings, and reported that plain radiograph assessment underestimates posterior comminution and the complexity of the fracture line (21). They also stated that coronal fragments are very difficult to recognize on plain radiographs. The present series also included a high frequency of intertrochanteric fractures with ≥ 3 fragments. The lack of a statistically significant difference in age between patients with 2-fragment fractures and those with ≥ 3 -fragment fractures could reflect the fact that the mean age of our patients was relatively high. Therefore, detailed evaluation of greater trochanter fragments could be important, particularly in elderly patients. However, Chapman *et al.* used a combination of CT scans and plain radiographs to evaluate intertrochanteric fractures using the two-dimensional Evans-Jensen and AO/OTA classification systems and concluded that there was no marked change in interobserver agreement when information from CT scans was added (13). Their results suggested that two-dimensional classification systems were not appropriate when evaluating intertrochanteric fractures on CT scans. Based on their results, a three-dimensional classification system using CT images would be needed for the fragments that could not be classified by two-dimensional classifications.

Some previous studies introduced the concept of three-dimensional classification of intertrochanteric fractures. Nakano *et al.* (22) and Shoda *et al.* (23) proposed a three-dimensional CT classification that defined an intertrochanteric fracture as that containing 4 major fragments and evaluated each greater trochanter fragment by its size. However, in the present study, 30.5% of fractures ($n = 29$) included the GA fragment, suggesting that intertrochanteric fractures can be classified more accurately by dividing the fracture into 5 fragments. This is the basis of the fragment-based classification system, which seems to be superior to conventional classification systems. On the other hand, Futamura *et al.* introduced a new three-dimensional classification focusing on AO/OTA classification 31-A3 fractures (24). In a subgroup of their classification, the shape of the posterior fragment was used to characterize the fractures. In the present fragment-based classification, as in their study, the shape of both anterior and posterior fragments can be characterized by a combination of the 5 fragments. Therefore, all types of intertrochanteric fractures can be simply classified using the fragment-based classification system and can be easily shared.

This study has several limitations. First, the type of fracture was evaluated by only one surgeon. Although CT scans enabled

accurate evaluation of intertrochanteric fractures, consideration of both interobserver and intraobserver reliability is important for a robust fracture classification system. Moreover, previous reports suggest that reliability tends to decrease as a classification system becomes more detailed (25, 26). Further study of the reliability of the fragment-based classification system is needed to address this limitation. Second, we did not perform a biomechanical evaluation. Therefore, it is difficult to discuss the fragment-based classification in terms of stable and unstable fractures because this structure-based classification system explains fractures in terms of only each bone fragment combination. Do *et al.* performed a biomechanical study to evaluate the effect of fracture geometry on the stability of 3-part intertrochanteric fractures by assessing the fragment size (27). Based on their results, fractures which comprise both GP and GA fragments under the fragment-based classification might be more unstable due to loss of both anterior and posterior structure of the greater trochanter. Thus, further biomechanical studies are needed to determine the stability of the fracture. The final limitation is that the study did not include a clinical evaluation of the fragment-based classification system. Tsukada *et al.* investigated comminution at the intertrochanteric fracture site and found that comminution at the anterior cortex may predict cut-out after osteosynthesis (28). Similar clinical studies including the present classification system are necessary. Despite these limitations, we believe that the fragment-based classification system allows surgeons to evaluate intertrochanteric fractures in detail.

In conclusion, we have introduced a novel three-dimensional CT system for classification of intertrochanteric fractures, called the fragment-based classification. Using this classification system, surgeons can evaluate intertrochanteric fractures in more detail than using the conventional two-dimensional classifications.

CONFLICT OF INTERESTS

All authors declare that they have no conflicts of interest.

ACKNOWLEDGEMENTS

This research received no specific grant from any funding agency in the public, commercial, or not-for-profit sectors.

REFERENCES

- Gullberg B, Johnell O, Kanis JA : World-wide projections for hip fracture. *Osteoporos Int* 7(5) : 407-413, 1997
- Yu J, Zhang C, Li L, Kwong JS, Xue L, Zeng X, Tang L, Li Y, Sun X : Internal fixation treatments for intertrochanteric fracture : a systematic review and meta-analysis of randomized evidence. *Sci Rep* 5 : 18195, 2015
- Tan BY, Lau AC, Kwek EB : Morphology and fixation pitfalls of a highly unstable intertrochanteric fracture variant. *J Orthop Surg (Hong Kong)* 23(2) : 142-145, 2015
- Karakus O, Ozdemir G, Karaca S, Cetin M, Saygi B : The relationship between the type of unstable intertrochanteric femur fracture and mobility in the elderly. *J Orthop Surg Res* 13(1) : 207, 2018
- Knobe M, Drescher W, Heussen N, Sellei RM, Pape HC : Is helical blade nailing superior to locked minimally invasive plating in unstable pertrochanteric fractures? *Clin Orthop Relat Res* 470(8) : 2302-2312, 2012
- Sanders D, Bryant D, Tieszer C, Lawendy AR, MacLeod M, Papp S, Liew A, Viskontas D, Coles C, Gurr K, Carey T, Gofton W, Bailey C, Bartley D, Trenholm A, Stone T, Leighton R, Foxall J, Zomar M, Trask K : A Multicenter Randomized Control Trial Comparing a Novel Intramedullary Device (InterTAN) Versus Conventional Treatment (Sliding Hip Screw) of Geriatric Hip Fractures. *J Orthop Trauma* 31(1) : 1-8, 2017
- Kulkarni SG, Babhulkar SS, Kulkarni SM, Kulkarni GS, Kulkarni MS, Patil R : Augmentation of intramedullary nailing in unstable intertrochanteric fractures using cerclage wire and lag screws : a comparative study. *Injury* 48 Suppl 2 : S18-S22, 2017
- Lee YK, Park CH, Koo KH : Fixation of Trochanteric Fragments in Cementless Bipolar Hemiarthroplasty of Unstable Intertrochanteric Fracture : Cerclage Wiring. *Hip Pelvis* 29(4) : 262-269, 2017
- Wada K, Mikami H, Oba K, Yonezu H, Sairyo K : Cementless calcar-replacement stem with integrated greater trochanter plate for unstable intertrochanteric fracture in very elderly patients. *J Orthop Surg (Hong Kong)* 25(1) : 2309499016684749, 2017
- Evans EM : The treatment of trochanteric fractures of the femur. *J Bone Joint Surg Br* 31B(2) : 190-203, 1949
- Jensen JS : Classification of trochanteric fractures. *Acta Orthop Scand* 51(5) : 803-810, 1980
- Marsh JL, Slongo TF, Agel J, Broderick JS, Creevey W, DeCoster TA, Prokuski L, Sirkin MS, Ziran B, Henley B, Audige L : Fracture and dislocation classification compendium - 2007 : Orthopaedic Trauma Association classification, database and outcomes committee. *J Orthop Trauma* 21(10 Suppl) : S1-133, 2007
- Chapman CB, Herrera MF, Binenbaum G, Schweppe M, Staron RB, Feldman F, Rosenwasser MP : Classification of intertrochanteric fractures with computed tomography : a study of intraobserver and interobserver variability and prognostic value. *Am J Orthop (Belle Mead NJ)* 32(9) : 443-449, 2003
- Tsuda T : Epidemiology of fragility fractures and fall prevention in the elderly : a systematic review of the literature. *Curr Orthop Pract* 28(6) : 580-585, 2017
- Shu WB, Zhang XB, Lu HY, Wang HH, Lan GH : Comparison of effects of four treatment methods for unstable intertrochanteric fractures : A network meta-analysis. *Int J Surg* 60 : 173-181, 2018
- Helin M, Pelissier A, Boyer P, Delory T, Estellat C, Massin P : Does the PFNA nail limit impaction in unstable intertrochanteric femoral fracture? A 115 case-control series. *Orthop Traumatol Surg Res* 101(1) : 45-49, 2015
- Johnson B, Stevenson J, Chamma R, Patel A, Rhee SJ, Lever C, Starks I, Roberts PJ : Short-term follow-up of pertrochanteric fractures treated using the proximal femoral locking plate. *J Orthop Trauma* 28(5) : 283-287, 2014
- Chun YS, Oh H, Cho YJ, Rhyu KH : Technique and early results of percutaneous reduction of sagittally unstable intertrochanteric fractures. *Clin Orthop Surg* 3(3) : 217-224, 2011
- Irgit K, Richard RD, Beebe MJ, Bowen TR, Kubiak E, Horwitz DS : Reverse Oblique and Transverse Intertrochanteric Femoral Fractures Treated With the Long Cephalomedullary Nail. *J Orthop Trauma* 29(9) : e299-304, 2015
- Cho JW, Kent WT, Yoon YC, Kim Y, Kim H, Jha A, Durai SK, Oh JK : Fracture morphology of AO/OTA 31-A trochanteric fractures : A 3D CT study with an emphasis on coronal fragments. *Injury* 48(2) : 277-284, 2017
- Isida R, Bariatsky V, Kern G, Dereudre G, Demondion X,

- Chantelot C : Prospective study of the reproducibility of X-rays and CT scans for assessing trochanteric fracture comminution in the elderly : a series of 110 cases. *Eur J Orthop Surg Traumatol* 25(7) : 1165-1170, 2015
22. Nakano T : Proximal femoral fracture. *Seikeigeka (Orthopaedics)* 65 : 842-850, 2014
 23. Shoda E, Kitada S, Sasaki Y, Hirase H, Niikura T, Lee SY, Sakurai A, Oe K, Sasaki T : Proposal of new classification of femoral trochanteric fracture by three-dimensional computed tomography and relationship to usual plain X-ray classification. *J Orthop Surg (Hong Kong)* 25(1) : 2309499017692700, 2017
 24. Futamura K, Baba T, Homma Y, Mogami A, Kanda A, Obayashi O, Sato K, Ueda Y, Kurata Y, Tsuji H, Kaneko K : New classification focusing on the relationship between the attachment of the iliofemoral ligament and the course of the fracture line for intertrochanteric fractures. *Injury* 47(8) : 1685-1691, 2016
 25. Schipper IB, Steyerberg EW, Castelein RM, van Vugt AB : Reliability of the AO/ASIF classification for pertrochanteric femoral fractures. *Acta Orthop Scand* 72(1) : 36-41, 2001
 26. Crijs TJ, Janssen SJ, Davis JT, Ring D, Sanchez HB, Science of Variation G : Reliability of the classification of proximal femur fractures : Does clinical experience matter? *Injury* 49(4) : 819-823, 2018
 27. Do JH, Kim YS, Lee SJ, Jo ML, Han SK : Influence of fragment volume on stability of 3-part intertrochanteric fracture of the femur : a biomechanical study. *Eur J Orthop Surg Traumatol* 23(4) : 371-370, 2013
 28. Tsukada S, Wakui M, Yoshizawa H, Miyao M, Honma T : Three-Dimensional Computed Tomographic Analysis for Comminution of Pertrochanteric Femoral Fracture : Comminuted Anterior Cortex as a Predictor of Cutting Out. *Open Orthop J* 10 : 62-70, 2016