

ORIGINAL

A semi-rigid thoracolumbar orthosis fitted immediately after spinal surgery : stabilizing effects and patient satisfaction

Tsuyoshi Goto¹, Toshinori Sakai², Kosuke Sugiura², Hiroyuki Manabe², Fumitake Tezuka², Kazuta Yamashita², Yoichiro Takata², Shinsuke Katoh¹, and Koichi Sairoy²

¹Department of Rehabilitation Medicine, Tokushima University Hospital, Tokushima, Japan

²Department of Orthopedics, Institute of Biomedical Sciences, Tokushima University Graduate School, Tokushima, Japan

Abstract : **Purpose :** To evaluate the stabilizing effects of a Fit Cure-Spine® semi-rigid thoracolumbar orthosis and wearer satisfaction after lumbar surgery. **Methods :** In study 1, the spinal angle, spinal motion angle, and distribution of load were measured in 8 adult male volunteers when the orthosis was worn (1) with no custom-made stay (CMS), (2) with a CMS in the prone position (P-CMS), and (3) with a CMS in the prone position and decreased lordosis (DP-CMS). In study 2, pain scale scores and responses to a questionnaire were recorded in 40 consecutive patients who underwent lumbar spinal surgery in our hospital. **Results :** In study 1, the mean lumbar lordosis when standing was similar to that in the prone position. When the trunk was bent forward, loads on the back support in P-CMS and DP-CMS were concentrated at the center of the CMS, unlike those for No-CMS. In study 2, there was a significant decrease in postoperative wound pain after wearing the Fit Cure-Spine orthosis for 2 weeks. Most patients who wore the orthosis were satisfied with their pain outcome. **Conclusion :** Adjustment to lumbar lordosis and the prone position was restricted in volunteers wearing the Fit Cure-Spine with a CMS. *J. Med. Invest.* 66:275-279, August, 2019

Keywords : Thoracolumbar spine, Orthosis, Low back pain, Range of motion

INTRODUCTION

Low back pain can be caused by many disorders, including intervertebral disc herniation, spondylosis, spinal canal stenosis, spondylolysis, spondylolisthesis, scoliosis, vertebral fracture, infection, and malignancy, all of which warrant treatment. Some patients need surgical intervention, including corrective spinal fusion surgery (1) while others require conservative treatment. Regardless of the treatment provided for patients with these spinal disorders, we often encounter situations where a spinal orthosis is indicated.

Spinal orthosis is used to restrict movement of the spine to control pain and restore function (2,3,4). In clinical practice, it is common to encounter patients requiring prompt external fixation after corrective surgery or following acute vertebral fracture. However, creating a rigid orthosis that fits a particular patient usually takes several days to a week. Corrective spinal fusion surgery is becoming increasingly common. However, in a patient undergoing this procedure, an orthosis molded preoperatively would not fit the trunk postoperatively because of the resulting marked change in posture. Furthermore, patients' general physical status immediately after corrective surgery is generally such that standing with adequate posture for the duration needed for orthosis molding is impossible. Moreover, postoperative surgical wound pain invariably precludes protracted standing, particularly in older patients. Nevertheless, it is well known that early mobilization is crucial to avoid several postoperative complications, including cardiovascular events (5), disuse atrophy (6), urologic dysfunction (7), and deep vein

thrombosis (8).

To resolve this dilemma, we have recently developed a semi-rigid thoracolumbar orthosis that can be fitted immediately after acute postural change, such as that occurring after trauma or spine surgery. The purpose of this study was to assess the effectiveness of this orthosis, its stabilizing effect using two different casts molded as stays for insertion during various trunk movements, and patient satisfaction with use of this orthosis after lumbar spine surgery.

PATICIPANTS AND METHODS

Study 1

Participants

We enrolled 8 healthy male volunteers with mean age 28.8 (range, 22–33) years, mean height 173.3 (range, 163–179) cm, and mean body weight 67.4 (range, 55.4–86.4) kg. None of the subjects had a history of low back pain, musculoskeletal injury, or spinal surgery.

Test material

A cast (splint) is created as a custom-made stay (CMS) fitted to the lumbar lordosis of the individual patient and is usually molded to meet the shape of the patient's back in the prone position. The device can be made available in approximately 10 min. After the cast becomes rigid, it is inserted into the back pocket built into the orthosis. The device is then firmly fixed to the patient's body using Velcro bands. This orthosis was developed by our team and has been available commercially as the Fit Cure-Spine® (Alcare Co., Ltd., Tokyo, Japan) since 2017 (Figure 1).

Three types of orthoses were constructed by inserting different types of CMS into the back pocket of the device so that each subject would wear the orthosis (1) with no CMS (No-CMS), (2) with a 220 mm × 350 mm CMS made of glass fiber molded to the lumbar lordosis in the prone position (P-CMS), and (3) with the

Received for publication December 26, 2018 ; accepted May 8, 2019.

Address correspondence and reprint requests to Toshinori Sakai, MD, PhD, Associate Professor, Department of Orthopedics, Institute of Biomedical Sciences, Tokushima University Graduate School, 3-18-15 Kuramoto-cho, Tokushima 770-8503, Japan and Fax : +81-88-633-0178.

same CMS but with decreased lordosis in the prone position (DP-CMS). The CMS was molded to fit the shape of the volunteer's back in the decreased lordosis condition, which was created by inserting a 10-cm cushion beneath the volunteer's belly in the prone position to reduce lumbar lordosis.

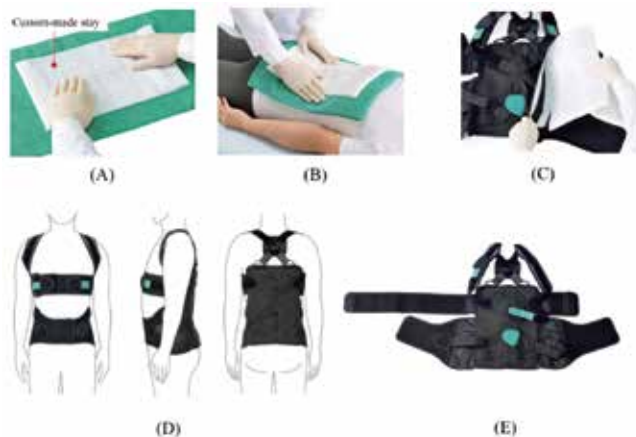

Figure 1. A custom-made stay (A) fitted to the lumbar lordosis of the patient is molded to meet the shape of the patient's back in the prone position (B). After the cast becomes rigid, it is inserted into the back pocket of the orthosis (C). Fixation is secured by fixing the orthosis to the patient's body using Velcro bands (D). This orthosis is available commercially as the Fit Cure-Spine (E).

Measurement of spinal movement while wearing the orthosis

Spinal movements were measured using a SpinalMouse® (Idiag, Volkerswil, Switzerland), which is an electronic computerized device that can measure the sagittal range of motion of the spine and intersegmental angles in a noninvasive manner. The device runs paravertebrally along the spine from the seventh cervical (C7) to the third sacral (S3) vertebrae.

First, lumbar lordosis and thoracic kyphosis in the standing position, in the prone position, and in the prone position with decreased lordosis were compared between the subjects to confirm the best method by which to mold the CMS (Figure 2). Range of motion in the sagittal plane from T1 to S1 in the standing position

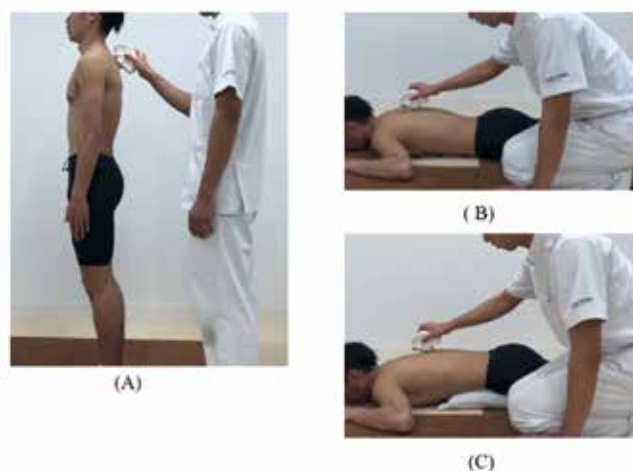


Figure 2. Lumbar lordosis and thoracic kyphosis of each volunteer in the standing (A) and prone (B) positions as well as in the prone position with decreased lordosis (C) were compared to determine the appropriate method of molding the custom-made stay.

was then calculated from the angles obtained on full flexion and extension. Measurements were taken while each subject was wearing the orthosis in the P-CMS and DP-CMS conditions by projecting the contour of the volunteer's back onto a wall and placing marks on the wall (Figure 3). After removal of the orthosis, each volunteer's body was positioned relative to these marks and measurements were taken using the SpinalMouse®.

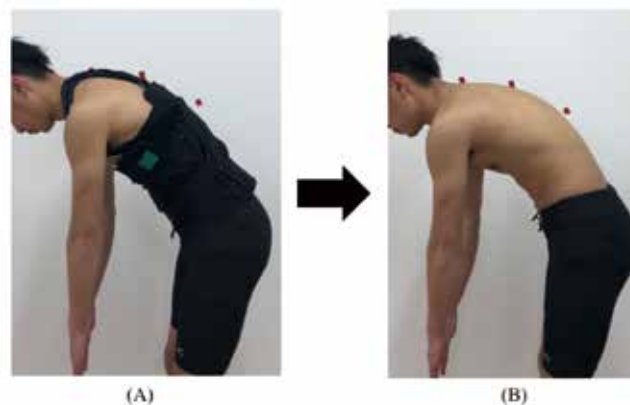


Figure 3. Range of motion in the sagittal plane from T1 to S1 during standing was calculated from the angles measured on full flexion and full extension. Measurements while the subject was wearing the orthosis under the P-CMS and DP-CMS conditions were obtained by projecting the contour of the subject's back onto a wall and placing marks on the wall. After removal of the orthosis, their body was positioned to align with these marks and measured using a SpinalMouse®. CMS, custom-made stay; P-CMS, CMS made of glass fibers fitted to the lumbar lordosis of each subject in the prone position; DP-CMS, CMS fitted in the prone position with decreased lordosis.

Load distribution

Contact pressure exerted by the orthosis on each volunteer's body surface was measured using pressure sensors (AMI Techno Co., Ltd, Tokyo, Japan) on full active flexion/extension of the trunk while standing with the knees fully extended. The back surface of the orthosis was divided into 6×8 (width \times height) 5×5 -cm square grids, and one pressure sensor was placed on each square (Figure 4). The value measured by each sensor was recorded via connected measurement amplifiers and converted to a compressive load (N) value (9).

Study 2

Participants

Study 2 included 40 consecutive patients (19 male, 21 female) of mean age 61 (range 13–84) years who underwent various

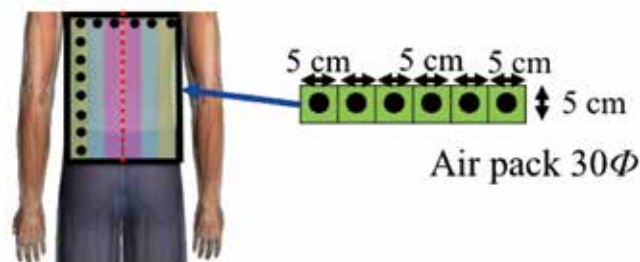


Figure 4. Apparatus used for measurement of load. An airpack placed at the rear of the brace is divided into 6×8 (width \times height) 5×5 -cm square grids, and one pressure sensor is placed on each square.

lumbar surgeries including posterior lumbar interbody fusion, extreme lateral lumbar interbody fusion, and direct repair of a pars defect, at our hospital from October 2015 to March 2016.

Pain scores and satisfaction questionnaire

Visual analogue scale (VAS) pain scores were recorded at rest and during activity immediately following surgery and at 1, 2, and 3 weeks during the postoperative hospital stay. Orthoses was fitted in all patients on the second postoperative day. A questionnaire designed to determine the patients' perceived ease of use, stability, and comfort, as well as time to wear the orthosis and overall satisfaction was administered.

Statistical analyses

Friedman test was used to detect statistically significant differences in measurements obtained at the four assessment points and post hoc Wilcoxon signed-rank test was used to identify statistically significant differences in measurements obtained under the three different wearing conditions. Statistical analyses were performed using SPSS for Windows software (version 22.0; IBM Corp., Armonk, NY). Changes in VAS pain scores were analyzed using repeated-measures analysis of variance with Bonferroni post hoc test. A p-value < 0.05 was considered statistically significant. Homogeneity of variances was assessed using the Shapiro-Wilk normality test. Both studies were approved by the Medical Ethics Committee. Informed consent was obtained from all volunteers in study 1 and all patients in study 2.

RESULTS

Study 1

Angles of lumbar lordosis

Mean angles of lumbar lordosis under the three wearing conditions are shown in Table 1. Mean angle in the standing position was similar to that in the prone position (23.6° ± 6.8° and 24.6° ± 8.9°, respectively). Mean angle of lumbar lordosis decreased significantly to 14.4° ± 8.2° after adjustment to decreased lordosis in the prone position.

Table 1. Mean thoracic kyphosis and lumbar lordosis angles for each orthosis.

	No-CMS	P-CMS	DP-CMS
Thoracic kyphosis angel (°)	46.4 ± 8.9	31.9 ± 11.7	24.9 ± 8.9
Lumbar lordosis angle (°)	23.6 ± 6.8	24.6 ± 8.9	14.4 ± 8.2

Range of motion during spinal flexion and extension

Mean range of trunk motion for each volunteer during flexion and extension under the three wearing conditions is shown in Figure 5. Mean flexion angles under the No-CMS, P-CMS, and DP-CMS conditions were 88.9° ± 10.3°, 81.6° ± 10.4°, and 98.9° ± 6.8°, respectively. There were significant differences in flexion angle between the No-CMS and DP-CMS conditions and between the P-CMS and DP-CMS conditions. Mean extension angles under the No-CMS, P-CMS, and DP-CMS conditions were 28.6° ± 5.1°, 22.0° ± 5.6°, and 31.9° ± 4.6°, respectively. There were significant differences between the No-CMS and P-CMS conditions and between the P-CMS and DP-CMS conditions. Movements were most restricted when the subjects were wearing the CMS molded to adjust for lumbar lordosis and the prone position.

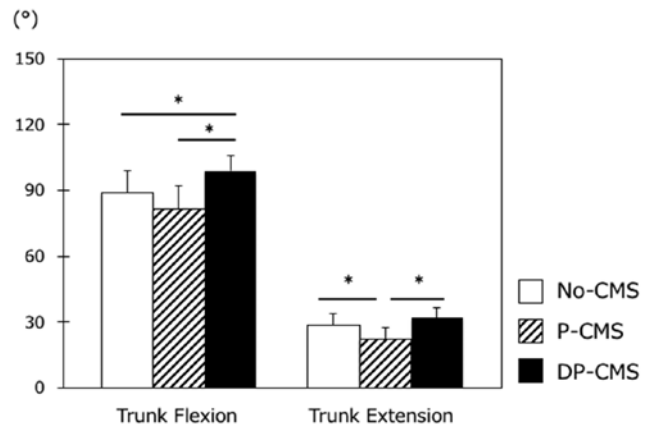


Figure 5. Graphs showing the mean ranges of motion in flexion and extension of the trunk for each orthosis. *p < 0.05 after Wilcoxon's adjustment between each condition. CMS, custom-made stay; P-CMS, CMS made of glass fibers fitted to the lumbar lordosis of each subject in the prone position; DP-CMS, CMS fitted in the prone position with decreased lordosis.

Load distribution on the back support during spinal flexion

The Fit Cure-Spine orthosis is believed to restrict forward bending of the trunk by providing three-point support at the lumbar region (by the CMS) and at the thoracic region (by the shoulder and chest belts; Figure 6). In this study, we evaluated the extent to which the difference in the type of CMS used influences function by measuring the stress distribution. Figure 7 shows the mean compressive load in each square grid during spinal flexion. For each volunteer, the trunk was bent forward and the load on the back support under the P-CMS and DP-CMS conditions was concentrated on the center of the CMS, which is in contrast with the No-CMS condition.

Study 2

VAS scores

Mean VAS score at rest immediately after surgery was 33.2 ± 28.1 and 36.5 ± 29.8 without and with the Fit Cure-Spine device, respectively. At 1 week postoperatively, mean VAS score



Figure 6. The Fit Cure-Spine orthosis is thought to provide three-point support in the lumbar region via the custom-made stay and in the thoracic region via the shoulder and chest belts.

was 21.2 ± 28.1 and 16.2 ± 20.6 with and without the orthosis, respectively. The respective values were 6.9 ± 11.0 and 6.1 ± 9.9 at 2 weeks and 4.6 ± 9.3 and 3.7 ± 7.9 at 3 weeks postoperatively. There were no statistically significant differences in mean VAS scores recorded at rest at any of the time points (Figure 8).

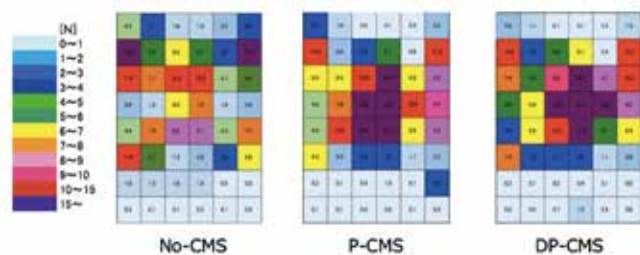


Figure 7. The mean compressive load in each grid square during spinal flexion. The volunteer's trunk was bent forward and the load on the back support under the P-CMS and DP-CMS conditions was concentrated on the center of the CMS, unlike under the No-CMS condition. CMS, custom-made stay ; P-CMS, CMS made of glass fibers fitted to the lumbar lordosis of each subject in the prone position ; DP-CMS, CMS fitted to each subject in the prone position with decreased lordosis.

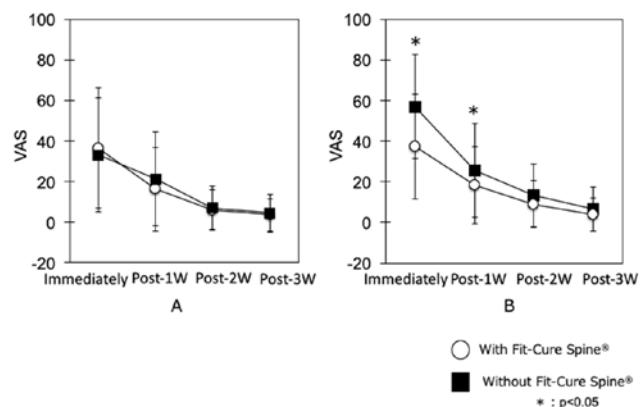


Figure 8. (A) Mean VAS pain scores at rest immediately after surgery and at 1, 2, and 3 weeks postoperatively with and without the Fit Cure-Spine orthosis. There are no statistically significant differences in scores obtained at rest. (B) Mean VAS pain scores on activity immediately after surgery and at 1, 2, and 3 weeks postoperatively with and without the Fit Cure-Spine orthosis. There was a significant difference in the VAS pain score immediately after surgery and at 1-week postoperatively. * $p < 0.05$. VAS, visual analogue scale.

Mean VAS score on activity immediately after surgery was 37.2 ± 25.9 and 57.0 ± 25.4 with and without the Fit Cure-Spine device, respectively. At 1 week postoperatively, mean VAS score was 18.4 ± 19.1 and 25.4 ± 23.0 with and without the orthosis, respectively. The respective values were 8.9 ± 11.7 and 13.3 ± 15.6 at 2 weeks and 4.0 ± 8.1 and 6.6 ± 11.0 at 3 weeks postoperatively. There was a significant difference between the VAS pain score recorded immediately after surgery and at 1 week postoperatively.

Comfort and wearability

Questionnaire results regarding the comfort and wearability of the orthosis are presented in Table 2. Most patients were not concerned about the orthosis being attached to the body. Overall, approximately 90% of the patients wore their orthosis for ≥ 12 h daily. Approximately 80% of participants were very satisfied or satisfied in terms of perceiving the orthosis to be comfortable to wear. However, 24% reported difficulty putting the orthosis on and taking it off and 90% felt that the sensation of having the orthosis on the body and its movement was too strong and somewhat strong. When asked to rate their overall satisfaction with the orthosis, 14%, 50%, and 36%, reported being very satisfied, satisfied, and undecided, respectively.

DISCUSSION

A spinal orthosis is often used to restrict movement of the spine as part of treatment for several spinal disorders, including postoperatively, to provide mechanical support, enhance comfort, and protect implants from biomechanical forces (2,3,4,9,10,11,12). For the orthosis to be effective, it is important that it fits the patient's trunk and has adequate stiffness; generally, this requires modeling using gypsum with the patient in a standing position and maintaining an ideal posture despite back pain. Furthermore, it takes approximately a week to create a custom-made rigid orthosis. In clinical practice, it is common to encounter patients postoperatively or post-trauma who need immediate external support. However, until now, there have been limited orthotic options for these patients.

If an orthosis is modeled before corrective spinal fusion surgery, it will not fit the patient's trunk because of the change in posture postoperatively. Furthermore, the patient's general physical status may be too poor immediately after such invasive surgery to maintain a standing position with adequate posture for the time needed for modeling the orthosis, and postoperative wound pain adds to this difficulty in older patients. It is known that early mobilization is important to avoid postoperative complications, in particular cardiovascular events (5), disuse atrophy

Table 2. Evaluation of comfort and ease of wear

	Easy to wear	Normal	Difficult to wear	
Perceived ease of use (%)	19	57	24	
	Too strong	Strong	Fit	
Perceived stability (%)	33	57	10	
	Except when bathing	10h	12h	
Time spent wearing brace (%)	88	7	5	
	Very satisfied	Satisfied	Undecided	Dissatisfied
Perceived comfort (%)	17	62	19	2
Overall satisfaction (%)	14	50	36	

(6), urologic dysfunction (7), and deep vein thrombosis (8). To address these problems, we have developed a new semi-rigid thoracolumbar orthosis and validated its clinical effectiveness.

Three-point support with a spinal orthosis is used to treat several common spinal disorders (13). The Fit-Cure Spine semi-rigid thoracolumbar orthosis used in the present study was developed taking into account the three-point support theory. This orthosis supports the trunk via CMS fitted to the lumbar lordosis of the individual patient, restricts backward bending, and is believed to restrict forward bending of the trunk by providing three-point support in the lumbar region via the CMS and in the thoracic region via the shoulder and the chest belts.

In study 1, we evaluated the effectiveness of the CMS by comparing the orthosis with and without the CMS molded to meet the shape of the patient's back in the prone position. We also assessed the influence of the shape of the CMS by comparing use of the orthosis in the prone position and that with decreased lordosis. Mean angle in the standing position was similar to that in the prone position, suggesting that the CMS molded in the prone position would be similar to that molded in the standing position. However, there was a significant decrease in thoracic kyphosis in the prone position. This finding may reflect a potential thoracic flexibility in the volunteers.

Our findings suggest that the CMS may be useful for maintaining good posture and restricting forward/backward bending of the trunk. A biomechanical study of two alternative semirigid thoracolumbar orthoses in volunteers performed by Kienie *et al.* reported a stabilizing effect (2). In that study, the increased stability was statistically significant despite the inability of either orthosis to achieve complete immobilization. We believe that the stabilizing effect would be increased only if a CMS was inserted.

The questionnaire responses indicate that patient compliance with the orthosis was mostly satisfactory. VAS pain scores on activity decreased significantly immediately after surgery and 1 week postoperatively when the orthosis was worn. Our findings indicate that the orthosis has a significant effect within 2 weeks of surgery. However, we do not have any evidence as yet regarding the local stability of the fusion site, although there was a significant difference between VAS pain score immediately after surgery and at 1 week postoperatively. These results show that the Fit Cure-Spine could significantly decrease surgical wound pain in the first 2 weeks postoperatively. Therefore, we recommend the Fit-Cure Spine be prescribed for 2 weeks after surgery as a temporary orthosis. Ideally, a rigid brace should be modelled after confirming that wound pain has resolved and the patient can easily remain in a standing position. The results also indicate that this orthosis effectively restricts forward bending of the trunk regardless of the type of CMS used. Thus, we believe this orthosis would be useful in patients with several types of thoracolumbar disorders, such as the acute phase of a compression fracture, degenerative disc disease, and infectious discitis.

We acknowledge that this study 1 is limited in that measurements were obtained from healthy adult male volunteers with no history of low back pain, musculoskeletal injury, or spinal surgery, which may yield different results from those in patients with lumbar disorders.

In conclusion, we have developed a semi-rigid thoracolumbar orthosis that can be fitted immediately after an acute postural change. We have also confirmed its clinical effectiveness by demonstrating its stabilizing effects using two different casts molded as inserted stays during forward/backward bending of the trunk and by the results of a satisfaction survey in patients who have undergone various types of lumbar surgery.

CONFLICTS OF INTEREST

The authors would like to acknowledge the funding received from Medical Engineering Laboratory, Alcare Co., Ltd., Tokyo, Japan.

ACKNOWLEDGEMENTS

The authors thank Hiroyuki Yamada and Takushi Kasashima for providing technical advice regarding the statistical analysis.

REFERENCES

1. Yavin D, Casha S, Wiebe S, Feasby TE, Clark C, Isaacs A, Holroyd-Leduc J, Hurlbert RJ, Quan H, Nataraj A, Sutherland GR, Jette N: Lumbar Fusion for Degenerative Disease: A Systematic Review and Meta-Analysis. *Neurosurgery* 80: 701-715, 2017
2. Kienle A, Saidi S, Oberst M: Effect of 2 different thoracolumbar orthoses on the stability of the spine during various body movements. *Spine* 38: 1082-1089, 2013
3. Jegede KA, Miller CP, Bible JE, Whang PG, Grauer JN: The effects of three different types of orthoses on the range of motion of the lumbar spine during 15 activities of daily living. *Spine* 36: 2346-2353, 2011
4. Connolly PJ, Grob D: Bracing of patients after fusion for degenerative problems of the lumbar spine—yes or no? *Spine* 23: 1426-1428, 1998.
5. Taylor HL, Henschel A, Bozek J, Keys A: Effects of bed rest on cardiovascular function and work performance. *J Appl Physiol* 2: 223-239, 1949
6. Wall BT, van Loon LJ: Nutritional strategies to attenuate muscle disuse atrophy. *Nutr Rev* 71: 195-208, 2013
7. Skelly JM, Guyatt GH, Kalbfleisch R, Singer J, Winter L: Management of urinary retention after surgical repair of hip fracture. *CMAJ* 146: 1185-1189, 1992
8. Severinsen MT, Johnsen SP, Tjønneland A, Overvad K, Dethlefsen C, Kristensen SR: Body height and sex-related differences in incidence of venous thromboembolism: A Danish follow-up study. *Eur J Intern Med* 21: 268-272, 2010
9. Terai T, Yamada H, Asano K, Nawata A, Iwasaki T, Henmi T, Sairyō K: Effectiveness of three types of lumbar orthosis for restricting extension motion. *Eur J Orthop Surg Traumatol* 24: S239-243, 2014
10. Axelsson P, Johnsson R, Stromqvist B: Lumbar orthosis with unilateral hip immobilization. Effect on intervertebral mobility determined by roentgen stereophotogrammetric analysis. *Spine* 18: 876-879, 1993
11. Bono CM, Lee CK: Critical analysis of trends in fusion for degenerative disc disease over the past 20 years: influence of technique on fusion rate and clinical outcome. *Spine* 29: 455-463, 2004
12. Cholewicki J, Alvi K, Silfies SP, Bartolomei J: Comparison of motion restriction and trunk stiffness provided by three thoracolumbosacral orthoses (TLSOs). *J Spinal Disord Tech* 16: 461-468, 2003
13. Patwardhan AG, Li SP, Gavin T, Lorenz M, Meade KP, Zindrick M: Orthotic stabilization of thoracolumbar injuries. A biomechanical analysis of the Jewett hyperextension orthosis. *Spine* 15: 654-661, 1990