

ORIGINAL

Clinical characteristics of dermatomyositis/polymyositis associated interstitial lung disease according to the autoantibody

Tomoo Kishaba¹, Rita McGill², Yuichiro Nei¹, Sachi Ibuki³, Masashi Momose^{1, 4}, Kenta Nishiyama^{1, 5}, Hiroaki Nagano¹, and Shin Yamashiro¹

¹Department of Respiratory Medicine, Okinawa Chubu Hospital, Uruma, Okinawa, Japan, ²Division of Nephrology, University of Chicago, Illinois, USA, ³Department of Rheumatology and Clinical Immunology, Graduate School of Medicine, Kyoto University, Kyoto, Japan, ⁴Division of Internal Medicine, Miyako Hospital, Miyakojima, Okinawa, Japan, ⁵Division of Internal Medicine, Hokubu Hospital, Nago, Okinawa, Japan

Abstract : Background : Dermatomyositis (DM) and polymyositis (PM) often have association with interstitial lung disease (ILD) which have disease specific autoantibody. **Methodology :** We reviewed medical records of DM/PM associated ILD from January 2000 to December 2017 according to the autoantibody. **Result :** We identified 52 patients, of whom 30 were antibody negative, 18 had anti aminoacyl-tRNA synthetases (ARS) antibodies and 4 had anti melanoma differentiation-associated gene (MDA)-5 antibody. In high resolution computed tomography (HRCT) of the chest, area of ground glass opacity (GGO), consolidation, and lung tip consolidation were more extensive in anti MDA-5 antibody positive patients ($p=0.051$, $p=0.026$, and $p=0.027$, respectively). Among laboratory findings, GOT had strong correlations with CPK ($r=0.889$, $p<0.001$), and LDH ($r=0.910$, $p<0.001$). Among roentgenographic findings, there were moderate correlations between GGO and consolidation ($r=0.668$, $p<0.001$), and between reticular shadow and traction bronchiectasis ($p=0.633$, $p<0.001$). ILD patients with anti MDA-5 antibodies had decreased survival (1.00 vs 84.3, 22.9 months, $p<0.001$). **Conclusion :** ILD patients with anti ARS antibody had intense inflammation, but reversible fibrosis and good prognosis. On the other hand, anti MDA-5 antibody positive ILD patients had shorter survival. Extent of parenchymal shadow and serum GOT were useful indicator of disease activity of PM/DM associated ILD patients in our cohort. *J. Med. Invest.* 65 : 251-257, August, 2018

Keywords : Polymyositis/Dermatomyositis (PM/DM), Interstitial lung disease (ILD), aminoacyl-tRNA synthetases (ARS), Anti melanoma differentiation-associated gene (MDA)-5, GOT

INTRODUCTION

Dermatomyositis (DM) and polymyositis (PM) are two major idiopathic inflammatory myopathies (IIMs), which mainly affect skin, muscle, lung (1, 2). The estimated annual incidence of PM/DM ranges from 6 to 10 per million (3). Traditionally, PM associated interstitial lung disease (ILD) have been thought to have a chronic clinical course (4, 5). Recently, autoantibodies against aminoacyl-tRNA synthetases (ARS) have been shown to indicate a subacute course and good prognosis (6, 7). In contrast, some patients with ILD associated with DM, especially those with clinically amyopathic dermatomyositis (CADM), who have the typical rash of DM with little or no definite muscle symptoms or hypomyopathic DM which mild muscle weakness with no elevation of muscle enzyme for > 6 months who have anti melanoma differentiation-associated gene (MDA)-5 antibody present with rapid progressive disease and have a poor prognosis (7-9). Approximately one-third of the patients with DM, CADM, PM develop ILD (4, 10) and acute severe forms of ILD sometimes occur in DM or CADM patients. Therefore, ILD is an important extra-muscular manifestation of IIMs (11, 12), which causes substantial morbidity and results in up to 50% of mortality (13). The spectrum of IIMs ranges

from a mild chronic course to a fulminant rapidly progressive course (14, 15). Some reports have described clinical characteristics of ILD associated with PM or DM, but little is known about the clinical, laboratory and radiological findings of each phenotype, including myositis specific antibodies such as anti ARS autoantibody and anti MDA-5 antibody, which have been recently shown to have associations with these diseases (16). The aim of this retrospective study was to evaluate clinical and radiological characteristics of PM/DM patients according to autoantibody status.

METHODOLOGY

Study population

We retrospectively identified ILD patients from 2000 April to 2017 December at Okinawa Chubu Hospital, and determined whether anti ARS antibody or anti MDA-5 antibody were present. The diagnosis of PM/DM was based on the criteria of Bohan and Peter (1). 1) systemic muscle weakness, 2) increased serum muscle enzyme levels, 3) electromyographic (EMG) evidence of myopathic changes, 4) typical histologic findings in muscle biopsies, and/or 5) characteristic dermatologic manifestations of DM. CADM, or dermatomyositis sine myositis defined by the absence of clinically significant muscle symptoms and normal muscle enzymes such as creatine kinase (CK) for periods of > 6 months. CADM is associated with an acute severe forms of ILD (7, 9, 12, 15, 16). Baseline clinical parameters including pulmonary function testing (PFT), and radiological findings were collected from the time of diagnosis.

Received for publication April 25, 2018 ; accepted July 2, 2018.

Address correspondence and reprint requests to Tomoo Kishaba, Department of Respiratory Medicine, Okinawa Chubu Hospital, Uruma, Okinawa, Japan and Fax : 81-974-5165.

We included PM/DM patients who had parenchymal shadow and were screened autoantibodies, including anti-Jo-1 antibody at least. PM/DM patients without interstitial pneumonia were excluded.

Clinical information

We reviewed clinical symptoms such as fever, cough, dyspnea, myalgia, arthralgia, Raynaud phenomenon, and physical findings such as mechanic hand, rash, subungual erythema, erythema, heliotrope rash, Gottron's sign, and finger swelling. We collected laboratory results for WBC, CRP, CPK, GOT, GPT, ALP, LDH, Krebs von den Lungen-6 (KL-6), and ferritin. Auto-antibodies including anti-Jo-1 (17, 18) other anti ARS antibody and anti-melanoma differentiation-associated gene 5 (MDA-5) antibody were measured (19, 20). In physiological findings, we reviewed forced vital capacity (FVC), percent predicted FVC, total lung capacity (TLC), and percent predicted TLCs. The interval between PFT and chest high resolution computed tomography (HRCT) was within three months.

We evaluated disease activity on the basis of degree of muscle inflammation such as serum GOT and ILD activity with extent of parenchymal shadow.

Autoantibody measurement

Anti-ARS antibody was measured by [³⁵S]methionine-labelled protein immunoprecipitation (IPP) using extracts of HeLa cells and by RNA-IPP using NET-2 buffer (50 mM Tris-HCl at pH 7.5, 150 mM NaCl, 0.05% NP-40) (21, 22).

Radiological findings

Non-contrast chest HRCT findings were reviewed. These images comprised 1.5 mm collimation sections at 10 mm intervals. We evaluated for consolidation, ground-glass opacity (GGO), reticular shadow, traction bronchiectasis and lung tip consolidation at below 1 cm of right diaphragm. Evaluation field were six which including carina, right inferior pulmonary vein, and below 1 cm of right diaphragm of both lungs. Ground-glass opacity was defined if there was hazy increased attenuation of the lung that did not obscure the underlying vessels. Consolidation was defined as homogeneous increase in pulmonary parenchymal attenuation that obscured the underlying vessels. Reticular shadow was defined as regular interlacing linear shadows separated by a few millimeters. Traction bronchiectasis was defined as Irregular bronchial dilatation within or around areas with parenchymal abnormalities such as consolidation or GGO. Definition of lung tip consolidation was thick consolidation > 2 mm with connection of both right diaphragm and pleura (23). Extent of consolidation, GGO, reticular shadow, traction bronchiectasis was categorized as follows; 0: none, 1: < 25%, 2: 25% < 50%, 3: 50% < 75%, 4: > 75% (24). The extent of lung tip consolidation was defined as 0: none, 1: one thick consolidation, 2: more than two thick consolidations. A thick consolidation was defined as one that measured more than 2 mm. The score of each findings was defined as total sum divided into six.

Treatment protocol

We commenced systemic prednisolone 0.5~1.0 mg/kg/day or plus cyclosporine or tacrolimus with monitoring trough value. Once disease stabilized, we tapered prednisolone every 2 or 4 weeks. When we saw progressive disease, we started intravenous methyl-prednisolone 1 g/day consecutive 3 days plus cyclosporine or tacrolimus and intravenous cyclophosphamide.

This study was approved by the institutional Review Board Board at Okinawa Chubu Hospital with a waiver of informed consent to allow the retrospective study of de-identified data.

Statistical analysis

Continuous variables are presented as median (min, max) or means \pm standard deviations, as appropriate. Categorical variables are presented as percentages. Chi-square and Fisher's exact tests were used to analyze categorical data, and Kruskal-Wallis rank tests were used for continuous data. Pearson correlation coefficient were calculated for each laboratory value and radiological finding. Kaplan-Meier survival curves and the log-rank tests were used to evaluate survival. The level of statistical significance was set at $p < 0.05$. All analyses were performed using STATA version 11.0; (Stata Corp., College Station, TX, USA).

RESULTS

Baseline clinical differences among the PM/DM associated ILD patients based on the autoantibody status

We identified 52 ILD patients with PM or DM. The clinical characteristics are organized in Table 1 according to the autoantibody status. Among anti ARS antibody group, Jo-1 were 14, PL-7 were 2, KS was 1 and OJ was 1. Median age was around 50 and 69.2% were female. Cough was slightly more frequent in anti MDA-5 group, but this was not statistically significant ($p=0.062$). Rash, subungual erythema, splinter hemorrhage, erythema, Gottron's sign and heliotrope rash were seen more often in anti MDA-5 group ($p=0.016, 0.003, 0.001, 0.013, \text{ and } 0.004$, respectively). Survival in the anti MDA-5 group was decreased compared with that of other two groups. (1.00 vs 84.3 and 22.9 months, $p < 0.001$) (Table 1).

Table 1. Clinical characteristics of three groups at diagnosis

	Antibody unknown (n=30)	Anti-ARS antibody (n=18 : Anti-Jo-1 14, Anti PL-7 2, Anti KS 1, Anti OJ 1)	Anti-MDA-5 antibody (n=4)	p-value
Age	55.5 (17, 80)	60.5 (26, 76)	45.5 (23, 55)	0.135
Gender (M/F)	9/21	6/12	1/3	0.940
Smoking (Pack-year)	0 (0, 1400)	13.8 (0, 45)	27 (0, 90)	0.245
Fever (%)	30	38.9	50	0.661
Cough (%)	26.7	55.6	75	0.051
Dyspnea (%)	40	55.6	75	0.316
Myalgia (%)	66.7	44.4	25	0.147
Arthralgia (%)	33.3	27.8	50	0.693
Raynaud (%)	6.7	5.6	0	0.867
Rash (%)	63.3	16.7	100	< 0.001
Subungual erythema (%)	26.7	11.1	100	0.002
Splinter Hemorrhage (%)	13.3	11.1	50	0.139
Mechanic Hand (%)	16.7	11.1	0	0.621
Erythema (%)	46.7	16.7	100	0.006
Gottron's Sign (%)	36.7	5.6	100	0.001
Heliotrope Rash (%)	26.7	0	75	0.003
Sausage Finger (%)	26.7	5.6	75	0.010
Initial PSL dose (mg/day)	40.1 \pm 19.6	44.4 \pm 15.9	52.5 \pm 9.6	0.292
Combination therapy (%)	40	66.7	75	0.711
Survival time (months)	84.3	22.9	1.00	< 0.001

Definition of abbreviation : M=men ; F=female ; ARS=aminoacyl-tRNA synthetases ; MDA-5=melanoma differentiation-associated gene 5 ; PSL=prednisolone.

Laboratory findings : WBC was significantly elevated in the anti-ARS antibody group (p=0.001). Both CRP and KL-6 tended to be elevated in anti-ARS antibody and ferritin tended to show high value. However, there were no statistically significance (Table 2).

Table 2. Laboratory findings according to antibody status at diagnosis

	Antibody unknown (n=30)	Anti-ARS antibody (n=18)	Anti-MDA-5 antibody (n=4)	p-value
WBC (3300-8600/mm ³)	8700 (3700, 16900)	13100 (4900, 21500)	5025 (3600, 8100)	0.001
CRP (0.00-0.14 mg /dl)	0.8 (0, 6.8)	3.8 (0.01, 22.6)	1.4 (0.2, 5.6)	0.133
GOT(13-30 U/ L)	41 (15, 1034)	61 (17, 251)	95 (56, 116)	0.824
GPT(10-42 U/ L)	28 (8, 510)	50 (13, 300)	63 (12, 105)	0.525
CPK(59-248 U/ L)	1079 (30, 29830)	774 (37, 7810)	366 (44, 2107)	0.330
LDH (124-222 U/ L)	490 (169, 2790)	547 (177, 1093)	499 (366, 832)	0.903
KL-6 (105-435 U/ mL)	860 (272, 3650)	909 (169, 9100)	549 (455, 1342)	0.553
Ferritin (30-400 ng/ mL)	981 (46, 2958)	308 (34, 1096)	512 (172, 852)	0.222
SS-A (%)	13.3	33.3	0	0.146

Definition of abbreviation : ARS=aminoacyl-tRNA synthetases ; MDA-5= melanoma differentiation-associated gene 5 ; WBC=white blood cell ; CRP=C-reactive protein ; CPK=creatine phosphokinase ; LDH= lactate dehydrogenase ; KL-6=Krebs von den Lungen-6. Findings are presents as median (interquartile range)

Pulmonary function test

Baseline median FVC and %FVC of anti-ARS antibody group tended to show more restrictive disorders[1.49 (0.95, 1.75) vs 1.89 (1.19, 3.48), p=0.051][60.8 (44.8, 79.5) vs 70.9 (60.7, 100.6), p=0.078]compared to that of antibody negative group.

Imaging

The extent of GGO, consolidation, and lung tip consolidation were significantly increased in anti MDA-5 group (p=0.051, p=0.026, and p=0.027, respectively) (Table 3).

Representative imaging of reticular shadow, traction bronchiectasis and lung tip consolidation are shown in Figure1, Figure 2 and Figure 3. Among four anti MDA-5 antibody associated ILD patients, all but one had lug tip consolidation.

Correlation Analyses

WBC and CRP (r=0.481, p=0.001), GOT and ferritin (r=0.496, p=0.019), and anti MDA-5 antibody and lung tip consolidation (r=0.435, p=0.009) were all weakly correlated. Reticular shadow and traction bronchiectasis (p=0.633, p< 0.001) consolidation and GGO (r=0.668, p< 0.001) were moderately correlated. GOT was strongly correlated with both CPK (r=0.889, p< 0.001) and LDH (r=0.910, p< 0.001) (Table 4). In addition, GOT value of 7 death patients out of 10 showed over 100IU/Lat diagnosis.

Treatment

18 (60%) of the antibody negative group received prednisolone alone. On the other hand, 12(67%) of the patients in the anti ARS

Table 3. Radiological findings of three groups at diagnosis

	Antibody Unknown (n=30)	Anti-ARS antibody (n=18)	Anti-MDA-5 antibody (n=4)	p-value
GGO	2 (0, 3)	2 (0, 4)	2.5 (2, 4)	0.051
Consolidation	1 (0, 4)	1 (0, 4)	3.5 (2, 4)	0.026
Reticular shadow	0 (0, 3)	1 (0, 2)	0.5 (0, 2)	0.203
Traction bronchiectasis	0 (0, 2)	0 (0, 2)	0 (0, 2)	0.667
Lung tip consolidation	0 (0, 2)	0 (0, 2)	2 (0, 2)	0.027

Definition of abbreviation : ARS=aminoacyl-tRNA synthetases ; MDA5= melanoma differentiation-associated gene 5 ; GGO= ground glass opacity. Findings are presented as median (interquartile range)

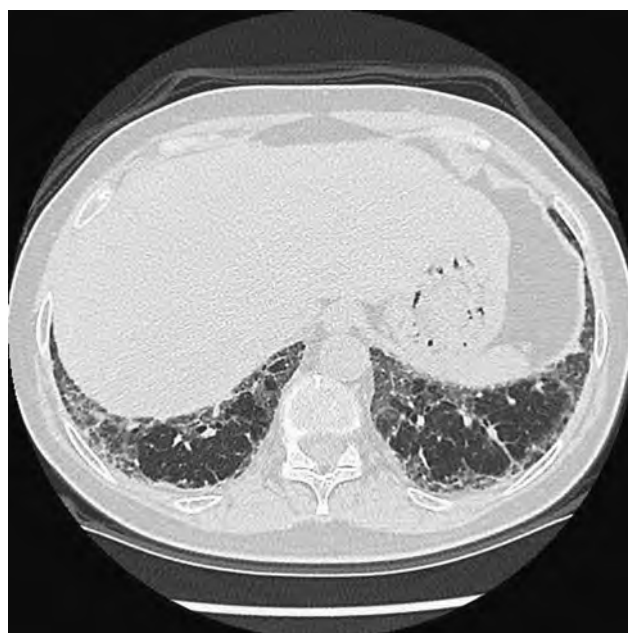

Figure 1. 60-year-old woman of anti PL-7 antibody with reticular shadow
Subpleural reticular shadow were demonstrated.

associated ILD group received prednisolone with other immunosuppressants, such as cyclosporine A or tacrolimus. 3(75%) of the patients in the anti MDA-5 associated ILD group received intensive therapy consisting of pulse corticosteroids, tacrolimus and intravenous cyclophosphamide (IVCY). In maintenance therapy, anti ARS antibody positive ILD patients were more likely to be treated with prednisolone only (54.5% vs 33.3%) and antibody negative patients more likely to receive prednisolone plus tacrolimus (38.9% vs 9.1%). Among 48 patients except for anti-MDA-5 patients, 6 patients showed relapse. And 4 out of 6 relapse patients showed over 100 IU/L of serum GOT at diagnosis. Two anti-MDA-5 antibody positive patients died within a month despite intensive therapy. Kaplan-Meier survival curves show decreased survival in the anti MDA-5 associated ILD group, compared to other two groups (1.0 months vs 79.7 and 23.7 months, p< 0.001). (Figure 4) Among 48

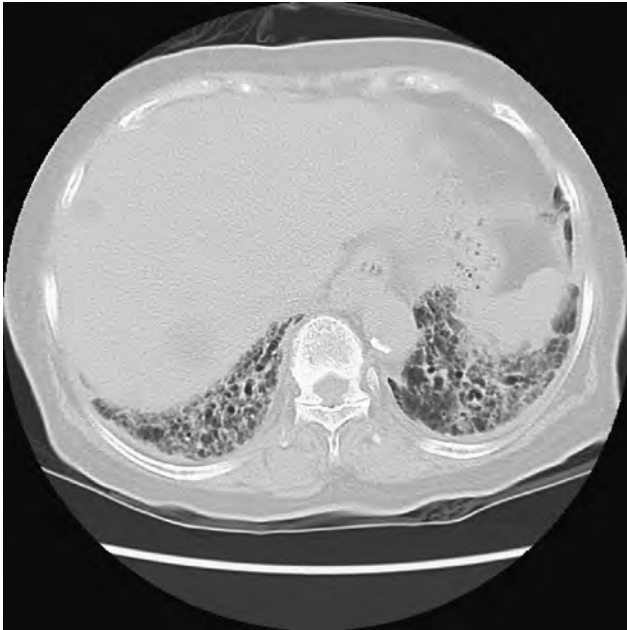


Figure 2. 70-year-old woman of Anti Jo-1 antibody with traction bronchiectasis
Traction bronchiectasis were evident in peribronchovascular bundle.

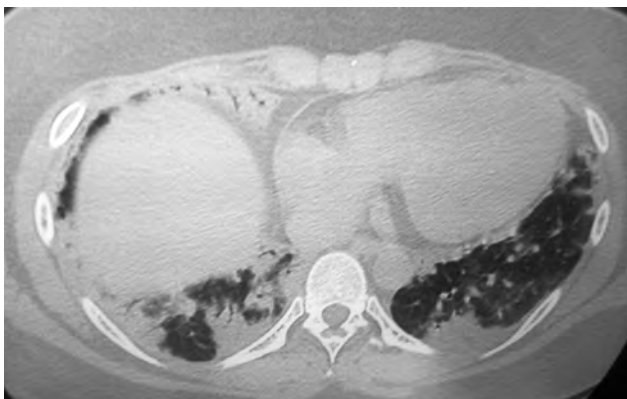


Figure 3. 22-year-old woman of anti MDA-5 antibody with lung tip consolidation
Lung tip consolidation was shown in edge of right diaphragm.

Table 4. Correlation coefficients among clinical parameters

WBC	r=0.481	CRP
GOT	r=0.889	CPK
LDH	r=0.910	GOT
Ferritin	r=0.496	GOT
anti MDA-5 antibody	r=0.435	Lung tip consolidation
Consolidation	r=0.668	GGO
Reticular shadow	r=0.633	Traction bronchiectasis

Definition of abbreviation : WBC=white blood cell ; CRP=C-reactive protein ; CPK= creatine phosphokinase ; LDH=lactate dehydrogenase ; KL-6=Krebs von den Lungen-6 ; GGO=ground glass opacity.

patients who survived acute phase, 6 patients relapsed. Overall, ten patients died during observation period. 4 anti MDA-5 positive patients died from progressive respiratory failure, and 5 patients died from infection and 1 patients died from cancer. And 2 MDA-5 patients were deceased within 1 month from commencing treatment. (Table 5)

DISCUSSION

We described the clinical characteristics, laboratory findings, radiological findings and correlations between laboratory and radiological findings in a series of 52 PM/DM patients, according to their autoantibody status. Cough, rash, subungual erythema, splinter hemorrhage, erythema, Gottron’s sign, and heliotrope rash were more often seen in anti MDA-5 group, who also had more extensive shadow involving of central bronchi and experienced cough more frequently compared to other two groups. In addition, all four anti MDA-5 positive patients satisfied clinical criteria of

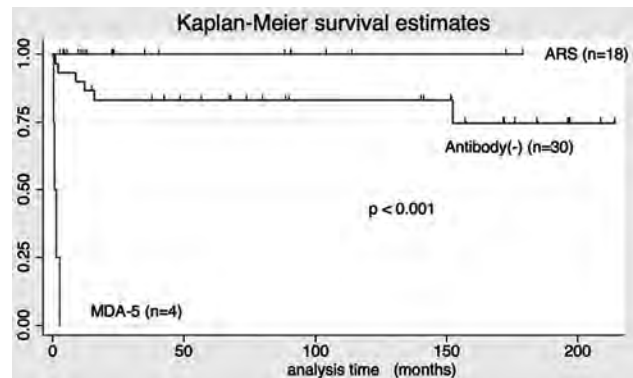


Figure 4. Kaplan-Meier survival curve
Anti MDA-5 antibody positive patients showed statistically significant poor survival compared to other two groups. (Log rank = p < 0.001)

Table 5. Cause of death and interval from initial treatment

	Antibody Type	Cause of Death	Interval from Initial treatment (months)
Case 1 89y F	Unknown	Pneumonia	152.4
Case 2 44y F	Unknown	Pneumonia	12.2
Case 3 80y F	Unknown	Pneumonia	1.9
Case 4 80y M	Unknown	Pneumonia	8.6
Case 5 50y M	MDA-5	Respiratory failure	0.3
Case 6 41y F	MDA-5	Respiratory failure	2.7
Case 7 57y F	Unknown	Cancer	15.8
Case 8 56y F	Unknown	Pneumonia	1.0
Case 9 56y F	MDA-5	Respiratory failure	1.3
Case 10 23y F	MDA-5	Respiratory failure	0.7

Definition of abbreviation : y=year-old ; M= male ; F= female ; MDA5=melanoma differentiation-associated gene 5.

dermatomyositis, with multiple skin manifestations. WBC and CRP were elevated patients with anti-ARS antibody, suggesting a higher degree of inflammation in these patients. KL-6 was also elevated in anti-ARS antibody group, which had reduced lung volume based on FVC and chest HRCT (25-27). Therefore, elevated KL-6 might reflect chronic volume loss with fibrosis. Alternatively, low KL-6 levels were associated with the more acute disease process in anti MDA-5 positive patients. KL-6 is a high molecular weight protein, so induction of KL-6 by epithelial injury and fibrosis may not be able to occur within the limited survival of MDA-5 positive patients. Among radiological findings, significant lung tip consolidation was seen exclusively in anti MDA-5 positive patients, and only minimally present among ILD patients that were anti MDA-5 antibody negative. The more extensive lung tip consolidation of anti MDA-5 antibody positive ILD patients limited diaphragmatic excursion and decreases overall lower lung field volume (23). Based on these findings, we now provide early, high-intensive treatment to patients with lung tip consolidation, hoping to avoid progressive limitation of the smooth movement of right diaphragm. In addition, the removal of exudates in the basal area is more dependent upon gravity and respiratory movement, so persistent inflammation or fibrosis can lead to severe restrictive disorders or profound dyspnea. Among laboratory values, GOT had strong positive correlation with CPK and LDH, but not ferritin, which suggests that muscle dysfunction, inflammation and cell lysis play an important role. We could not demonstrate an association between serum ferritin and mortality, which has been reported in prior studies, especially in anti MDA-5 associated ILD patients (27, 28). The mechanism of inflammation or disease history in our patients might differ. Our results suggest that common laboratory assays for GOT, CPK and LDH are useful for analyzing disease activity in both antibody negative and anti ARS positive antibody associated ILD patients. However, high-risk patients with anti MDA-5 antibody frequently do not have CPK elevation, which should encourage rapid and comprehensive evaluation of ILD progression (28-31).

In serum biomarker, Chen, *et al.* reported that serum KL-6 was useful predictor of disease progression and treatment response of PM/DM ILD patients (32). KL-6 is associated with type II alveolar cell injury and extent of fibrosis. Therefore, decrease KL-6 might be associated with improvement of lung parenchymal shadow. We did not check serum KL-6 of PM/DM ILD patients in our cohort repeatedly. So, trace of serial KL-6 of PM/DM ILD patients warrants future study in Japan.

We noted that the initial prednisolone dosage was somewhat higher in anti MDA-5 positive or anti ARS positive ILD patients compared to antibody negative ILD patients, but this was not statistically significant. In addition, both anti MDA-5 positive and anti ARS positive ILD patients were more likely to receive combination therapy compared to antibody negative patients, although this difference was also not significant. Patients with anti-ARS antibody often have relapse of ILD (32, 33). Therefore, meticulous clinical monitoring of symptoms, biomarkers, and radiological findings, is essential. Anti ARS antibody positive ILD patients often have relapse of parenchymal shadow in the same anatomical location as the original infiltrate. Among our anti ARS antibody positive ILD patients, prednisolone with tacrolimus was more likely to stabilize clinical condition (34). Our ILD patients with anti MDA-5 antibody had a poorer prognosis in our study, which is consistent with prior reports (35-40). Patients with anti-MDA-5 antibody should therefore start intensive therapy as soon as possible. ILD patients with anti MDA-5 antibody who survive the acute phase seldom have been reported to relapse. Therefore, control of disease activity of acute phase is crucial for these high-risk ILD patients with anti MDA-5 antibody. Among 48 patients who survived acute phase, 6 patients relapsed despite slow tapering of systemic prednisolone.

These patients often relapsed under 20 mg of prednisolone. Therefore, meticulous monitoring of disease activity and sensible use of immunosuppressants are required.

The strength of this study is the detailed clinical information obtained on patients from a large ILD program. Certain limitations are worth noting. This was a single-center retrospective study, and may not therefore generalize to all PM/DM ILD patients. However, the clinical signs and symptoms of our patients were comparable with previous reports. Secondly, we lack results for ferritin and new anti-ARS autoantibody for some of our older cases. However, anti Jo-1 antibody was screened for every patient. It is therefore possible that the associations of these tests may have been different if those data were not missing. We also lack PFT in some of the anti MDA-5 associated ILD patients, because of rapid progression and limited survival. Finally, the HRCT performed in our program is not uniformly available in all hospitals, so coordination between referral clinic and special center is important.

In conclusion, ILD patients with anti MDA-5 antibody have a poor prognosis. Cough and leukocytosis are useful indicators, especially in patients with anti ARS antibodies. Muscle enzyme levels such as GOT, CPK and LDH have strong associations with the acute phase of both antibody negative and anti ARS antibody positive ILD patients. Multi center studies are needed to evaluate the clinical findings and define the course of PM/DM ILD patients based on autoantibody status.

ACKNOWLEDGEMENTS

We thank Professor Mimori Tsuneyo from Kyoto University for measuring autoantibody.

FOOTNOTE

Conflicts of Interest : The authors have no conflicts of interest to declare.

ETHICAL STATEMENT

Informed consent was waived by the local Ethics Committee of Okinawa Chubu Hospital. (No.17, 2017)

CONTRIBUTIONS

(I) Conception and design : T.K, Y.N (II) Administrative support : R.M,S.Y (III) Provision of study materials or patients : M.M, K.N (IV) Collection and assembly of data : T.K,H.N,M.M,K.N (V) data analysis and interpretation : T.K,R.M,Y.N,S.I (VI) Manuscript writing : T.K,R.M (VII) Final approval of manuscript : All authors.

REFERENCES

1. Bohan A, Peter JB : Polymyositis and dermatomyositis (first of two parts). *N Engl J Med* 292 : 344-347, 1975
2. Ernste FC, Reed AM : Idiopathic inflammatory myopathies : current trends in pathogenesis, clinical features, and up-to-date treatment recommendations. *Mayo Clin Proc* 88 : 83-105, 2013
3. Dobloug C, Garen T, Bitter H, Stjame J, Stenseth G, Gravel L, Sem M, Gran JT, Molberg O : Prevalence and clinical characteristics of adult polymyositis and dermatomyositis ; data from a large and unselected Norwegian cohort. *Ann Rheum*

- Dis 74(8) : 1551-6, 2015
4. Connors GR, Christopher-Stine L, Oddis CV, Danoff SK : Interstitial lung disease associated with the idiopathic inflammatory myopathies : what progress has been made in the past 35 years? *Chest* 138 : 1464-1474, 2010
 5. Marie I, Hatron PY, Dominique S, Cherin P, Mouthon L, Menard JF : Short-term and long-term outcomes of interstitial lung disease in polymyositis and dermatomyositis : a series of 107 patients. *Arthritis Rheum* 63 : 3439-3447, 2011
 6. Kishaba T : Subacute Interstitial Pneumonia. *J Gen Emerg Med* 2 ; 4 : 020, 2017
 7. Koreeda Y, Higashimoto I, Yamamoto M, Takahashi M, Kaji K, Kuwana M, Fukuda Y : Clinical and pathological findings of interstitial lung disease patients with anti-aminoacyl-tRNA synthetase autoantibodies. *Intern Med* 49(5) : 361-9, 2010
 8. Sontheimer RD : Would a new name hasten the acceptance of amyopathic dermatomyositis (dermatomyositis sine myositis) as a distinctive subset within the idiopathic inflammatory dermatomyopathies spectrum of clinical illness? *J Am Acad Dermatol* 46 : 626-636, 2002
 9. Fujisawa T, Hozumi H, Kono M, Enomoto N, Hashimoto D, Nakamura Y, Inui N, Yokomura K, Koshimizu N, Toyoshima M, Shirai T, Yasuda K, Hayakawa H, Suda T : Prognostic Factors for Myositis- Associated Interstitial Lung Disease. *PLOS ONE* 9(6) : e98824, 2014
 10. Gerami P, Schope JM, McDonald L, Walling HW, Southeimer RD : A systematic review of adult-onset clinically amyopathic dermatomyositis (dermatomyositis sine myositis) : a missing link within the spectrum of the idiopathic inflammatory myopathies. *J Am Acad Dermatol* 54 : 597-613, 2006
 11. Cottin V, Thivolet-Bejui F, Reynaud-Gaubert M, Cadranel J, Delaval P, Ternamian PJ, Cordier JF ; Group d'Etudes et de Recherche sur les Maladies "Orphelines" Pulmonaires : Interstitial lung disease in amyopathic dermatomyositis, dermatomyositis and polymyositis. *Eur Respir J* 22 : 245-250, 2003
 12. Fujisawa T, Suda T, Nakamura Y, Enomoto N, Ide K, Toyoshima M, Uchiyama H, Tamura R, Ida M, Yagi T, Yasuda K, Genma H, Hayakawa H, Chida K, Nakamura H : Differences in clinical features and prognosis of interstitial lung diseases between polymyositis and dermatomyositis. *J Rheumatol* 32 : 58-64, 2005
 13. Suda T, Fujisawa T, Enomoto N, Nakamura Y, Inui N, Naito T, Hashimoto D, Sato J, Toyoshima M, Hashizume H, Chida K : Interstitial lung diseases associated with amyopathic dermatomyositis. *Eur Respir J* 28 : 1005-1012, 2006
 14. Saketkoo LA, Ascherman DP, Cottin V, Christopher-Stine L, Danoff SK, Oddis CV : Interstitial lung disease in idiopathic inflammatory myopathy. *Curr Rheumatol Rev* 6 : 108-119, 2010
 15. Lega JC, Fabien N, Reynaud Q, Durieu I, Durupt S, Dutetre M, Cordier JF, Cottin V : The clinical phenotype associated with myositis-specific and associated autoantibodies : a meta-analysis revisiting the so-called antisynthetase syndrome. *Autoimmunity Rev* 13 : 883-891, 2014
 16. Sontheimer RD, Miyagawa S : Potentially fatal interstitial lung disease can occur in clinically amyopathic dermatomyositis. *J Am Acad Dermatol* 48 : 797-798, 2003
 17. Tanizawa K, Handa T, Nakashima R, Kubo T, Hosono Y, Aihara K, Ikezoe K, Watanabe K, Taguchi Y, Hatta K, Oga T, Chin K, Nagai S, Mimori T, Mishima M : The prognostic value of HRCT in myositis-associated interstitial lung disease. *Respir Med* 107 : 745-752, 2013
 18. Marguerie C, Bunn CC, Beynon HL, Bernstein RM, Hughes JM, So AK, Walport MJ : Polymyositis, pulmonary fibrosis and autoantibodies to aminoacyl-tRNA synthetase enzymes. *Q J Med* 77(282) : 1019-38, 1990
 19. Sato S, Hirakata M, Kuwana M, Suwa A, Inada S, Mimori T, Nishikawa T, Oddis CV, Ikeda Y : Autoantibodies to a 140-kd polypeptide, CADM-140 in Japanese patients with clinically amyopathic dermatomyositis. *Arthritis Rheum* 52(5) : 1571-6, 2005
 20. Tansley SL, Betteridge ZE, Gunawardena H, Jacques TS, Owens CM, Pickington C, Arnold K, Yasin S, Moraitis E, Wedderburn LR, McHugh NJ ; UK Juvenile Dermatomyositis Research Group : Anti-MDA5 autoantibodies in juvenile dermatomyositis identify a distinct clinical phenotype : a prospective cohort study. *Arthritis Res Ther* 16(4) : R138, 2014
 21. Fujita Y, Fujii T, Nakashima R *et al* : Aseptic meningitis in mixed connective tissue disease : cytokine and anti-U1RNP antibodies in cerebrospinal fluids from two different cases. *Mod Rheumatol* 18 : 184-8, 2008
 22. Nakashima R, Imura Y, Kobayashi S, Yukawa N, Yoshifuji H, Nojima T, Kawabata D, Ohmura K, Usui T, Fujii T, Okawa K, Mimori T : The RIG-I-like receptor IFIH1/MDA5 is a dermatomyositis-specific autoantigen identified by the anti-CADM-140 antibody. *Rheumatology (Oxford)* 49(3) : 433-40, 2010
 23. Kishaba T, Nagano H, Nei Y, Shin Yamashiro : Clinical and Radiological Predictor of Polymyositis and Dermatomyositis Associated Interstitial Lung Disease. *Int J Respir Pulm Med* 3 : 059
 24. Sumikawa H, Johkoh T, Thomas V, Colby, Ichikado K, Suga M, Taniguchi H, Kondoh Y, Ogura T, Arakawa H, Fujimoto K, Inoue A, Mihara N, Honda O, Tomiyama N, Nakamura H, Muller NL : Computed Tomography Findings in Pathological Usual Interstitial Pneumonia. Relationship to Survival. *Am J Respir Crit Care Med* 177 : 433-439, 2008
 25. Fathi M, Dastmalchi M, Rasmussen E, Lundberg IE, Tomling G : Interstitial lung disease, a common manifestation of newly diagnosed polymyositis and dermatomyositis. *Ann Rheum Dis* 63 : 297-301, 2004
 26. Jean-Christophe Lega, Quitterie Reynaud, Alexandre Belot, Nicole F, Isabelle D, Cottin V : Idiopathic inflammatory myopathies and the lung. *Eur Respir Rev* 24 : 216-238, 2015
 27. Hamaguchi Y, Kuwana M, Hoshino K, Hasegawa M, Kaji K, Matsushita T, Komura K, Nakamura M, Kodera M, Suga N, Higashi A, Ogusu K, Tsutsui K, Furusaki A, Tanabe H, Sasaoka S, Muro Y, Yoshikawa M, Ishiguro N, Ayano M, Muroi E, Fujikawa K, Umeda Y, Kawase M, Mabuchi E, Asano Y, Sodemoto K, Seishima M, Yamada H, Sato S, Takehara K, Fujimoto M : Clinical correlations with dermatomyositis-specific autoantibodies in adult Japanese patients with dermatomyositis : a multicenter cross-sectional study. *Arch Dermatol* 147 : 391-398, 2011
 28. Mukae H, Ishimoto H, Sakamoto N, Hara S, Kakugawa T, Nakayama S, Ishimatsu Y, Kawakami A, Eguchi K, Kohno S : Clinical differences between interstitial lung disease associated with clinically amyopathic dermatomyositis and classic dermatomyositis. *Chest* 136 : 1341-1347, 2009
 29. Ghirardello A, Bassi N, Palma L, Borella E, Domeneghetti M, Punzi L, Doria A : Autoantibodies in polymyositis and dermatomyositis. *Curr Rheumatol Rep* 15 : 335-342, 2013
 30. Hall JC, Casciola-Rosen L, Samedy LA, Werner J, Owoyemi K, Danoff SK, Christopher-Stine L : Anti-melanoma differentiation-associated protein 5-associated dermatomyositis : expanding the clinical spectrum. *Arthritis Care Res (Hoboken)* 65 : 1307-1315, 2013
 31. Labrador-Horrillo M, Martinez MA, Selva-O'Callaghan A, Trallero-Araguas E, Balada E, Vilardell-Tarres M, Juárez C : Anti-MDA5 antibodies in a large Mediterranean population of adults with dermatomyositis. *J Immunol Res* 2014 : 290797, 2014
 32. Chen F, Lu X, Shu X, Peng Q, Tian X, Wang G : Predictive

- value of serum markers for the development of interstitial lung disease in patients with polymyositis and dermatomyositis : a comparative and prospective study. *Intern Med J* 45(6): 641-7, 2015
33. Takato H, Waseda Y, Watanabe S, Inuzuka K, Katayama N, Ichikawa Y, Yasui M, Fujimura M : Pulmonary manifestations of anti-ARS antibody positive interstitial pneumonia -With or without PM/DM. *Respiratory Medicine* 107 : 128-133, 2013
 34. Hervier B, Devilliers H, Stanciu R, Meyer A, Uzunhan Y, Masseur A, Dubucquoi S, Hatron PY, Musset L, Wallaert B, Nunes H, Maisonneuve T, Olsson NO, Adoue D, Arlet P, Sibilia J, Guiguet M, Lauque D, Amoura Z, Hachulla E, Hamidou M, Benveniste O : Hierarchical cluster and survival analyses of anti-synthetase syndrome : phenotype and outcome are correlated with anti-tRNA synthetase antibody specificity. *Autoimmunity Rev* 12 : 210-217, 2012
 35. Wilkes MR, Sereika SM, Fertig N, Lucas MR, Oddis CV : Treatment of antisynthetase-associated interstitial lung disease with tacrolimus. *Arthritis Rheum* 52 : 2439-2446, 2005
 36. Chen Z, Cao M, Plana MN, Liang J, Cai H, Kuwana M, Sun L : Utility of anti-melanoma differentiation-associated gene 5 antibody measurement in identifying patients with dermatomyositis and a high risk for developing rapidly progressive interstitial lung disease : a review of the literature and a meta-analysis. *Arthritis Care Res (Hoboken)* 65(8) : 1316-24, 2013
 37. Marie I, Hachulla E, Cherin P, Dominique S, Hatron PY, Hellot MF, Devulder B, Herson S, Levesque H, Courtois H : Interstitial lung disease in polymyositis and dermatomyositis. *Arthritis Rheum* 47(6) : 614-22, 2002
 38. Douglas WW, Tazelaar HD, Hartman TE, Hartman RP, Decker PA, Schroeder DR, Ryu JH : Polymyositis-dermatomyositis-associated interstitial lung disease. *Am J Respir Crit Care Med* 164 : 1182-1185, 2001
 39. Selva-O'Callaghan A, Labrador-Horrillo M, Muñoz-Gall X, Martínez-Gomez X, Majó-Masferrer J, Solans-Laqué R, Simeon-Aznar CP, Morell-Brotard F, Vilardell-Tarrés M : Polymyositis/dermatomyositis-associated lung disease : analysis of a series of 81 patients. *Lupus* 14(7) : 534-42, 2005
 40. Kameda H, Nagasawa H, Ogawa H, Sekiguchi N, Takei H, Tokuhira M, Amano K, Takeuchi T : Combination therapy with corticosteroids, cyclosporin A, and intravenous pulse cyclophosphamide for acute/subacute interstitial pneumonia in patients with dermatomyositis. *J Rheumatol* 32(9) : s1719-26, 2005