

CASE REPORT

Percutaneous full endoscopic lumbar foraminoplasty for adjacent level foraminal stenosis following vertebral intersegmental fusion in an awake and aware patient under local anesthesia : A case report

Kazuta Yamashita⁽¹⁾, Kosaku Higashino⁽¹⁾, Toshinori Sakai⁽¹⁾, Yoichiro Takata⁽¹⁾, Fumio Hayashi⁽¹⁾, Fumitake Tezuka⁽¹⁾, Masatoshi Morimoto⁽¹⁾, Takashi Chikawa⁽²⁾, Akihiro Nagamachi⁽¹⁾, and Koichi Sairyō⁽¹⁾

¹⁾Department of Orthopedics, Tokushima University, Tokushima, Japan, ²⁾Department of Orthopedic Surgery, Tokushima Municipal Hospital, Tokushima, Japan

Abstract : Percutaneous endoscopic surgery for the lumbar spine has become established in the last decade. It requires only an 8 mm skin incision, causes minimal damage to the paravertebral muscles, and can be performed under local anesthesia. With the advent of improved equipment, in particular the high-speed surgical drill, the indications for percutaneous endoscopic surgery have expanded to include lumbar spinal canal stenosis. Transforaminal percutaneous endoscopic discectomy has been used to treat intervertebral stenosis. However, it has been reported that adjacent level disc degeneration and foraminal stenosis can occur following intervertebral segmental fusion. When this adjacent level pathology becomes symptomatic, additional fusion surgery is often needed. We performed minimally invasive percutaneous full endoscopic lumbar foraminoplasty in an awake and aware 50-year-old woman under local anesthesia. The procedure was successful with no complications. Her radiculopathy, including muscle weakness and leg pain due to impingement of the exiting nerve, improved after the surgery. *J. Med. Invest.* 64 : 291-295, August, 2017

Keywords : percutaneous endoscopic surgery, lumbar intervertebral foraminal stenosis, foraminoplasty, local anesthesia, adjacent level stenosis

INTRODUCTION

Lumbar fusion is now an accepted treatment for degenerative lumbar spondylolisthesis, but may cause adjacent segment disease (ASD). (1-7) Maruenda *et al.* (3) reviewed a series of 73 patients who underwent circumferential lumbar fusion and were followed up for 15 years after surgery. When followed up at 5 and 10 years, seven (9.6%) and 18 (24.6%) of these patients, respectively, had required redo surgery for symptomatic ASD. By the final follow-up at 15 years, 24 patients (37.5%) had undergone further surgical treatment.

Etebar and Cahill (4) retrospectively reviewed 125 patients who underwent spinal fusion and found that the ASD included spondylolisthesis (39%), spinal canal stenosis due to disc herniation and/or facet hypertrophy (33%), a stress fracture of the adjacent vertebral body (28%), and scoliosis (17%). The mean follow-up duration in this group was 44.8 months. Imagama *et al.* (5) evaluated ASD after L4/5 posterior lumbar interbody fusion in detail using plain radiographs, computed tomography (CT), and magnetic resonance imaging (MRI). The incidences of facet joint degeneration, disc degeneration detected on MRI, and spinal stenosis were 21%, 23%, and 27%, respectively, at L3/4 and 17%, 35%, and 4% at L5/S1.

Based on these reports, it seems likely that foraminal stenosis could occur because of ASD and disc degeneration at the adjacent level. Orita *et al.* (6) identified foraminal stenosis de novo at the adjacent level in eight (6.4%) of 125 patients at an average of 13.3

months after fusion surgery. All eight patients were symptomatic and two required additional fusion surgery.

Two surgical treatments for foraminal stenosis have been reported : spinal fusion (6-10) and foraminoplasty. Of these, fusion surgery seems to be the gold standard. In a series reported by Jenis *et al.* (8), 63 of 65 patients with foraminal stenosis required fusion surgery. The other method is minimally invasive percutaneous endoscopic lumbar foraminoplasty (PELF) without fusion (11-14), which is a modification of transforaminal percutaneous endoscopic discectomy (15-19). It is possible to perform PELF under local anesthesia, which would be beneficial for high-risk patients, in particular the elderly and those with significant comorbid conditions. The procedure is performed through an 8 mm skin incision and damage to the paravertebral muscles is minimal ; this percutaneous endoscopic technique is thus the least invasive lumbar surgery available at this time. In this case report, we describe the use of PELF in an awake and aware patient with adjacent level foraminal stenosis following spinal fusion surgery for spondylolisthesis.

CASE REPORT

The patient was a 50-year-old woman with rheumatoid arthritis treated by methotrexate and prednisolone. About 2 years earlier, she had undergone transforaminal lumbar interbody fusion for lumbar spondylolisthesis at L4/5, which had been causing low back pain and pain in both lower limbs (Figure 1). Her postoperative course had been good and her pain had disappeared. However, 6 months after surgery, she felt discomfort in her left buttock and her left lower limb pain returned in a distribution consistent with the area innervated by the L5 nerve. This pain gradually worsened over time.

Received for publication November 25, 2016 ; accepted March 8, 2017.

Address correspondence and reprint requests to Kazuta Yamashita, MD, Department of Orthopedics the University of Tokushima 3-18-15 Kuramoto, Tokushima 770-8503, Japan and Fax : +81-88-633-0178.

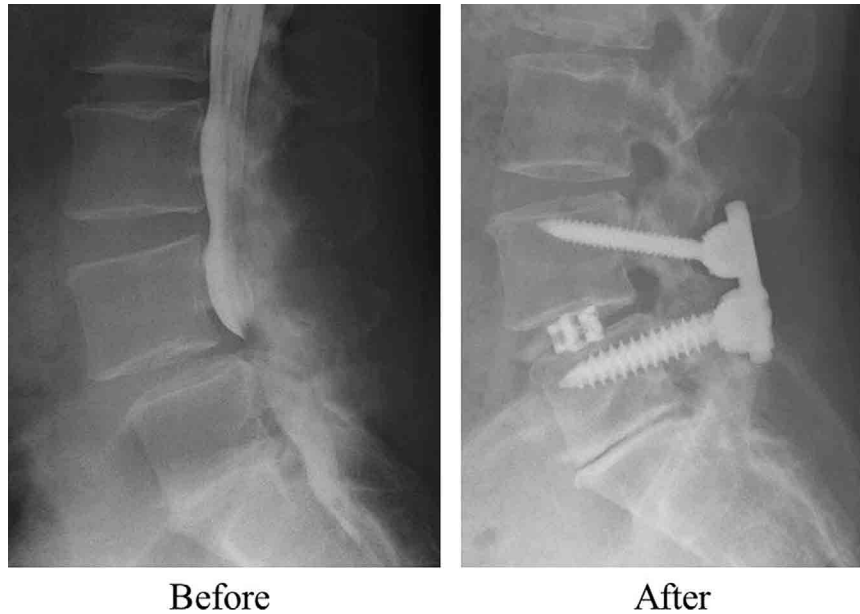


Figure 1. Lumbar myelography and plain lateral X-ray 2 years after fusion surgery. Transforaminal lumbar interbody fusion (TLIF) was done using pedicle screws and an intervertebral body cage. Collapse of the disc space can be seen at L5/S1. Left panel : lumbar myelography before TLIF showed lumbar spinal canal stenosis at L4/5 due to L4 spondylolisthesis. Right panel ; Two years after TLIF. There was no screw loosening and subsidence of the cage.

Neurologic findings

Sensory and deep tendon reflexes were normal. Weakness of the left extensor hallucis longus was apparent and found to be 4/5. The femoral nerve stretch test was bilaterally negative, but the straight leg raise test was slightly positive on the left side. The cause of the patient's pain was hard to detect on MRI due to the effect of the metal implants ; however, a CT scan showed left bony foraminal stenosis at L5/S1 (Figure 2). The patient also had a history of discectomy for herniated nucleus pulposus (HNP) approximately 20 years earlier, and collapse of the disc space at L5/S1 was evident (Figure 1). We confirmed that her symptoms disappeared temporarily on left L5 selective nerve root block (Figure 3), so diagnosed ASD subsequent to transforaminal lumbar interbody fusion and left bony foraminal stenosis at L5/S1. Her symptoms did not improve after about 4 months of conservative treatment. Finally, we

performed PELF using the percutaneous endoscopic discectomy technique.

Surgical technique

The procedure was performed under local anesthesia with the patient in the prone position on a radiolucent table. The skin entry point was about 6 cm from the midline. After administration of local anesthesia around the entry point, an 18-gauge spinal needle was inserted into the L5/S1 disc, and an intraoperative discogram was obtained using a mixture of indigo carmine and contrast medium. Following insertion of a spinal needle into the disc under C-arm fluoroscopic guidance, a guide wire was inserted through the spinal needle, after which the needle was removed. An 8 mm skin incision was made and the tapered cannulated obturator was inserted along with a cannula into the left L5/S1 foraminal area. The endoscope was then inserted into the foraminal space through the cannula.

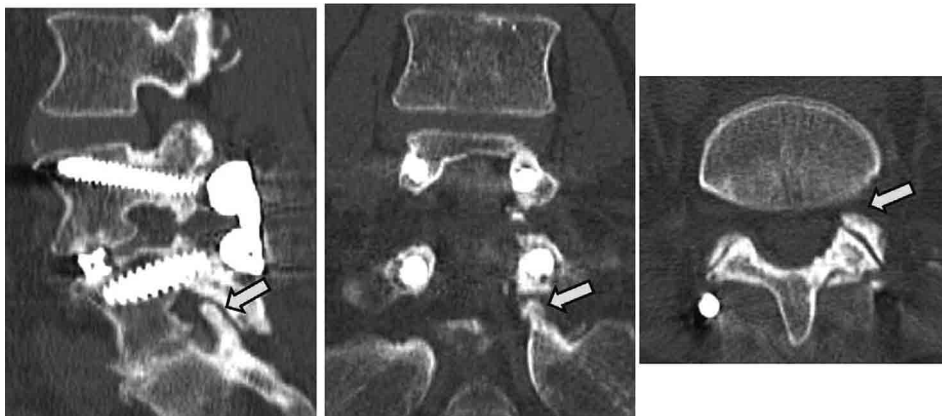


Figure 2. CT scans before percutaneous endoscopic lumbar foraminoplasty. Computed tomography scans show left bony foraminal stenosis at the level of L5/S. There is an obvious protruding bone at the ventral aspect of upper articular process of the sacrum (arrow).

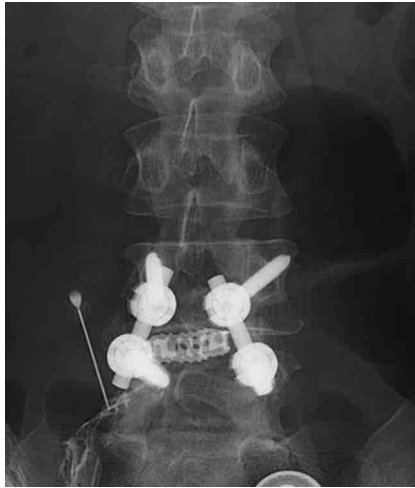


Figure 3. The selective left L5 nerve root block. The selective left L5 nerve root block was effective for the patient's symptom.

The ventral aspect of the superior articular process of the sacrum was removed carefully using a high-speed drill (Figure 4A). Next, the blue-stained slightly bulging nucleus pulposus was exposed (Figure 4B) and removed using small forceps and a radiofrequency wave system. Adequate decompression was achieved by careful removal of the residual ventral aspect of the superior articular process (Figure 4C). The endoscope and cannula were then removed, which was followed by placement of a catheter, wound closure using a single stitch, and application of a sterile dressing. The procedure took 62 minutes to perform and there was limited blood loss. We did not encounter any surgery-related complications such as nerve root damage, dural tearing, hematoma, or infection.

Postoperative course

The patient's postoperative course was good, and her symptoms disappeared immediately after the surgery. The patient was able to stand and walk 2 hours after her operation. Postoperative CT scans revealed that the foramen at L5/S1 had been expanded adequately without damaging the facet joint (Figure 5). The weakness of the left extensor hallucis longus resolved about 2 weeks postoperatively.

DISCUSSION

Percutaneous endoscopic discectomy was initially indicated for HNP (15-19). With the advent of improved surgical equipment, in particular the ultra-thin high-speed drill, which can be operated in the small working space of an endoscopic system, percutaneous endoscopic discectomy can now be used to treat a variety of conditions. Dezawa *et al.* used the ultra-thin high-speed drill to make a bone hole through the lamina and removed an HNP in the hidden zone using a translaminar approach (20). Transforaminal percutaneous endoscopic discectomy is challenging when performed for HNP at the L5/S1 level if there is obstruction by a high iliac crest. Abe *et al.* (21) performed foraminoplasty-the enlargement of the intervertebral foramen using an ultra-thin high-speed drill to obtain safe access to the neural canal at the lumbosacral junction-for removal of HNP. Foraminoplasty can even be used at the L4/5 level to avoid injury to the exiting nerve during surgery (14).

We have performed transforaminal lumbar intervertebral body fusion in a patient with foraminal stenosis at a level adjacent to spinal arthrodesis at L4/5. The foraminal stenosis was observed at the left L5/S1 level. As being reported before, degenerative change such as facet hypertrophy can appear at the adjacent level following spinal fusion (4, 5). Foraminal stenosis can also occur due to facet hypertrophy (4, 5) and disc collapse (22). Orita *et al.* (6) reported a series of patients with foraminal stenosis at the adjacent level following spinal fusion in whom symptoms appeared on average

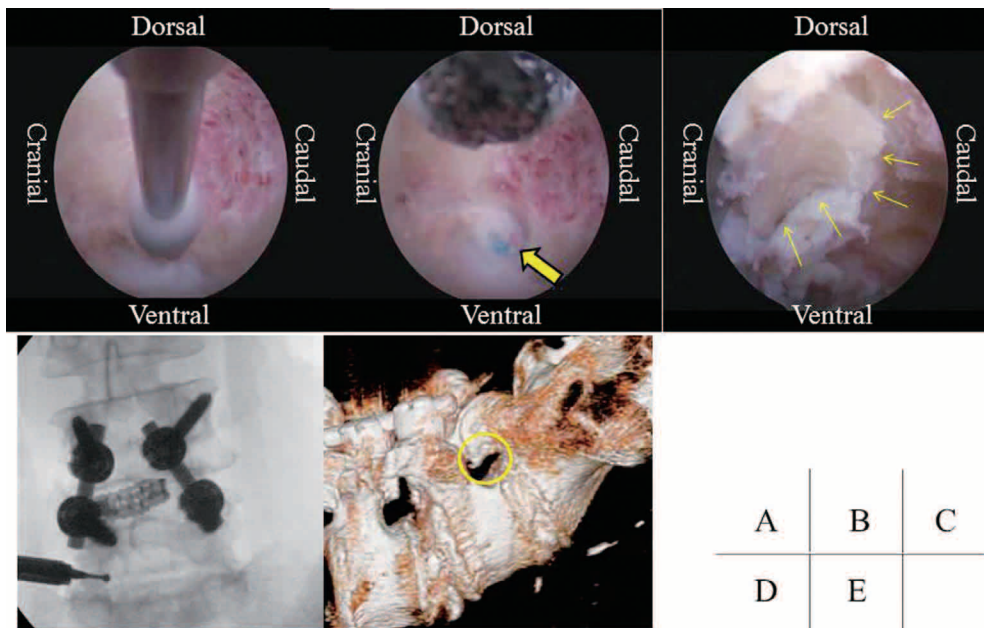


Figure 4. The intraoperative endoscopic view (A) The protruding bone was dug using high-speed drill. (B) The blue stained nucleus pulposus was exposed (arrow). (C) The residual ventral aspect of the superior articular process (arrow) was broken off and removed. (D) The endoscopic procedure was done under fluoroscopically. (E) The circle in the 3D-CT shows the field of endoscopic view.

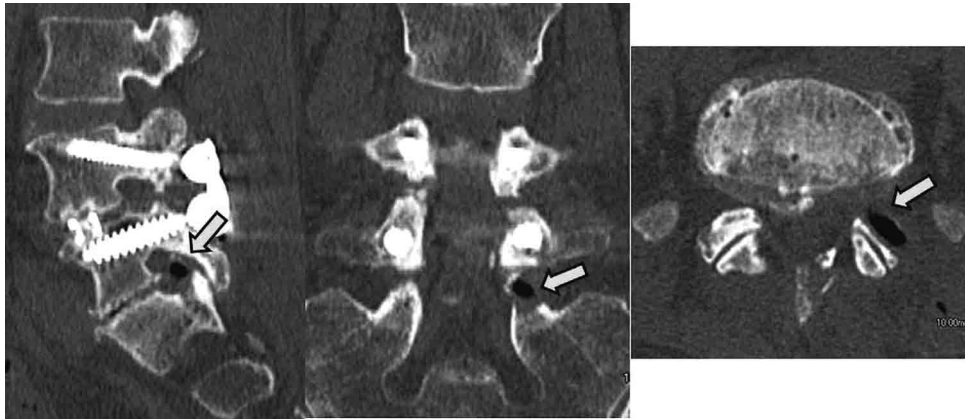


Figure 5. CT scans after the PELF. The CT scans show the sufficient decompression of the left foramen at L5/S (arrow).

13.3 months after surgery. In the present case report, radiculopathy developed only 6 months after fusion surgery in a patient with a history of discectomy at L5/S1 about 20 years earlier and pre-existing disc collapse. Hence, symptoms may appear at the adjacent level within months of surgery.

Fusion seems to be the gold standard for surgical treatment of foraminal stenosis (6-10). The alternative surgical treatment is minimally invasive PELF without fusion (11-14). Yeung and Gore performed PELF in 30 patients under local anesthesia and reported that the mean visual analog pain score improved from 7.2 preoperatively to 4.0 postoperatively (11). Ahn *et al.* (12) reported excellent or good clinical results in at least 80% of 35 patients with foraminal stenosis treated by transforaminal percutaneous endoscopic discectomy. In our patient, the leg pain disappeared and the muscle weakness resolved following a PELF procedure.

The benefits of PELF are two-fold. First, the surgery can be performed in an awake and aware state under local anesthesia and direct injury to the exiting nerve root can be avoided (23). Further, elderly patients who would normally be considered high-risk for general anesthesia because of comorbid heart, lung, liver, and kidney conditions can be considered for PELF under local anesthesia (24). Second, it is possible to perform PELF without fusion. In our patient, the foraminal stenosis appeared at the level adjacent to the fusion, where additional fusion surgery could have facilitated further spondylotic degenerative changes. PELF without fusion may avoid this complication.

PELF is the surgery that has been applied PED surgery. Thus surgeons have to be careful not to cause complications, such as exiting nerve root injury, headache, seizure, and organs injury (18). At the local anesthesia and carefully preoperative plans, surgeons can prevent these complications. Compared with microscopic decompression surgery, the advantage of PELF is less invasive surgery, but PELF has possibility of above complications. Surgeons should have adequate surgical training such as animal and cadaver training.

PELF surgery might be able to apply to the recurrent foraminal stenosis of the same level and same side. Generally, the major concern in repeat surgery for recurrent spinal disease is approach-related complications. Scar tissue usually makes repeat surgery more difficult and increases the risk of dural tear and nerve root injury. This case was performed PELF surgery to the adjacent level, so there is no adhesion around the foramen area. The percutaneous endoscopic surgery using transforaminal approach is not the procedure that needs laminectomy and removal of the yellow ligament. We had reported that repeat PED surgery for the same level recurrence of lumbar disc herniation (25). Using the exact

same transforaminal approach, we could easily remove the fragment of recurrent lumbar disc herniation. Thus, surgeons may choose repeat PELF surgery to the recurrent foraminal stenosis.

In conclusion, we have successfully treated foraminal stenosis at the level adjacent to a previous spinal fusion in an awake and aware patient using a minimally invasive PELF technique without fusion under local anesthesia.

REFERENCES

1. Harrop JS, Youssef JA, Maltenfort M, Vorwald P, Jabbour P, Bono CM : Lumbar adjacent segment degeneration and disease after arthrodesis and total disc arthroplasty. *Spine* 33 (15) : 1701-7, 2008
2. Park P, Garton HJ, Gala VC, Hoff JT, McGillicuddy JE : Adjacent segment disease after lumbar or lumbosacral fusion : review of the literature. *Spine* 29(17) : 1938-44, 2004
3. Maruenda JI, Barrios C, Garibo F, Maruenda B : Adjacent segment degeneration and revision surgery after circumferential lumbar fusion : outcomes throughout 15 years of follow-up. *Eur Spine J* 25(5) : 1550-7, 2016
4. Etebar S, Cahill DW : Risk factors for adjacent-segment failure following lumbar fixation with rigid instrumentation for degenerative instability. *J Neurosurg* 90(2 Suppl) : 163-9, 1999
5. Imagama S, Kawakami N, Kanemura T, Matsubara Y, Tsuji T, Ohara T, Katayama Y, Ishiguro N : Radiographic Adjacent Segment Degeneration at Five Years After L4/5 Posterior Lumbar Interbody Fusion With Pedicle Screw Instrumentation : Evaluation by Computed Tomography and Annual Screening With Magnetic Resonance Imaging. *Clin Spine Surg* : 2016. [Epub ahead of print]
6. Orita S, Yamagata M, Ikeda Y, Nakajima F, Aoki Y, Nakamura J, Takahashi K, Suzuki T, Ohtori S : Retrospective exploration of risk factors for L5 radiculopathy following lumbar floating fusion surgery. *J Orthop Surg Res* 10 : 164, 2015
7. Alimi M, Hofstetter CP, Tsiouris AJ, Elowitz E, Härtl R : Extreme lateral interbody fusion for unilateral symptomatic vertical foraminal stenosis. *Eur Spine J* 24(3) : 346-52, 2015
8. Jenis LG, An HS, Gordin R : Foraminal stenosis of the lumbar spine : a review of 65 surgical cases. *Am J Orthop (Belle Mead NJ)* 30(3) : 205-11, 2001
9. Merckaert S, Pierzchala K, Kulik G, Schizas C : Influence of anatomical variations on lumbar foraminal stenosis pathogenesis. *Eur Spine J* 24(2) : 313-8, 2015

10. Lin JH, Chiang YH : Unilateral approach for bilateral foramen decompression in minimally invasive transforaminal interbody fusion. *World Neurosurg* 82(5) : 891-6, 2014
11. Yeung A, Gore S : Endoscopic foraminal decompression for failed back surgery syndrome under local anesthesia. *Int J Spine Surg* 8 : doi : 10.14444/1022. eCollection., 2014
12. Ahn Y, Oh HK, Kim H, Lee SH, Lee HN : Percutaneous endoscopic lumbar foraminotomy : an advanced surgical technique and clinical outcomes. *Neurosurgery* 75(2) : 124-33, 2014
13. Ruetten S, Komp M, Merk H, Godolias G : Use of newly developed instruments and endoscopes : full-endoscopic resection of lumbar disc herniations via the interlaminar and lateral transforaminal approach. *J Neurosurg Spine* 6(6) : 521-30, 2007
14. Henmi T, Terai T, Hibino N, Yoshioka S, Kondo K, Goda Y : Percutaneous endoscopic lumbar discectomy utilizing ventral epiduroscopic observation technique and foraminoplasty for transligamentous extruded nucleus pulposus : technical note. *J Neurosurg Spine* 13 : 1-6, 2015
15. Yeung AT : The evolution of percutaneous spinal endoscopy and discectomy : state of the art. *Mt Sinai J Med* 67 : 327-32, 2000
16. Yeung AT, Tsou PM : Posterolateral endoscopic excision for lumbar disc herniation : Surgical technique, outcome, and complications in 307 consecutive cases. *Spine* 27 : 722-31, 2002
17. Yeung AT, Yeung CA : Minimally invasive techniques for the management of lumbar disc herniation. *Orthop Clin North Am* 38(3) : 363-72, 2007
18. Sairyo K, Egawa H, Matsuura T, Takahashi M, Higashino K, Sakai T, Suzue N, Hamada D, Goto T, Takata Y, Nishisho T, Goda Y, Sato R, Tsutsui T, Tonogai I, Kondo K, Tezuka F, Mineta K, Sugiura K, Takeuchi M, Dezawa A : State of the art : Transforaminal approach for percutaneous endoscopic lumbar discectomy under local anesthesia. *J Med Invest* 61(3-4) : 217-25, 2014
19. Sairyo K, Nagamachi A : State-of-the-art management of low back pain in athletes : Instructional lecture. *J Orthop Sci* 21(3) : 263-72, 2016
20. Dezawa A, Mikami H, Sairyo K : Percutaneous endoscopic translaminar approach for herniated nucleus pulposus in the hidden zone of the lumbar spine. *Asian J Endosc Surgery* 5(4) : 200-203, 2011
21. Abe M, Takata Y, Higashino K, Sakai T, Matsuura T, Suzue N, Hamada D, Goto T, Nishisho T, Goda Y, Tsutsui T, Tonogai I, Miyagi R, Morimoto M, Mineta K, Kimura T, Nitta A, Hama S, Higuchi T, C Jha S, Takahashi R, Fukuta S, Sairyo K : Foraminoplasty transforaminal percutaneous endoscopic discectomy at the lumbosacral junction under local anesthesia in an elite rugby player. *J Med Invest* 62(3-4) : 238-41, 2015
22. Lee S, Kang JH, Srikantha U, Jang IT, Oh SH : Extraforaminal compression of the L-5 nerve root at the lumbosacral junction : clinical analysis, decompression technique, and outcome. *J Neurosurg Spine* 20(4) : 371-9, 2014
23. Sairyo K, Matsuura T, Higashino K, Sakai T, Takata Y, Goda Y, Suzue N, Hamada D, Goto T, Nishisho T, Sato R, Tsutsui T, Tonogai I, Mineta K : Surgery related complications in percutaneous endoscopic lumbar discectomy under local anesthesia. *J Med Invest* 61(3-4) : 264-9, 2014
24. Kitahama Y, Sairyo K, Dezawa A : Percutaneous endoscopic transforaminal approach to decompress the lateral recess in an elderly patient with spinal canal stenosis, herniated nucleus pulposus and pulmonary comorbidities. *Asian J Endosc Surg* 6(2) : 130-3, 2013
25. Yamashita K, Higashino K, Sakai T, Takata Y, Abe M, Morimoto M, Nagamachi A, Sairyo K : Revision percutaneous endoscopic lumbar discectomy under the local anesthesia for the recurrent lumbar herniated nucleus pulposus in a high class athlete : A case Report. *J Med Invest* 63 : 135-9, 2016