

CASE REPORT

Complete Fracture-Dislocation of the Thoracolumbar Spine with No Critical Neurological Deficit : A Case Report

Kosuke Sugiura¹, Toshinori Sakai², Keisuke Adachi¹, Kazumasa Inoue¹, Satoshi Endo¹, Yasuaki Tamaki¹, Koichi Sairyo², and Akihiro Nagamachi¹

¹Department of Orthopedics, Mitoyo General Hospital, Kagawa, Japan, ²Department of Orthopedics, Institute of Biomedical Sciences, Tokushima University Graduate School, Tokushima, Japan

Abstract : Fractures at the thoracolumbar junction are the most common spinal column fractures. Among type C fractures in the Arbeitsgemeinschaft für Osteosynthesefragen Spine Classification, cases with complete fracture-dislocations of the spinal column often result in a critical neurological deficit despite surgical treatment. We present a case of an 18-year-old man who had a complete fracture-dislocation of the T12 vertebral body and multiple injuries following high-energy trauma but no critical neurological deficits. Because of active bleeding in the left thoracic cavity, the patient underwent open reduction of the T12 vertebral body and anterior spinal fusion of the T11-L1 vertebral bodies via an anterior approach between the T9 and T10 ribs within 24 h of the accident. Four months postoperatively, the patient could ambulate independently, with a slight disturbance of light touch. At 6 months postoperatively, plain computed tomography scans showed bony union of the T12 vertebral body. We postulated two reasons for the absence of critical neurological dysfunction : (1) spontaneous spinal canal sparing because of the fracture of the right superior articular process in the L1 vertebral body and (2) fracture morphology, that is, a rotational fracture with mild to moderately strong shearing stress to the dura mater. *J. Med. Invest.* 63 : 122-126, February, 2016

Keywords : Fracture-Dislocation, Trauma, Thoracolumbar Spine, Neurological deficit, Surgery

INTRODUCTION

Among spinal column fractures, fractures at the thoracolumbar junction are the most common. The Arbeitsgemeinschaft für Osteosynthesefragen (AO) Spine Committee classified fractures of the thoracolumbar spine into three main types according to morphology as follows : type A (compression), type B (tension band disruption), and type C (dislocation/translation) (1). Type C fractures often occur following high-energy trauma and typically involve severe neurological deficits. Aebi reported a high incidence of neurological deficit in type C fracture (55% : 97/177), although type C fractures are uncommon among thoracolumbar spinal fractures (15% : 177/1212) (2). Among type C fractures, complete fracture-dislocation with 100% spinal displacement is an uncommon injury, which usually presents with critical neurological deficit and spinal deformity. Wang *et al.* reported that over 70% of patients with complete fracture-dislocation have a complete injury, that is, American Spinal Injury Association Impairment Scale (AIS) A (3).

In this report, we present a rare case of complete fracture-dislocation of the thoracolumbar spine with no critical neurological deficit or spinal deformity after treatment with anterior spinal fusion.

CASE PRESENTATION

An 18-year-old man with no prior medical history who worked in a paper mill was transporting a heavy load weighing approximately 300 kg with a trailer, when the load fell on him from the left

side. He was sandwiched between the load and the floor and lost consciousness. As soon as he was rescued, he was transferred to our emergency room.

During trauma care, he was secured on the backboard. The Glasgow Coma Scale score was 10 (E2V4M4) and he was semi-comatose. His vital signs suggested hypovolemic shock (blood pressure : 70/30 mmHg ; heart rate : 110-120 bpm). After the patient's consciousness improved, he complained of severe back pain, left foot pain, and bilateral pubic pain. Neurological examination indicated muscle weakness in the proximal lower extremities (manual muscle test : iliopsoas 3+/3 ; quadriceps 5/4), and a sensory disturbance of grade 7/10 in light touch in the left inguinal region and on the anterior portion of the left thigh. No other neurological abnormalities were noted.

Laboratory data showed progressive anemia. Plain computed tomography (CT) scans revealed multiple injuries, with right pneumothorax, left hemothorax (Figure 1a), pelvic ring fracture (Figure 1b), left Lisfranc joint dislocation (Figure 1c), and T12 vertebral fracture-dislocation (Figure 2). The fracture line was identified from the anterosuperior corner to the posteroinferior corner of the T12 vertebral body ; the T12 caudal vertebral fragment including the posteroinferior corner had dislocated with left rotation and translation (Figure 3). In addition, the right superior articular process of the L1 vertebra was fractured and dislocated outside of the spinal canal. Thoracolumbar magnetic resonance images revealed continuity of the spinal cord up to the cauda equina, but spinal cord compression by the dislocated T12 lamina was observed in the T2-weighted images (Figure 4).

Although the patient's general condition improved with treatment in the intensive care unit (ICU), active bleeding from the left chest drain persisted. To control the bleeding, we decided to operate to reduce the T12 vertebral dislocation and fuse the damaged spinal column.

Received for publication July 21, 2015 ; accepted August 24, 2015.

Address correspondence and reprint requests to Akihiro Nagamachi, MD, PhD, Department of Orthopedics, Mitoyo General Hospital, 708 Himehama, Toyohama, Kanonji, Kagawa 769-1695, Japan and Fax : +81-875-52-4936.

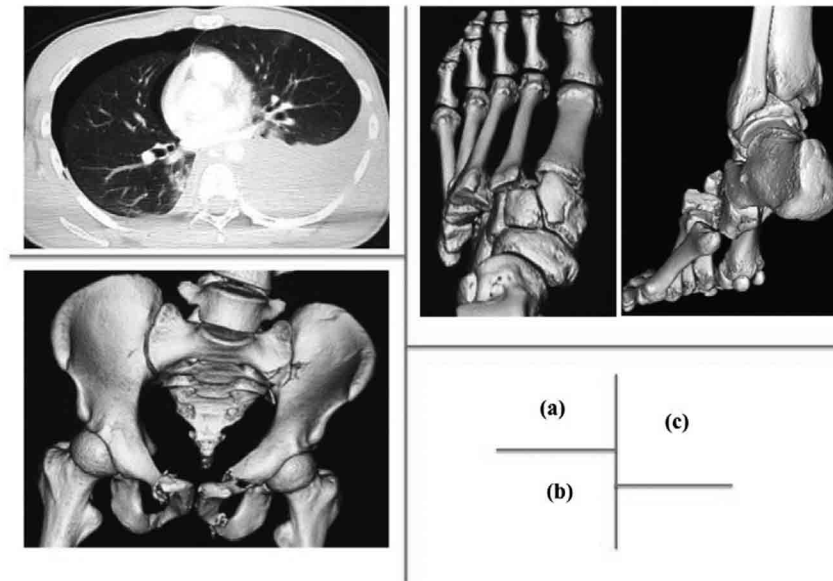


Figure 1

(a) Plain chest computed tomography (CT) image showing right traumatic pneumothorax and left hemothorax. (b) Three-dimensional (3D) pelvic CT image showing pelvic ring fracture affecting the bilateral pubic bones and the left ilium, ischium, and sacrum (Type B in AO classification). (c) The 3D CT image of the left foot showing Lisfranc joint dislocation. The first metatarsal bone was dislocated to the dorsal side, and other metatarsal bones were dislocated to the plantar side (Type C2 in the Myerson classification).

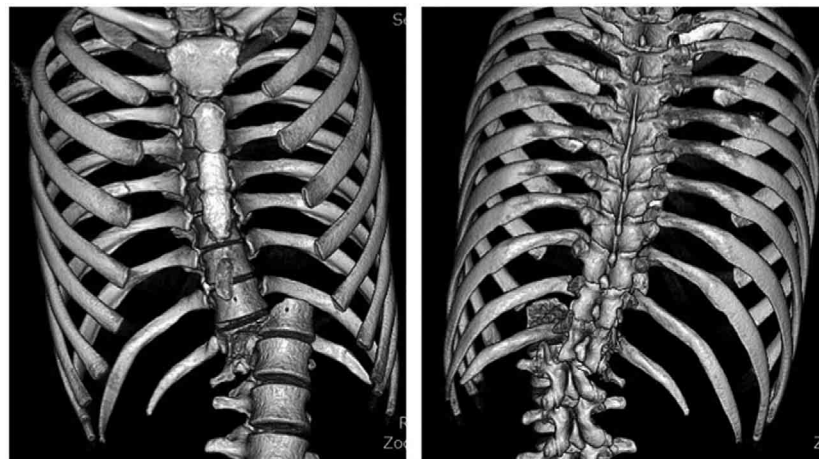


Figure 2

Three-dimensional thoracolumbar CT images showing fracture-dislocation of the T12 vertebral body. The fracture line running from the antero-superior corner and the postero-inferior corner of the T12 vertebral body is seen. The caudal vertebral fragment has dislocated to the left side with rotation.

OPERATIVE PROCEDURE :

The operation started approximately 12 h after the accident. The operation was performed in the right lateral position on a Jackson table under somatosensory evoked potentials (SEP) monitoring to avoid neurological deterioration caused by postural changes or the surgical procedures.

An anterior approach between the left T9 and T10 ribs was used. In the left thoracic cavity, active bleeding was found from the fractured T12 vertebral body, and the injured left segmental artery of the T12 vertebra was identified. After hemostasis was achieved by ligation of the T12 segmental artery, we attempted reduction of the dislocated T12 fractured vertebral bodies by

inserting instruments into the fractured space. After we confirmed reduction of the fractured fragments using an image intensifier, we performed anterior spinal fusion of the T11-L1 vertebral bodies (Figure 5). During the operative procedure, SEP monitoring showed no significant neurological dysfunction.

POSTOPERATIVE COURSE :

The general condition of the patient improved under management in the ICU for 3 days postoperatively. Although slight numbness and disturbance of light touch (grade 8/10) remained on the anterior portion of the left thigh (L1-2 nerve root lesions), sensation in the perineum remained intact. Further, no bladder and rectal disturbances were found, and muscular strength in the

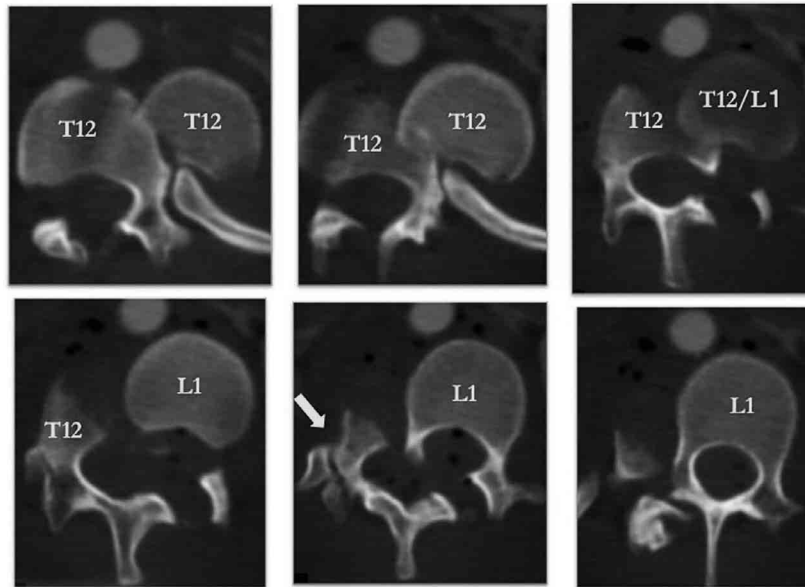


Figure 3

Plain CT axial images in thoracolumbar transition showing fracture-dislocation of the T12 vertebral body. Because of the fracture and displacement of the right superior articular process of the L1 vertebral body (yellow arrow), the spinal canal was spared completely.

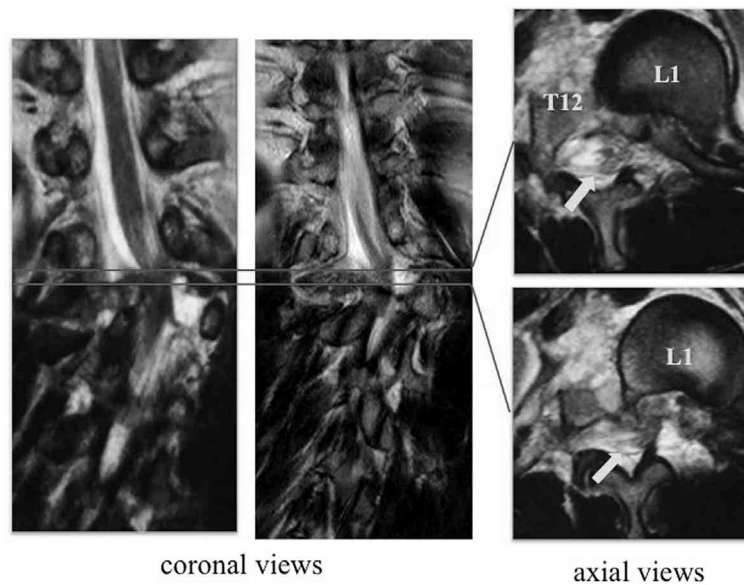


Figure 4

Magnetic resonance T2-weighted images of the thoracolumbar spine showing the continuity of the spinal cord (yellow arrows). The area of transition from the conus medullaris to the cauda equina is compressed between the T12 right lamina and L1 left pedicle in the T2-weighted images.

lower extremities recovered completely in the perioperative period. After bed rest for 6 weeks, the patient started to ambulate. At 4 months postoperatively, he could walk independently and was discharged. Although he complained of slight back pain, CT scans revealed bony union of the T12 vertebral body at 6 months postoperatively (Figure 6), and the patient was able to return to regular work.

DISCUSSION

The thoracolumbar spine is the most vulnerable to spinal fractures (4). Because fracture-dislocation of the thoracolumbar spine is the most unstable type of fracture due to failure of all the three columns (5), such cases often involve severe neurological dysfunction or critical sequelae. Further, most cases need surgical intervention for decompression of the dural sac or reduction/stabilization of the affected spine (3). Since high-energy trauma is the commonest cause of fracture-dislocation of the thoracolumbar

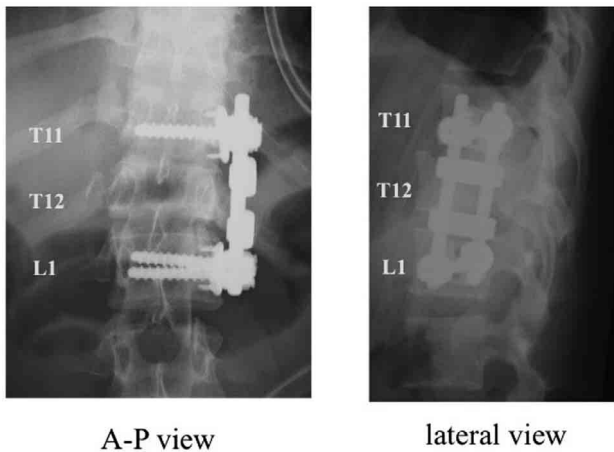


Figure 5
Postoperative plain radiographs showing reduced alignment of the thoracolumbar spine.

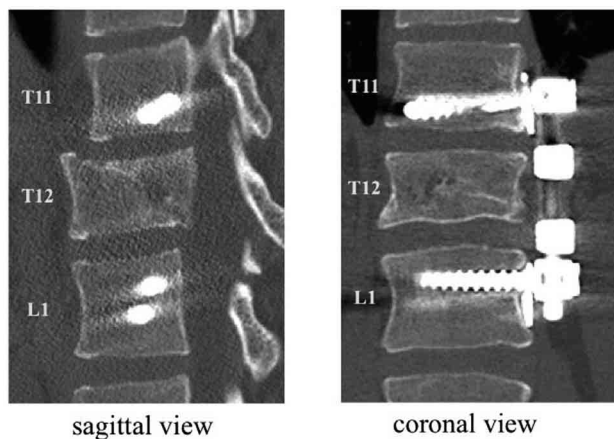


Figure 6
Postoperative plain CT images showing bony union at the 6-month follow-up.

spine. These patients also typically suffer other complications, such as pneumothorax, hemothorax, myocardial or pulmonary contusion, other fractures, great vessel injury, and/or multiple internal organ injury (4).

Although our patient suffered from complete fracture-dislocation of the thoracolumbar spine, he had no critical neurological deficits, and the only postoperative sequela was slight sensory disturbance of the left thigh, possibly due to the L1-2 nerve root injury. There are two possible reasons for the absence of critical neurological deficits. The first is spinal canal sparing due to the fracture of the middle column of the L1 vertebral body. Only a few cases with fracture-dislocation of the thoracolumbar spine without severe neurological dysfunction have been reported; some of these had middle column fractures, such as pedicle or facet fractures, which caused spinal canal sparing (6-8). Our patient had a similar right superior articular process fracture of the L1 vertebral body, which contributed to incidental thoracolumbar spinal canal sparing at the T12-L1 levels. The other reason is the type of dislocation of the thoracolumbar spine. Rotational dislocation does not involve strong shearing stress to the dural sac, compared with lateral or anteroposterior dislocation.

With regard to the operative procedure for thoracolumbar spinal fractures, most surgeons prefer posterior or combined anterior-posterior fusion for both stable and unstable fractures (9-11). In the present case, we performed anterior fusion for achieving hemostasis in the thoracic cavity as well as for reduction and stabilization of the spinal column. Therefore, we planned a two-stage surgery, with anterior spinal fusion as the primary surgery and posterior spinal fusion as additional surgery if stability of the bone fragments was not achieved or back pain due to the non-union of the T12 vertebral body persisted postoperatively. Fortunately, at 6 months postoperatively, plain thoracolumbar CT scans revealed bony union of the T12 vertebral body and no additional surgery was required.

CONCLUSION

We have presented a rare case of complete fracture-dislocation of the thoracolumbar spine with no critical neurological deficit. The most plausible reasons for the absence of such neurological deficit are spinal canal sparing caused by a fracture of the superior articular process of the T12 vertebral body and rotational dislocation with mild to moderate shearing stress to the dural sac.

CONFLICTS OF INTEREST

The authors declare that there are no conflicts of interest in relation to the article.

REFERENCES

- Vaccaro AR, Oner C, Kepler CK, Dvorak M, Schnake K, Bellabarba C, Reinhold M, Aarabi B, Kandziora F, Chapman J, Shanmuganathan R, Fehlings M, Vialle L : AOSpine Spinal Cord Injury & Trauma Knowledge Forum. AOSpine thoracolumbar spine injury classification system : fracture description, neurological status, and key modifiers. *Spine* 38 (23) : 2028-2037, 2013
- Aebi M : Classification of thoracolumbar fracture and dislocations. *Eur Spine J* 19(Suppl 1) : S2-7, 2010
- Wang F, Zhu Y : Treatment of complete fracture-dislocation of thoracolumbar spine. *J Spinal Disord Tech* 26(8) : 421-426, 2013
- Wood KB, Li W, Lebl DR, Ploumis A : Management of thoracolumbar spine fractures. *Spine J* 14(1) : 145-164, 2014
- Dennis F : The three column spine and its significance in the classification of acute thoracolumbar spinal injuries. *Spine* 8 (8) : 817-831, 1983
- Akay KM, Baysefer A, Kayali H, Beduk A, Timurkaynak E : Fracture and lateral dislocation of the T12-L1 vertebrae without neurological deficit. *Neurol Med Chir (Tokyo)* 43(5) : 267-270, 2003
- Hsieh CT, Chen GJ, Wu CC, Su YH : Complete fracture-dislocation of the thoracolumbar spine without paraplegia. *Am J Emerg Med* 26(5) : 633.e5-633.e7, 2008
- Evans LJ : Image in clinical medicine. Thoracolumbar fracture with preservation of neurologic function. *N Engl J Med* 367(20) : 1939, 2012
- Oskouian RJ Jr., Shaffrey CI, Withhill R, Sausur CA, Pouratian N, Kanter AS, Asthagiri AR, Dumont AS, Sheehan JP, Elias WJ, Shaffrey ME : Anterior stabilization of three-column thoracolumbar spinal trauma. *J Neurosurg Spine* 5(1) : 18-25, 2006
- Wood KB, Bohn D, Mehbod A : Anterior versus posterior

treatment of stable thoracolumbar burst fractures without neurologic deficit. a prospective, randomized study. *J Spinal Disord Tech* 18 : S15-S23, 2005

11. Masuda T, Miyamoto K, Wakahara K, Matsumoto K, Hioki A,

Shimokawa T, Shimizu K, Ogura S, Akiyama H : Clinical Outcomes of Surgical Treatments for Traumatic Spinal Injuries due to Snowboarding. *Asian Spine J* 9(1) : 90-98, 2015