

## REVIEW

# The state of the art in arthroscopic hip surgery

Tomohiro Goto, Daisuke Hamada, Kazuaki Mineta, Ichiro Tonogai, Hiroshi Egawa, Tetsuya Matsuura, Mitsuhiko Takahashi, Kousaku Higashino, Toshinori Sakai, Naoto Suzue, Yoichiro Takata, Toshihiko Nishisho, Yuichiro Goda, Ryousuke Sato, Fumitake Tezuka, Kenji Kondo, Makoto Takeuchi, Kousuke Sugiura, and Koichi Sairyo

*Department of Orthopedics, Institute of Health Biosciences, the University of Tokushima Graduate School, Tokushima, Japan*

**Abstract :** Hip arthroscopy is among the most rapidly evolving arthroscopic techniques in the last decade and offers the benefits of being both a minimally invasive procedure and an excellent diagnostic tool. Improvements in instrumentation and surgical skills have advanced our ability to accurately diagnose and treat various conditions of the hip joint, and hip arthroscopy has elucidated several pathologies that cause disabling symptoms. Many of these conditions were previously unrecognized and left untreated. The indications for hip arthroscopy include the management of early osteoarthritis, synovial disorders (e.g., synovial osteochondromatosis), labral tears, chondral lesions, and femoroacetabular impingement (FAI), which is increasingly recognized as a disorder that can lead to the development of early cartilage and labral injury. A better understanding of hip arthroscopy, including the anatomy, improved surgical techniques, indications, and complications of the procedure, is essential for its success. This review article discusses the state of the art of arthroscopic hip surgery. *J. Med. Invest.* 61 : 226-232, August, 2014

**Keywords :** *hip arthroscopy, minimally invasive surgery, femoroacetabular impingement, labral tear*

## INTRODUCTION

Diagnosis and treatment of the hip joint is one of the latest frontiers in arthroscopy. The unique anatomy of the hip, its strong thick capsule and ball-and-socket constrained architecture, and the dense soft tissue around the joint, are all challenges for the hip arthroscopist and has slowed advances in hip arthroscopy. Hip arthroscopy is becoming a useful tool for the diagnosis and management of both intra- and extra-articular hip pathologies because

of advances in the technologies and techniques of arthroscopy, including endoscopic instruments (1). As a minimally invasive procedure, it has several advantages, including relatively short rehabilitation and few complications. It has also provided opportunities to identify previously unrecognized pathologies as well as manage subtle causes of hip pain such as labral injuries. There are several indications for hip arthroscopy including intra-articular lesions, such as labral tears, chondral lesions, femoroacetabular impingement (FAI), and synovial diseases, and extra-articular lesions, like snapping hips and bursitis. The indications continue to expand, but it should be emphasized that arthroscopy is not the solution for all forms of hip disease.

Received for publication March 7, 2014 ; accepted March 31, 2014.

Address correspondence and reprint requests to Koichi Sairyo, M.D., Ph.D., Department of Orthopedics, Institute of Health Biosciences, the University of Tokushima Graduate School, 3-18-15 Kuramoto, Tokushima 770-8503, Japan and Fax : +81-88-633-0178.

## HISTORY OF HIP ARTHROSCOPY

Hip arthroscopy was first introduced by Burman in 1931 (2). He used a specifically designed 4 mm scope to evaluate 20 cadaveric hip joints without distraction. He noted that visualization was limited to the articular surface of the femoral head and the intracapsular neck of the femur, what is now known as the peripheral compartment. This meant that the articular surface of the acetabulum, the acetabular fossa, and the ligamentum teres, the so-called central compartment, were not visualized. Two of the most significant anatomic challenges in accessing the central compartment are, first, the femoral head, which is convex and deeply recessed in the bony acetabulum and, second, the thick fibrocapsular and muscular envelope around the hip joint, which decreases the distension permissible during hip arthroscopy. After Burman's report, hip arthroscopy remained relatively obscure for around 50 years. It was only after Eriksson, in the early 1980s, evaluated and measured the distension of the hip capsule and the distraction force necessary to adequately visualize the hip joint (3, 4) that, using traction, the techniques of hip arthroscopy developed more rapidly. The development of specialized equipment in the 1990s and early 2000s, coupled with improved surgical techniques and a better understanding of pathology, has led to an increase in the number of surgeons performing hip arthroscopy. Glick and colleagues (5, 6) have described lateral decubitus positioning and peritrochanteric portal placement, and Byrd (7, 8) has provided numerous technical suggestions for hip arthroscopy in the supine position. The recent advances in equipment for hip arthroscopy, especially the oblique-viewing endoscope and flexible instruments specifically designed for the hip, have led to improved safety, visualization, and accessibility of the hip joint.

## SURGICAL TECHNIQUES

After induction of general anesthesia, the patient is placed in the supine position. The hip joint is abducted by 10 degrees, and the lower extremity is internal rotated by 15 degrees and fixed to the fracture table. For operations on the central compartment, the hip joint is distracted so that the joint widens to around 8 to 10 mm while being monitored by a radiographic image intensifier (Fig. 1). First the anterolateral portal is positioned over the

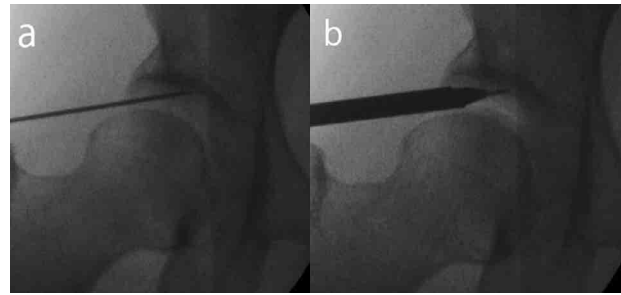
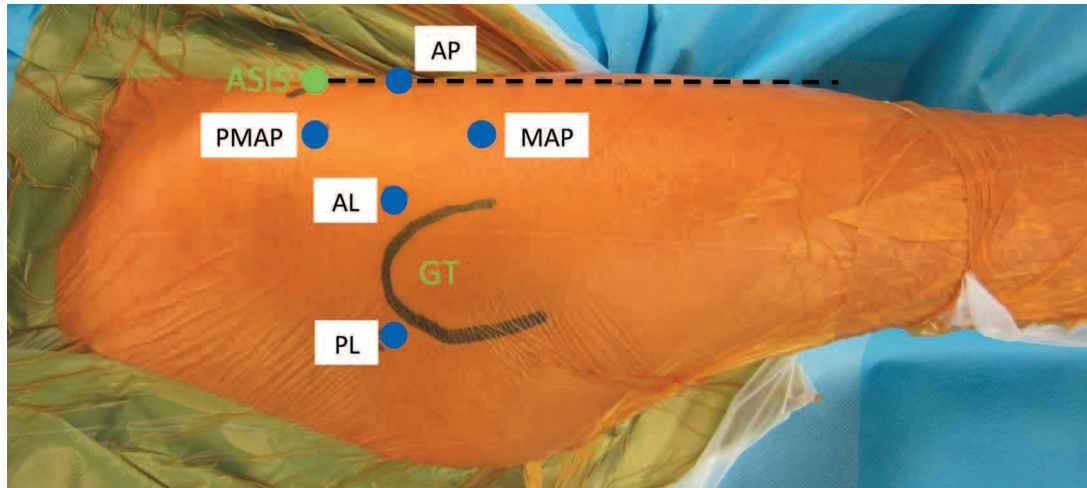


Figure 1. A fluoroscopic image under traction. The joint space is widened to around 8 to 10 mm (A) so that the arthroscope can pass into the hip joint (B).

superior and anterior border of the great trochanter (Fig. 2). While monitoring with the image intensifier, the surgeon inserts a 15-gauge spinal needle into the hip joint and injects 30 mL of normal saline. A metallic guide wire is inserted into the guide needle and the guide needle is removed. A trocar is inserted over the metallic guidewire to enlarge the anterolateral portal, and a 5.5 mm arthroscope can then be passed over the guidewire into the joint. A 70-degree arthroscope is usually used for viewing the hip joint and then other portals are made under direct vision. Historically, 3 standard portals (anterior, anterolateral, and posterolateral) have been used to access the hip joint (Fig. 2). As hip arthroscopic procedures become more complex, more portals may be needed to provide appropriate access. We usually use 2 additional portals, a mid-anterior portal and a proximal mid-anterior portal, which are useful to access the peripheral compartment to perform osteochondroplasty for cam-type femoroacetabular impingement and the peritrochanteric space to treat trochanteric bursitis or external snapping hip (Fig. 2). Saline is infused under a pressure of 50-60 mmHg (up to 100 mmHg) to assist with capsular distension during surgery. An intra-articular diagnostic sweep is usually performed prior to the treatment of any identified pathology. Use of flexible instruments allows a wide variety of procedures to be performed in the joint.

Techniques for extensile arthroscopic capsulotomy are useful for improving controllability and peripheral compartment exposure but they should be done with caution to avoid injuring the retinacular artery and creating iatrogenic instability. If an extensile capsulotomy has been performed, the incised capsule is anatomically repaired to restore the tension and stability of the iliofemoral ligament.



**Figure 2.** A photograph of the right hip showing skin entry sites for the major hip arthroscopic portals. The greater trochanter and anterior superior iliac spine (ASIS) are outlined. Line A is drawn down the anterior thigh from the ASIS. AL and PL are placed 1 cm superior and 1 cm anterior or posterior to the tip of the greater trochanter, respectively. AP is placed 1 cm lateral to the line A at the same level as AL. AP, AL, and MAP form an equilateral triangle to the distal and AP, AL, and PMAP form an equilateral triangle to the proximal. AP : anterior portal, AL : anterolateral portal, PL : posterolateral portal, MAP : mid-anterior portal, PMAP : proximal mid-anterior portal

## SURGICAL INDICATIONS

### 1. Acetabular labral injury

The acetabular labrum is a fibrocartilage structure surrounding the acetabular rim and it functions to provide stability, maintain the suction seal, regulate synovial fluid, and assist in force distribution for load bearing (9, 10). When a labral tear occurs, the stability of the hip joint is diminished, the rate of acetabular cartilage compression is increased, and the contact stress between the femoral and acetabular cartilage will also be increased (11). If the tear is left untreated, it will alter normal hip joint function and may eventually lead to osteoarthritis. Acetabular labral tears commonly occur in the anterosuperior quadrant of the labrum.

The goal of arthroscopic treatment of the torn labrum is to relieve pain by eliminating the unstable flap tears that cause subtle symptoms in the hip. The decision of whether to resect or restore the torn labrum is based on the quality of the labral tissue and blood supply. Most of the blood supply to the labrum comes from the capsular side, whereas the articular side has less vascularity and limited synovial covering (12). It is important to accurately define the margin of the labral lesion during the initial arthroscopic examination : labral preservation is important because labral repair is associated with less progression of degenerative change in the hip, so resection of the labrum should be minimized. The case shown in Figure 3, where the labrum is detached from the bone and is flapping in the joint

space, is a good indication for repair (Fig. 3a). Bio-absorbable suture anchors are placed on the rim of the acetabulum and the suture materials are passed through the split in the labrum. The suture is tied down using sliding knot techniques (Fig. 3b).

Isolated treatment of labral tears without addressing the underlying causative factor will result in poor outcome. Associated causative factors such as bony deformities in FAI or developmental dysplasia of the hip (DDH) must be identified preoperatively and treated appropriately at the time of surgery.

### 2. Chondral injury

Chondral injuries of the femoral head and acetabulum are often elusive sources of hip pain (7). Traditionally, most chondral injuries involve labral tears, FAI, DDH, and osteoarthritis. However, acute isolated traumatic chondral injuries can occur as the result of impact loading over the greater trochanter, so-called lateral impact injury. This usually occurs in young adult men during sports activities. The high bone density of the hip allows impact on this area to transfer load to the joint surface, resulting in chondral lesions without associated osseous injury (13).

### 3. Femoroacetabular impingement

Ganz (14) first introduced the concept of FAI as a dynamic cause for osteoarthritis of the hip. Impingement within the hip joint is a mechanical conflict between the femur and acetabulum. Two distinct type of FAI have been described, pincer and

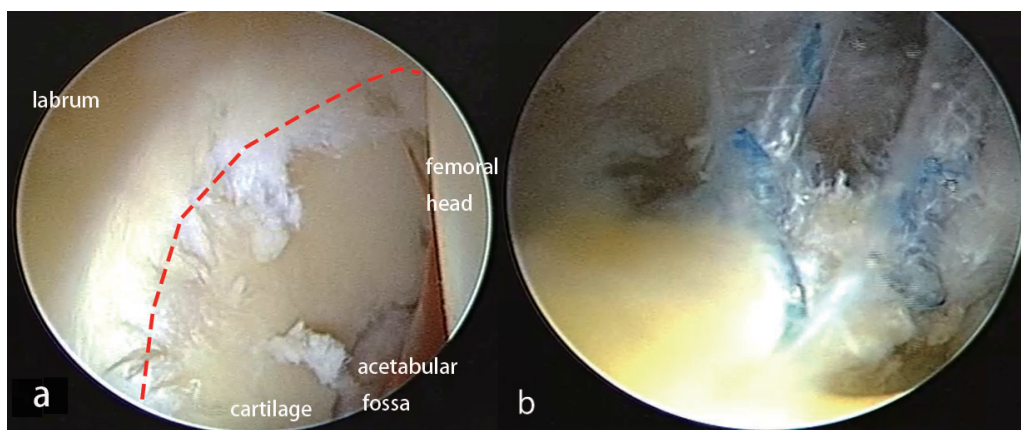


Figure 3. Arthroscopic labral repair. The labrum is detached off the bony acetabulum. A dotted line shows the boundary between labrum and acetabular cartilage (a). A repaired labrum suture affixed to the acetabular rim (b).

cam. Pincer impingement involves abnormal morphology of the acetabulum such as focal or global acetabular over-coverage. Cam impingement is the result of contact between an abnormally shaped femoral head-neck junction and acetabulum during hip flexion and internal rotation. These anatomical abnormalities of the proximal part of the femur and acetabulum result in repetitive abutment during dynamic hip motion, which leads to abnormal loading of the femoral head-neck junction against the acetabular rim and precipitates labral and chondral injuries (14, 15). These injuries are commonly localized to the anterosuperior region of the acetabular rim. The severity of these injuries usually depends on the duration of non-treatment, suggesting the importance of early diagnosis and treatment.

For preoperative diagnosis, some morphological indicators of FAI has been reported, such as alpha angle, center-edge angle, acetabular retroversion, coxa profunda, herniation pit, and so on. But the etiology of these morphological features remains controversial and not fully defined. While FAI is widely noticed to be a cause of early primary osteoarthritis of the hip, the etiology of hip OA is much different in each ethnic. The prevalence of primary hip OA has been found to be much higher in Caucasian than in Japanese population. Thus, there is possibility that FAI may have a little contribution to the cause of OA in Japanese population. We previously reported about the morphology associated with FAI in Japanese (16). Further consideration is needed about a comprehensive knowledge of hip anatomy in each ethnic to elucidate the exact etiology of FAI.

The goal of surgical treatment is to eliminate impingement between the femoral head-neck junction and the acetabular rim by osteochondroplasty of the

femoral head (Fig. 4a, b) and/or removing the excessive bone of the acetabular rim (Fig. 4d, c).

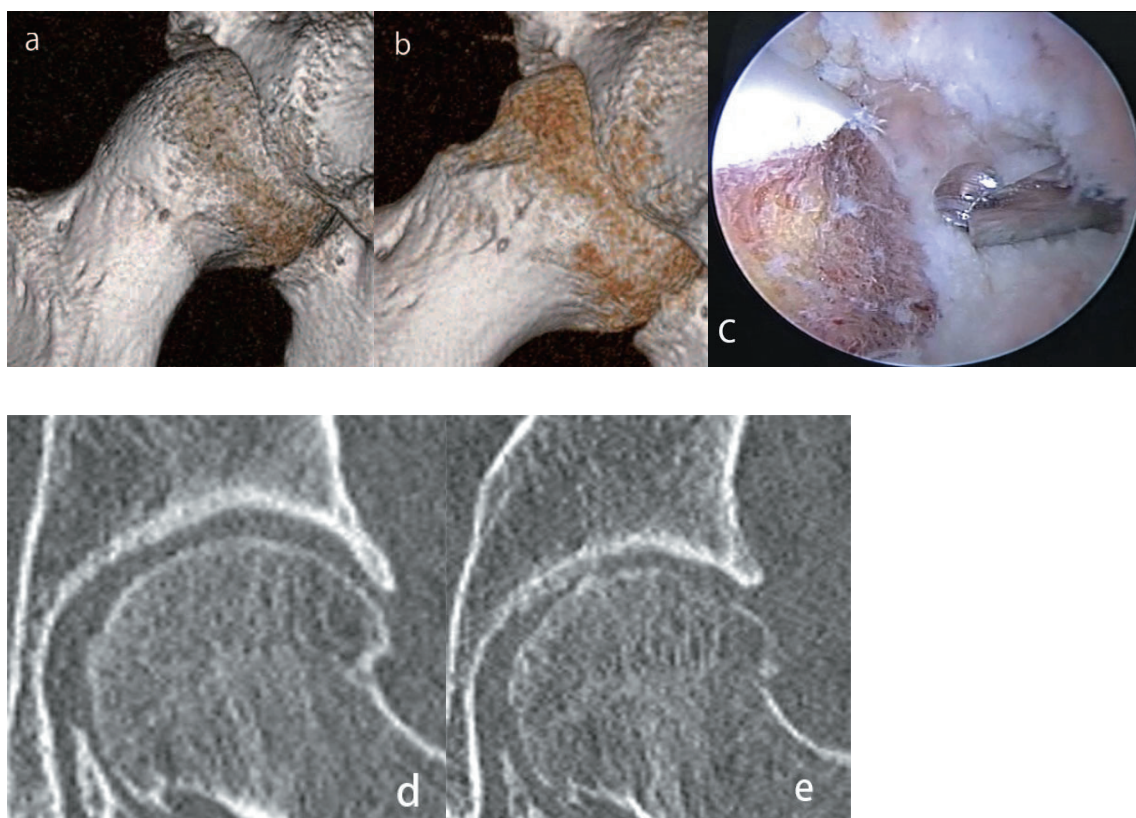
#### 4. Developmental dysplasia of the hip

DDH is the most common cause of secondary osteoarthritis in young adults and is more frequently encountered in women and in certain ethnic groups such as Japanese (17). The role of hip arthroscopy in adult DDH has not been well defined. In cases of pre-arthritis DDH, relatively high rates of acetabular chondral and labral lesions in the anterosuperior region are reported as arthroscopic findings (18). Byrd (19) reported that labral debridement could provide symptomatic relief, whereas others have reported cases of accelerated arthritis and instability following hip arthroscopy (20). Labral refixation may be reasonable in cases of subtle symptomatic dysplasia, but extensive debridement with capsulotomy may result in iatrogenic instability and dysfunction. When performing hip arthroscopy for DDH, the importance of capsular plication and repair should be kept in mind. Currently, arthroscopic surgery for significant DDH should be accompanied by some definitive treatment such as periacetabular osteotomy of the underlying primary mechanical problem.

#### 5. Osteoarthritis

Osteoarthritis is a non-inflammatory degenerative joint disorder associated with cartilage degeneration and bony deformity. It is the most common disease of the hip joint in adults. At present, the role of arthroscopy in the treatment of osteoarthritis of the hip is controversial and needs to be better defined. However, the indication for total hip arthroplasty for end-stage osteoarthritis is widely



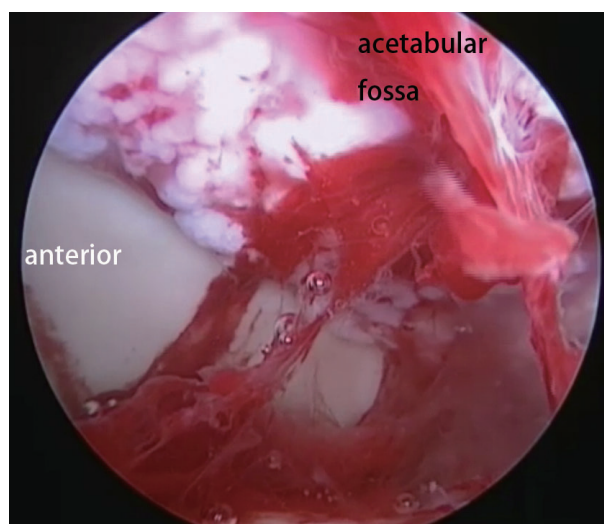


**Figure 4.** Preoperative (a) and postoperative (b) computed tomography (CT) images reveal improved head-neck offset. Intraoperative arthroscopic photograph shows osteochondroplasty of the femoral head (c). CT coronal images show the acetabular over-coverage preoperatively (d) and that appropriate arthroscopic acetabular rim resection postoperatively (e).

accepted. McCarthy (21) reported that debriding osteophytes or a degenerative labrum could help improve mechanical symptoms in patients with early osteoarthritis. On the other hand, Walton (22) reported that osteoarthritic patients were found to have significantly worse outcomes. The results of systematic reviews reported significantly poorer clinical outcomes in degenerative hip joints (23, 24). Preoperative radiographic joint space narrowing  $> 50\%$  or intraoperative severe cartilage lesions could be high risks for total hip arthroplasty within a few years of hip arthroscopic surgery (25, 26). The conduction of hip arthroscopy for osteoarthritis needs stricter criteria. The presence of any joint space narrowing in preoperative radiographic management should be approached with considerable caution.

#### 6. Synovial osteochondromatosis

Synovial osteochondromatosis is a benign tumor that results in monoarticular arthropathy. It is well known in the knee and elbow joints but is relatively uncommon in the hip. Synovial osteochondromatosis has been described as cartilaginous metaplasia that can result in formation of multiple loose bodies and clusters (Fig. 5). When it involves the hip joint,



**Figure 5.** Intraoperative arthroscopic view from posterior portal shows clusters of loose bodies in synovial osteochondromatosis at acetabular fossa.

there are usually long delays in diagnosis and treatment because of its insidious clinical presentation and poor diagnosis rate on imaging studies (27). Magnetic resonance imaging (MRI) and computed tomographic arthrography are useful for detecting osteochondral lesions in the hip joint. Though MRI

might obscure intra-articular fragments, it can show multiple intra-articular filling defects. It is essential to fully explore inside the joint and be sure to remove all fragments.

## COMPLICATIONS

Arthroscopic surgery of the hip is a relatively safe procedure, with a complication rate lower than that of other open surgeries. The incidence of complications reported after hip arthroscopic surgery is between 0.5% and 6.4% and the majority of complications are transient (28-30). The most common class of complications of hip arthroscopy is traction-related injury, which includes neurapraxia of the peroneal, femoral, sciatic, lateral femoral cutaneous, and pudendal nerves. Other related complications are associated with the compressive force, usually exerted by the perineal post used for countertraction. These injuries occur in the area of the groin, and range from edema and hematoma to pressure necrosis (4, 5). They are usually associated with prolonged procedures or the use of excessive traction force. Martin (31) suggested that continuous traction should not exceed 2 h, with intermittent traction used in prolonged surgeries and the force limited in general to 50 lbs. Other common intra-operative complications are iatrogenic chondral injuries like scuffing of the articular surface by canulae or the arthroscope. This complication may be reduced by meticulous surgical technique and placement of secondary portals under direct visualization.

There have been reports of direct damage to the lateral cutaneous nerve or sciatic nerve during the creation of portal sites (32). Additionally, fluid extravasation into the intrapelvic spaces has occurred with prolonged operative times or extra-articular surgery, for example, to remove loose bodies or release the iliopsoas tendon. This complication needs special attention during surgery because it can be fatal due to abdominal compartment syndrome (33). Some rare complications such as osteonecrosis, postoperative dislocation of the femoral head, and femoral neck fractures have been described in case reports (34-36).

## CONCLUSION

Hip arthroscopy has evolved tremendously in the last decade. Advances in hip arthroscopic techniques

have improved the diagnosis and treatment of intra-articular hip problems that were previously unrecognized, and improvements in technology have made the procedure accessible and reproducible. The indications for hip arthroscopy are therefore continuing to grow. Improved clinical correlations of symptoms to pathology will influence the evolution of endoscopic techniques for better management of hip conditions. However, a careful physical examination and radiographic assessment are critical to define strict surgical indications that reproducibly achieve favorable clinical outcomes.

## REFERENCES

1. Kelly BT, Buly RL : Hip arthroscopy update. *HSS J* 1 : 40-48, 2005
2. Burman MS : Arthroscopy or the direct visualization of joints : an experimental cadaver study. *1931. Clinical orthopaedics and related research* 390 : 5-9, 2001
3. Eriksson E, Sebik A : Arthroscopy and arthroscopic surgery in a gas versus a fluid medium. *Orthop Clin North Am* 13 : 293-298, 1982
4. Eriksson E, Arvidsson I, Arvidsson H : Diagnostic and operative arthroscopy of the hip. *Orthopedics* 9 : 169-176, 1986
5. Glick JM, Sampson TG, Gordon RB, Behr JT, Schmidt E : Hip arthroscopy by the lateral approach. *Arthroscopy* 3 : 4-12, 1987
6. Glick JM : Hip arthroscopy. The lateral approach. *Clin Sports Med* 20 : 733-747, 2001
7. Byrd JW : Hip arthroscopy. The supine position. *Clin Sports Med* 20 : 703-731, 2001
8. Byrd JW, Jones KS : Hip arthroscopy in athletes. *Clin Sports Med* 20 : 749-761, 2001
9. Ferguson SJ, Bryant JT, Ganz R, Ito K : An in vitro investigation of the acetabular labral seal in hip joint mechanics. *Journal of Biomechanics* 36 : 171-178, 2003
10. Ferguson SJ, Bryant JT, Ito K : The material properties of the bovine acetabular labrum. *J Orthop Res* 19 : 887-896, 2001
11. Crawford MJ, Dy CJ, Alexander JW, Thompson M, Schroder SJ, Vega CE, Patel RV, Miller AR, McCarthy JC, Lowe WR, Noble PC : The 2007 Frank Stinchfield Award. The biomechanics of the hip labrum and the stability of the hip. *Clin Orthop Relat Res* 465 : 16-22, 2007
12. Kelly BT, Shapiro GS, Digiovanni CW, Buly RL, Potter HG, Hannafin JA : Vascularity of the hip

- labrum : a cadaveric investigation. *Arthroscopy* 21 : 3-11, 2005
13. Byrd JW : Lateral impact injury. A source of occult hip pathology. *Clin Sports Med* 20 : 801-815, 2001
  14. Ganz R, Parvizi J, Beck M, Leunig M, Nötzli H, Siebenrock KA : Femoroacetabular impingement : a cause for osteoarthritis of the hip. *Clin Orthop Relat Res* 417 : 112-120, 2003
  15. Khanduja V, Villar RN : Arthroscopic surgery of the hip : current concepts and recent advances. *J Bone Joint Surg Br* 88 : 1557-1566, 2006
  16. Goto T, Takasago T, Egawa H, Yasui N : CT analysis of the herniation pits in Japanese asymptomatic subjects. *Hip Joint* 39 : 371-373, 2013 (article in Japanese)
  17. Hoaglund FT, Shiba R, Newberg AH, Leung KY : Diseases of the hip. A comparative study of Japanese Oriental and American white patients. *J Bone Joint Surg Am* 67 : 1376-1383, 1985
  18. Fujii M, Nakashima Y, Jingushi S, Yamamoto T, Noguchi Y, Suenaga E, Iwamoto Y : Intra-articular findings in symptomatic developmental dysplasia of the hip. *J Pediatr Orthop* 29 : 9-13, 2009
  19. Byrd JWT, Jones KS : Hip arthroscopy in the presence of dysplasia. *Arthroscopy* 19 : 1055-1060, 2003
  20. Benali Y, Katthagen BD : Hip subluxation as a complication of arthroscopic debridement. *Arthroscopy* 25 : 405-407, 2009
  21. McCarthy JC, Lee J-A : Arthroscopic intervention in early hip disease. *Clin Orthop Relat Res* 429 : 157-162, 2004
  22. Walton NP, Jahromi I, Lewis PL : Chondral degeneration and therapeutic hip arthroscopy. *Int Orthop* 28 : 354-356, 2004
  23. Clohisy JC, St John LC, Schutz AL : Surgical treatment of femoroacetabular impingement : a systematic review of the literature. *Clin Orthop Relat Res* 468 : 555-564, 2010
  24. Ng VY, Arora N, Best TM, Pan X, Ellis TJ : Efficacy of surgery for femoroacetabular impingement : a systematic review. *Am J Sports Med* 38 : 2337-2345, 2010
  25. Philippon MJ, Briggs KK, Yen Y-M, Kuppersmith DA : Outcomes following hip arthroscopy for femoroacetabular impingement with associated chondrolabral dysfunction : minimum two-year follow-up. *J Bone Joint Surg Br* 91 : 16-23, 2009
  26. Larson CM, Giveans MR, Taylor M : Does arthroscopic FAI correction improve function with radiographic arthritis? *Clin Orthop Relat Res* 469 : 1667-1676, 2011
  27. McCarthy JC, Lee J : Hip arthroscopy : indications and technical pearls. *Clin Orthop Relat Res* 441 : 180-187, 2005
  28. Griffin DR, Villar RN : Complications of arthroscopy of the hip. *J Bone Joint Surg Br* 81 : 604-606, 1999
  29. Sampson TG : Complications of hip arthroscopy. *Clin Sports Med* 20 : 831-835, 2001
  30. Clarke MT, Arora A, Villar RN : Hip arthroscopy : complications in 1054 cases. *Clin Orthop Relat Res* 406 : 84-88, 2003
  31. Martin HD, Palmer IJ, Champlin K, Kaiser B, Kelly B, Leunig M : Physiological changes as a result of hip arthroscopy performed with traction. *Arthroscopy* 28 : 1365-1372, 2012
  32. Frich LH, Lauritzen J, Juhl M : Arthroscopy in diagnosis and treatment of hip disorders. *Orthopedics* 12 : 389-392, 1989
  33. Ladner B, Nester K, Cascio B : Abdominal fluid extravasation during hip arthroscopy. *Arthroscopy* 26 : 131-135, 2010
  34. Matsuda DK : Acute iatrogenic dislocation following hip impingement arthroscopic surgery. *Arthroscopy* 25 : 400-404, 2009
  35. Ayeni OR, Bedi A, Lorich DG, Kelly BT : Femoral neck fracture after arthroscopic management of femoroacetabular impingement : a case report. *J Bone Joint Surg Am* 93 : e47, 2011
  36. Scher DL, Belmont PJ, Owens BD : Case report : Osteonecrosis of the femoral head after hip arthroscopy. *Clin Orthop Relat Res* 468 : 3121-3125, 2010