

ORIGINAL**Efficacy of the Quickert procedure for involutional entropion : the first case series in Asia**

Tatsuro Miyamoto¹⁾, Hiroshi Eguchi¹⁾, Takashi Katome¹⁾, Toshihiko Nagasawa¹⁾, Yoshinori Mitamura¹⁾, Geoffrey Crawford, FRANZCO, FRACS²⁾

¹⁾Department of Ophthalmology, Institute of Health Biosciences, the University of Tokushima Graduate School, Tokushima, Japan ; and ²⁾Centre for Ophthalmology and Visual Science, University of Western Australia and the Lions Eye Institute, Western Australia, Australia

Abstract : Purpose : To report the efficacy of the Quickert procedure in the first case series of involutional entropion in an elderly Asian population, and to introduce the technique to Asian ophthalmologists including general ophthalmologists and ophthalmic trainees. **Methods :** We conducted a retrospective review of 13 consecutive patients underwent the Quickert procedure for involutional entropion by occasional eyelid surgeons at Tokushima University Hospital or Mino Tanaka Hospital from September 2003 to April 2010. **Demographic data, including gender, age, history of previous eyelid surgery, systemic disease, recurrence of entropion, postoperative complications, and symptoms were analyzed. Results :** There were 5 male (38.5%) and 8 female (61.5%) subjects with a mean age of 77.8 years. Three patients underwent previous surgery for entropion were included. Entropion was rectified in all patients by a single Quickert procedure, and no recurrence was observed for a maximum of 89 months after the surgery. Although notching of the eyelid margin and mild symblepharon were observed in one patient, no symptoms associated with these complications were reported. **Conclusion :** The Quickert procedure can be one of the surgical procedures of choice for involutional entropion and should be common surgical approach for occasional eyelid surgeons in Asia as well as in western countries. *J. Med. Invest.* 59 : 136-142, February, 2012

Keywords : *the Quickert procedure, involutional entropion, occasional eyelid surgeon*

INTRODUCTION

Involutional entropion is a condition in the elderly population in which the eyelid margin is turned in against the globe with the eyelid margin and touching the cornea. It is a common lower eyelid

malposition encountered by most ophthalmologists, including ophthalmic practitioners or trainees who do not specialise in oculoplastic surgery, in outpatient clinics. When left untreated, this condition can cause ocular discomfort, several corneal disorders, and ocular inflammations that may be associated with visual disturbance. Surgical treatment should be considered if there are persistent symptoms and changes to the ocular surface.

The underlying pathogenesis of involutional entropion is thought to be due to 4 factors : 1. horizontal eyelid laxity, 2. vertical eyelid laxity with

Received for publication November 14, 2011 ; accepted December 19, 2011.

Address correspondence and reprint requests to Hiroshi Eguchi, M.D., Ph.D., Department of Ophthalmology, Institute of Health Biosciences, the University of Tokushima Graduate School, 3-18-15, Kuramoto-cho, Tokushima 770-8503, Japan and Fax : +088-631-4848.

attenuation or disinsertion of the lower lid retractors, 3. overriding of the preseptal orbicularis oculi muscle, and 4. relative enophthalmos (1-4). Horizontal eyelid laxity is probably the main underlying factor (5), and enophthalmos has been disproved as a cause (6). Therefore, various surgical procedures that address one, two, or all of these factors have been described, and it is widely accepted that surgically addressing the causative factors is necessary to successfully correct entropion (5, 7). In terms of pre-operative examinations, horizontal eyelid laxity is estimated by the pinch test and medial canthal tendon (MCT) laxity grading by the lateral distraction test (8). However, a mild degree of horizontal eyelid laxity (clinically "undetected") predisposes to the failure of surgical correction (5); therefore, most general ophthalmologists or ophthalmic trainees find it difficult to precisely evaluate horizontal eyelid laxity and even oculoplastic specialists can overlook this condition.

Quickert described a horizontal eyelid shortening procedure that was combined with the modified Wies entropion repair method as the Quickert procedure in 1972 (9). Since it can address all the aforementioned factors causing involutional entropion and the surgical technique is relatively easy, it has become entrenched as one of the popular procedures for the treatment of involutional entropion in Western countries (4, 5, 9-11). However, to our knowledge, there are no journal articles describing the use of this technique in Asian population. If the procedure is reasonable for pathophysiologically

correcting involutional entropion, easy to perform even for occasional eyelid surgeons or ophthalmic trainees and gives good results, it should be considered for practice by Asian ophthalmologists. The aim of this article is to introduce the Quickert procedure to Asian ophthalmologists, including general ophthalmologists and ophthalmic trainees, by reporting the first case series of involutional entropion in an elderly Asian population.

PATIENTS AND METHODS

Demographic data (Table 1)

We retrospectively examined 13 consecutive elderly patients (13 lower eyelids) with involutional entropion who underwent the Quickert procedure between September 2003 and April 2010 at Tokushima University Hospital or Mino Tanaka Hospital. The mean age was 77.8 years (range, 69-86 years) at the time of surgery; 5 (38.5%) were male and 8 (61.5%) were female. Of these, 3 eyelids had previously undergone surgery to correct entropion. One patient (case 5) underwent the Jones procedure at Tokushima University Hospital a year earlier and another patient (case 12) underwent probable tarsal stripping at some practitioner of plastic surgeon. The rest (case 3) had unknown eyelid surgery three times at other hospitals by three different occasional eyelid surgeons. There were no patients with systemic connective tissue disease.

Table 1 Demographic data of the 13 cases

Case	Age	Gender	Eye	Cornea	Surgery date	Follow-up (mo)	Others
1	78	F	OD	SPK	2003/09/08	89	None
2	86	M	OD	SPK	2005/05/15	81	Anemia
3	86	F	OD	SPK	2006/11/24	51	Three surgeries *
4	81	F	OD	Erosion	2007/06/29	44	PKP
5	77	F	OD	SPK	2007/11/02	17	Jones procedure (2006/02/21**)
6	81	F	OD	SPK	2008/05/24	33	Blepharoptosis
7	76	F	OD	SPK	2008/09/09	29	Optic atrophy, Iritis
8	79	M	OD	SPK	2008/10/10	28	DSAEK, PKP, Glaucoma
9	76	M	OS	SPK	2008/11/25	27	Hepatocirrhosis, Thrombocytopenia
10	73	F	OD	SPK	2009/04/10	22	Cataract surgery, Buckling surgery
11	75	F	OD	SPK	2009/12/05	14	Conjunctivochalasis
12	75	M	OS	Erosion	2010/04/23	10	Parkinson disease, Tarsal stripping
13	69	M	OD	SPK	2010/04/27	10	Nephrosis

* : Past history of three unknown surgeries for involutional entropion

** : Date of previous operation at Tokushima University Hospital

M : Male ; F : Female ; SPK : Superficial punctate keratitis ; PKP : Penetrating keratoplasty ; DSAEK : Descemet's stripping automated endothelial keratoplasty ; mo : month.

Surgical technique

Moxifloxacin hydrochloride 0.5% (Vegamox[®], Alcon) or 0.3% gatifloxacin hydrate (Gatiflo[®], Senju) ophthalmic solutions were applied to the conjunctival sac 3 times daily for 3 days prior to surgery. After the application of 1 drop of 0.4% oxybuprocaine hydrochloride (Benoxil[®], Santen), the lower eyelid was anaesthetised with approximately 2 ml of 1% lidocaine hydrochloride and a 1 : 100,000 dilution of epinephrine (1% Xylocaine[®] Injection, AstraZeneca) subcutaneously and subconjunctively. All surgeries were performed by occasional eyelid surgeons (HE or TM), not oculoplastic specialists, according to the "Quickert procedure" (4, 9, 10).

A full-thickness vertical 5-mm incision was initially made perpendicular to the eyelid margin, starting at 5 mm from the lateral canthus, approximately one-quarter of the eyelid length. A second full-thickness eyelid incision was made horizontally from the inferior aspect of the initial incision 5 mm below the lid margin and below the tarsal plate to the inferior punctum. A third incision was made laterally from the inferior aspect of the initial incision to the lateral canthus (Fig. 1A). The medial flap

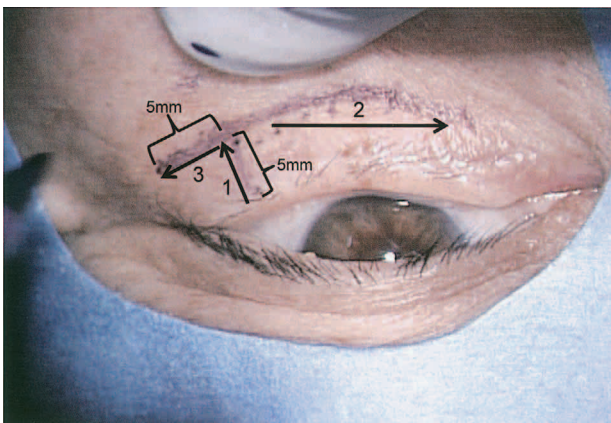


Figure 1A : Incision marked
Full-thickness eyelid incision was made.
The numbers indicate the order of the incision

of the eyelid was then folded over the lateral flap and tightened to give moderate tension. The fourth incision was made at the point marked on the medial flap vertical to the eyelid margin and carried to the inferior tarsal border where it joined the second incision (Fig. 1B). Thus, the block shape of the overlapping full-thickness eyelid was excised. The tarsal plate was approximated 2 absorbable sutures (8-0 Vicryl, Ethicon) (Fig. 1C), and the margin of

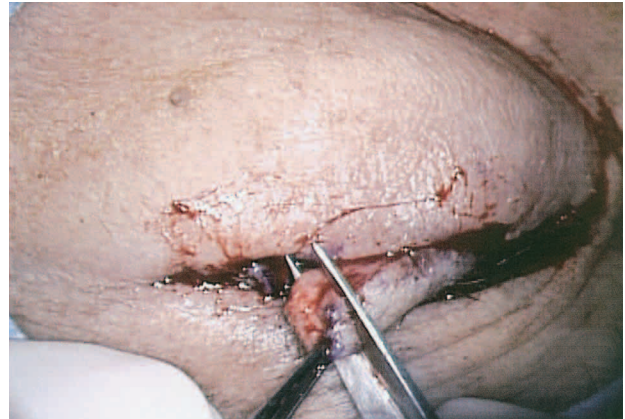


Figure 1B : Overlapping eyelid incision
Overlapping full-thickness eyelid incision was excised to correct the horizontal eyelid laxity.

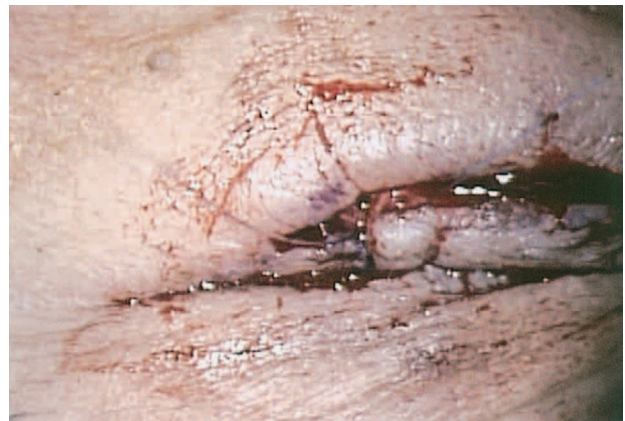

Figure 1C : Close the lid margin
The two 8-0 absorbable sutures were placed through the edge of tarsal plate close to the lid margin to avoid eyelid notching.

the eyelid flap was approximated by passing one non-absorbable 6-0 Nylon suture (Nescosuture[®], Alfresa Pharma) through the grey line. The skin margin of the approximated flap was closed using interrupted 6-0 nylon sutures. Three double armed 4-0 absorbable sutures (4-0 PDS or 4-0 Vicryl, Ethicon) were placed through the lower lid retractor layer (Fig. 1D). They were passed under the orbicularis oculi muscle anterior to the tarsal plate in the upper wound edge to emerge in the skin 2 mm inferior to the lash line. The sutures for lower lid retractor plication were placed at two points in the medial flap and at one point in the lateral flap (Fig. 1E). The double arms of the suture were placed 2-3 mm apart and tied firmly without bolsters. Finally, the skin of the second and third incisions was closed with interrupted 6-0 nylon sutures (Fig. 1F).

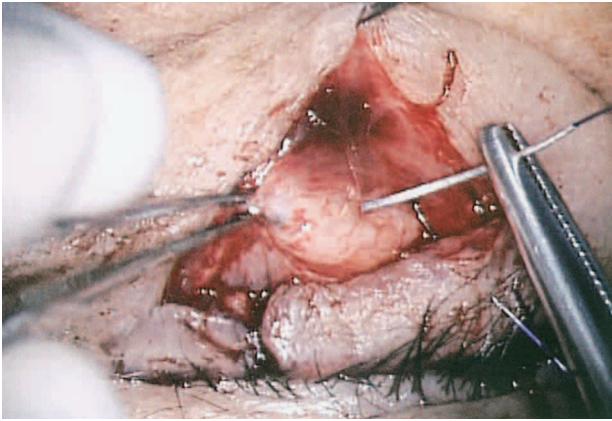


Figure 1D : The sutures through the lower lid retractor
Absorbable sutures were placed through the lower lid retractor layer.

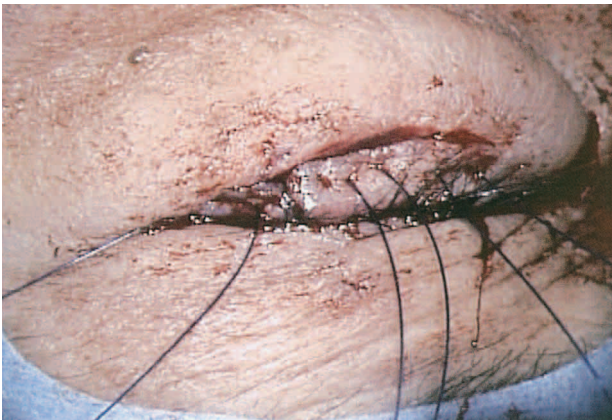

Figure 1E : Three double armed sutures
Three double armed sutures were passed under the orbicularis anterior to the tarsal plate to emerge 2 mm inferior to the lash line.

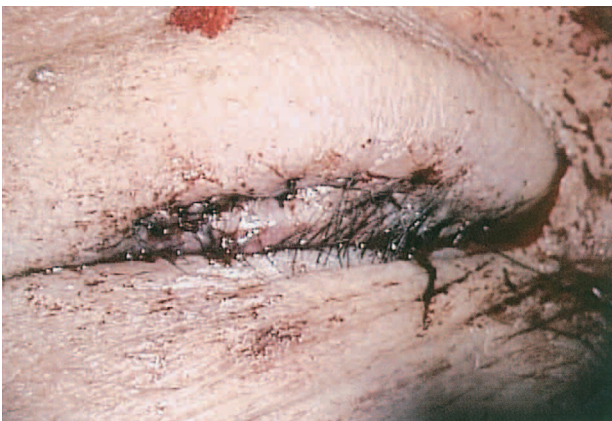

Figure 1F : Close the skins
The second and third incisions were closed with 6-0 nylon sutures.

Postoperative care

The topical antimicrobials stated above and fluorometholone (0.1% Flumetholon[®], Santen) ophthalmic solutions were applied 3 times daily for 2

weeks, and betamethasone sodium phosphate-fradiomycin sulphate (Rinderon[®]-A, Shionogi) ointment was instilled in the suture sites twice daily until suture removal. The skin sutures were removed at 7 days postoperation. The first postoperative review in the outpatient clinic was at 4-5 days after surgery. All patients were examined again for the recurrence of entropion, corneal disorders, ocular symptoms, and complications at 1, 3, 6, and 12 months postoperation as scheduled visits and once a year while they could return.

RESULTS

The follow-up period ranged from 10 to 89 months (mean, 35 months). No patient was lost to a scheduled follow-up, except one patient who died within 8 months of the surgery. Entropion was corrected in all patients by a single Quickert procedure (Figs. 2A, B), and there was no recurrence in any of the

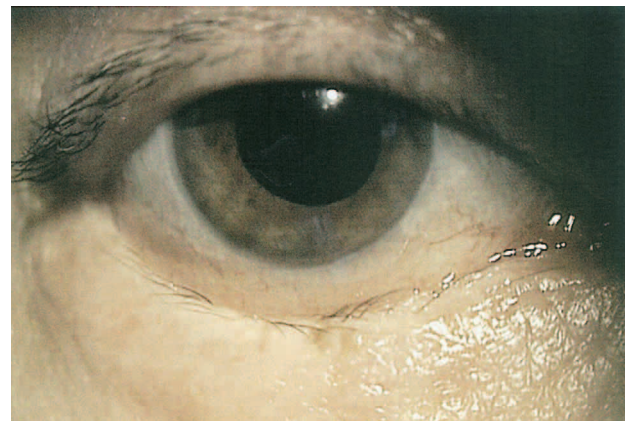


Figure 2A : Preoperative photograph
Marked entropion and cilia touching the cornea are observed.

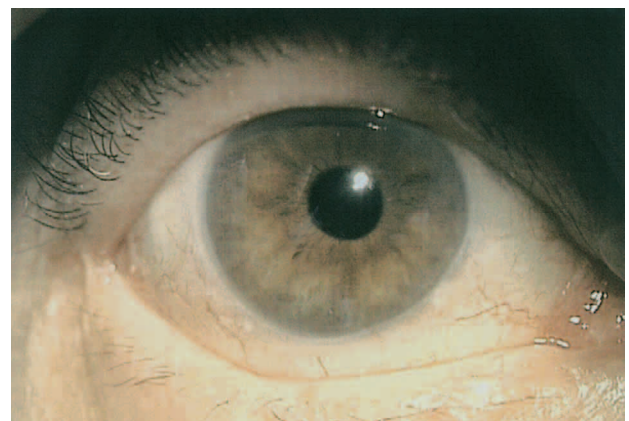

Figure 2B : Postoperative photograph
Entropion is completely rectified.

patients. Corneal disorders and ocular symptoms were decreased or had disappeared in all patients at each visit. Although mild notching of the eyelid margin and negligible symblepharon were observed in one patient (Figs. 3A, B), no symptoms associated with these complications were reported.

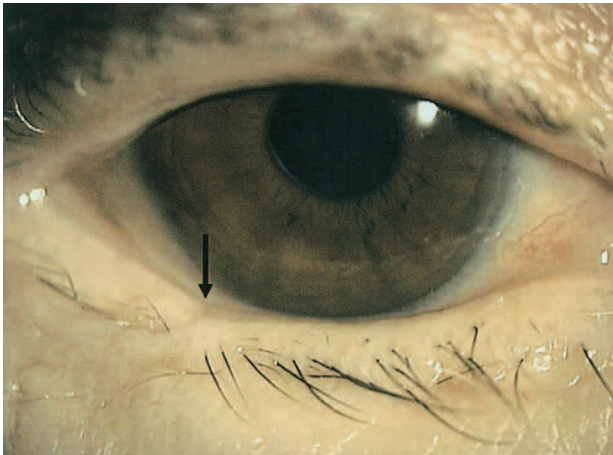

Figure 3A : Complications of the eyelid margin
Minimal notching of the eyelid margin is observed.

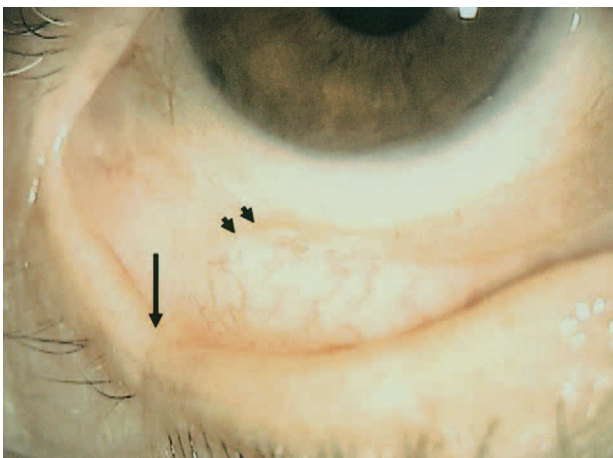


Figure 3B : Complications of the conjunctiva palpebrae
Minimal symblepharon is observed.

DISCUSSION

Involutional entropion is a more common eyelid malposition in elderly Asian populations than in non-Asians, and 11.4% of the total ophthalmic plastic surgery operations completed on Asians are for entropion repair (12). It is possible that the actual number of the elderly population with involutional entropion who visit ophthalmic practitioners and the

number of patients who require surgical treatment are higher than this reported value. In other words, it remains possible that a large number of Asian ophthalmologists, including ophthalmic practitioners and trainees who do not specialise in ophthalmic plastic surgery, are required to perform some surgical treatments for involutional entropion.

Although numerous procedures have been reported that address one, two, or all the causes of involutional entropion, there is no perfect method and all the techniques are associated with advantages and disadvantages. Moreover, the major etiological cause is still a matter of debate. Danks *et al.* speculated that horizontal laxity is probably the main underlying factor and stated that lid shortening should be performed in all primary surgeries and reoperations.⁵ In terms of horizontal laxity, it is generally rectified by the tarsal strip procedure (13) or full-thickness eyelid resection (1, 4, 5). The former procedure preserves the almond-shaped configuration of the lateral canthus while avoiding phimosis or eyelid notching (14); however, ophthalmic practitioners or trainees may be hesitant to dissect the lateral canthus deep enough to reach the periosteum of the orbital rim because most of them provide routine medical care mainly for the eyeball, or at the most, for the eyelid. The latter procedure can be easily performed by most ophthalmologists using common scissors, but it is more invasive than the former procedure and is associated with an increased probability of notching the eyelid margin.

Meanwhile, Jones *et al.* reported that vertical laxity of the eyelid is the most important cause of involutional entropion (15), and this opinion was supported by Kakizaki *et al.* who advocates the shortening of the lower lid retractor, addressing only the vertical laxity, as the first operational procedure for involutional entropion (16). Kakizaki *et al.* also stated that the looseness of the orbicularis oculi muscle is not the main cause of involutional entropion on the basis of the findings of perioperative magnetic resonance imaging of the lower lid (17). However, in Jones procedure, a meticulous knowledge of the lower eyelid anatomy is required to precisely isolate and tighten the lower lid retractor, and it may be a difficult procedure for the occasional eyelid surgeons to perform. Barnes *et al.* suggested that an ideal operation should be effective, with minimum discomfort, rapid recovery and be simple enough for a trainee to perform (18). Rougraff *et al.* analyzed the published recurrence rates and suggested that the correction of at least 2 of 3 involutional changes

conferred a higher long-term success rate (19) ; therefore, we believe that rectifying as many causes of involutional entropion as possible is preferable. For general ophthalmologists and trainees, particularly when they do not have confidence in preoperative examination of horizontal and/or vertical laxity of the eyelid, it is certain that they choose a procedure that can address all the possible causes of involutional entropion.

We prefer the Quickert procedure because it can address horizontal eyelid laxity by full-thickness eyelid shortening and vertical eyelid laxity by tucking the lower lid retractor between the orbicularis oculi muscle and the tarsal plate and can prevent the preseptal orbicularis oculi muscle overriding by creating fibrosis with the sutures. In other words, the procedure can address all the known causes of involutional entropion at single surgery. Besides, the surgical technique can be performed by most ophthalmic practitioners and trainees because it is not always necessary to have meticulous knowledge of the lower lid lamellae. Full-thickness eyelid resection enables us to easily master the anatomy of the cross-section of the lower lid. Every ophthalmologist may understand the conjunctiva as a glossy mucosa and the orbicularis oculi muscle as a bloody striped tissue. The lower lid retractor can then be identified at a glance as it is whitish in appearance and is located between the orbicularis oculi muscle and the conjunctiva. When correcting involutional entropion, tucking the full-thickness layers of the lower lid retractor is important because the lower lid retractor consists of a double layer and the posterior layer represents the main tractional component of the lower lid (19). When only the anterior layer is addressed using the Jones procedure or if the lower lid retractors are not adequately isolated, it is possible for entropion to recur. In this case series, we treated a case of recurrent involutional entropion that was initially treated by an occasional eyelid surgeon using the Jones procedure. Overlooked horizontal eyelid laxity or insufficient tucking of the lower lid retractor without a clear understanding of the double layer may be the cause of recurrence. All of the recurred cases can be treated by a single Quickert procedure performed by an occasional eyelid surgeon (HE) without any support from oculoplastic specialists. We believe that a cross-section of the eyelid, that enables us to understand the full-thickness of the lower lid retractor even after a previous Jones procedure has obscured the layer, contributes to the excellent results for this

technique.

Although the success rate of Quickert procedure is reported to be the highest in several procedures, (5, 20), we have to take into account that patients inclusion of surgery for involutional entropion may elder patients who do not have high rates of life expectancy. In this cases series, the success rate is 100% and all cases are followed for at least 10 months, except for a case who died 8 months after the surgery, and the follow-up duration ranges to 89 months at maximum. Thus, this case series proves Quickert procedure have a good success rate for the long-term result. Mild notching of the eyelid margin and negligible symblepharon at the first vertical full-thickness incision occurred in only one patient with respect to postoperative complications in this case series. This patient had undergone three previous unknown surgeries by three different occasional eyelid surgeons. The symblepharon was possibly caused by a severe postoperative inflammation of the eyelid tissue due to the lack of normal anatomy. None of the patients experienced symblepharon after a primary Quickert procedure. At present, no complaints regarding these complications have been reported.

In conclusion, the Quickert procedure is easy for most ophthalmologists to perform, and it is the logical approach for rectifying involutional entropion. It can also be applied to recurrent cases in which the normal anatomy of the eyelid has already been lost after unknown surgery. The recurrence rate is very low in the long-term outcome. The Quickert procedure should be considered as one of the surgical treatments of choice for involutional entropion in the elderly Asian population.

CONFLICT OF INTEREST

The authors declared no conflict of interest.

REFERENCES

1. Dagleish R, Smith JLS : Mechanics and histology of senile entropion. *Br J Ophthalmol* 50 : 79-91, 1966
2. Dryden R, Leibsohn J, Wobig J : Senile entropion pathogenesis and treatment. *Arch Ophthalmol* 96 : 1883-1885, 1978
3. Jones LT : The anatomy of the lower eyelid and its relation to the cause and cure of entropion.

- Am J Ophthalmol 1 : 29-36, 1960
4. Collin JRO, Rathbun JE : Involutional entropion. A review with evaluation of procedure. Arch Ophthalmol 96 : 1058-1064, 1978
 5. Danks JJ, Rose GE : Involutional lower lid entropion. To shorten or not to shorten? Ophthalmology 105 : 2065-2067, 1998
 6. Kersten RC, Hammer BJ, Kulwin DR : The role of enophthalmos in involutional entropion. Ophthal Plast Reconstr Surg 13 : 195-198, 1997
 7. O'Sullivan EP, Howe LJ, Barnes E, Barnes J, Olver JM : Factors affecting the success rate of Quickert and Wies procedures for lower lid entropion. Orbit 17 : 59-60, 1999
 8. Oliver JM, Sathia J, Wright M : Lower eyelid medial canthal tendon laxity grading : an interobserver study of normal subjects. Ophthalmology 108 : 2321-2325, 2001
 9. Quickert MH : The eyelids. Malposition of the lid. In : Sorby A, editor. Modern Ophthalmology, 2nd ed. London : Butterworth, v. 4A, sec II, 1972, pp.937-954.
 10. Marcovits AS : Variations on the theme of involutional entropion and the Quickert repair. Ann Ophthalmol 12 : 1028-1032, 1980
 11. Tyers AG, Collin JRO : Colour atlas of ophthalmic plastic surgery, 3rd ed. London : Butterworth, vi. sec A, 2008, pp. 98-100.
 12. Carter SR, Chang J, Aguilar GL, Rathbun JE, Seiff R : Involutional entropion and ectropion of the Asian lower eyelid. Ophthal Plast Reconstr Surg 16 : 45-49, 2000
 13. Anderson RL, Gordy DD : The tarsal strip procedure. Arch Ophthalmol 97 : 2192-2196, 1979
 14. Rougraff PM, Tse DT, Johnson TE, Feuer W : Involutional entropion repair with fornix sutures and lateral tarsal strip procedure. Ophthal Plast Reconstr Surg 17 : 281-287, 2000
 15. Jones LT, Reeth MJ, Tsujimura JK : Senile entropion. Am J Ophthalmol 55 : 463-469, 1963
 16. Kakizaki H, Zako M, Mito H, Kato Y, Iwaki M : Modified operation to correctly detect and fix the lower eyelid retractor in involutional entropion. Jpn J Ophthalmol 49 : 330-332, 2005
 17. Kakizaki H, Zako M, Mito H, Katori N, Iwaki M : Magnetic resonance imaging of pre and postoperative lower eyelid states in involutional entropion. Jpn J Ophthalmol 48 : 363-367, 2004
 18. Barnes JA, Bunce C, Oliver JM : Simple effective surgery for involutional entropion suitable for the general ophthalmologist. Ophthalmology 113 : 92-96, 2006
 19. Kakizaki H, Zhao J, Nakano T, Asamoto K, Zako M, Iwaki M, Miyaishi O : The lower eyelid retractor consists of definite double layer. Ophthalmology 113 : 2346-2350, 2006
 20. Oliver JM, Barnes JA : Effective small-incision surgery for involutional lower eyelid entropion. Ophthalmology 107 : 1982-1988, 2000