

## CASE REPORT

# Fournier's gangrene in elderly patient : report of a case

Hajime Nakatani, Shinichi Hamada, Toyotake Okanoue, Akihiro Kawamura, Takashi Chikai\*, Shinya Yamamoto\*, Yuichiro Inoue\*\*, and Kazuhiro Hanazaki\*\*\*

*Department of Surgery, \*Department of Anesthesiology, and \*\*Department of Urology, Kubokawa Hospital, Kochi, Japan ; and \*\*\*Department of Surgery, Kochi Medical School, Kochi University, Kochi, Japan*

**Abstract : Fournier's gangrene (FG) is rapidly progressing acute gangrenous infection of the anorectal and urogenital area. FG needs precocious diagnosis and aggressive treatment with the use of wide spectrum antibiotics and surgical debridement. In our case, a 91-year-old Japanese female who had rehabilitation after treatment of pneumonia and her past history was rheumatoid arthritis treated with steroid and chronic heart failure. Her activities of daily living was bedridden with dementia. Necrotic skin was observed in urogenital and anorectal area and skin redness enlarged to the hip with high fever. Surgical debridement was performed. Both *Peptostreptococcus* Sp. and *Fusobacterium* Sp. was cultured from resected necrotic tissue. We used antibiotics, PAMP and PIPC, which had sensitivity for them. But unfortunately, disseminated intravascular coagulation occurred after 4th day of operation, and finally she died after 10th day of operation. We discussed the treatment for FG in patient with complication. J. Med. Invest. 58 : 255-258, August, 2011**

**Keywords :** *Fournier's gangrene, debridement, nutrition*

## INTRODUCTION

Necrotizing fasciitis of the anorectal and urogenital subcutaneous and fascias, also Fournier's gangrene (FG), is an uncommon condition that can affect patients of any age and rapidly progress to life-threatening disease. FG has a high death rate and is an acute surgical emergency. Successful treatment of FG is related to early diagnosis and appropriate intervention. The main points of treatment are aggressive hemodynamic stabilization, antibiotic therapy covering all suspected involved bacteria and emergency surgical debridement (1-3).

Received for publication January 24, 2011 ; accepted April 27, 2011.

Address correspondence and reprint requests to Hajime Nakatani Department of Surgery, Kubokawa Hospital, Shimanto-cho, Kochi, 786-0002, Japan and Fax : +81-880-22-1166.

In our present case, an elderly FG patient who had severe chronic heart failure with rheumatoid arthritis treated with steroid and her activity of daily living (ADL) was bedridden. We discussed the problems of the treatment after debridement focused on the adequate intervention especially nutritional approach.

## CASE REPORT

A 91-year-old Japanese female was admitted to our hospital due to pneumonia. Her past history was chronic heart failure and rheumatoid arthritis treated with steroid (predonine : 5 mg per a day). After treatment of pneumonia, she had a sudden high fever with necrosis of anorectal and urogenital area (Fig. 1). Skin redness enlarged rapidly. Peripheral blood test was as followed ; red blood cells :

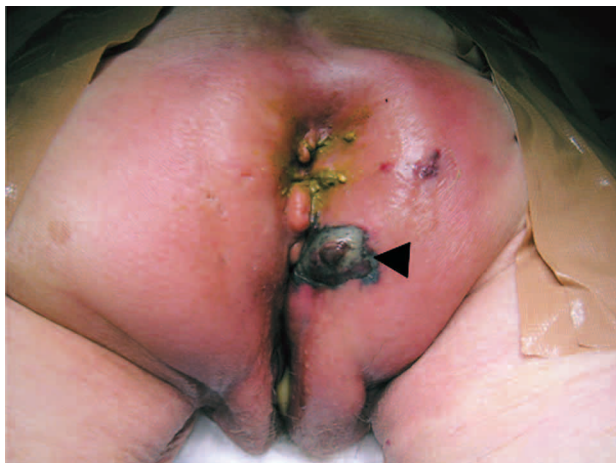

Figure 1 Anorectal and urogenital area at the pre-operation. Arrow head : skin necrosis

$320 (400-520) \times 10^4$ , hematocrit : 27.2 (36.0-48.0)%, hemoglobin : 9.7 (13.0-17.0) mg/dl, white blood cells : 18700 (4000-9000), sodium : 129 (138-146) mmol/l, potassium : 3.7 (3.6-4.9) mmol/l chloride : 98 (99-109) mmol/l, total protein : 5.2 (6.7-8.3) mg/dl, albumin : 2.6 (3.9-4.9) mg/dl, alkaline phosphatase : 172 (115-359) U/l, lactate dehydrogenase : 226 (119-229) U/l, total bilirubin : 0.5 (0.2-1.3) mg/dl, alanine aminotransferase : 13 (8-42) U/l, aspartate aminotransferase : 27 (13-33) U/dl, blood urea nitrogen : 53.8 (8.0-20.0) mg/dl, and creatinine : 1.4 (0.6-1.2) mg/dl, C-Reactive protein : 27.65 (0-0.3) mg/dl, and glucose : 92 (60-199) mg/dl. Computed tomography scan revealed that subcutaneous tissue density was relatively high and air density was observed (Fig. 2). We diagnosed FG, so we proposed emergency operation. Preoperative condition was very poor, and the risk classification of American Society of Anesthesiology (ASA) was 4E of this patient. Under saddle block anesthesia, aggressive

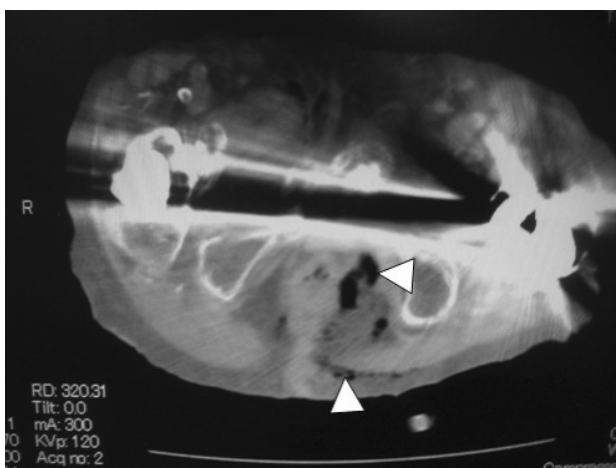


Figure 2 Computed tomography. Arrow head : air density in the subcutaneous tissue

debridement of necrosis tissue was performed immediately. Colostomy was not performed. Intraoperation and after operation, hypotension was observed and we used dopamine and norepinephrine. Bacteria was cultured from resected necrotic tissue, *Peptostreptococcus* Sp. and *Fusobacterium* Sp. were obtained. Antibiotic was used both PAMP and PIPC which had sensitivity for *Peptostreptococcus* Sp. and *Fusobacterium* Sp.. After operation wound discharge was very clear and blood pressure was kept stable. The wound at 3rd day after operation was described in Fig. 3. The 4th day after operation, disseminated intravascular coagulation (DIC) was occurred. 300 Kcal was administrated in the patient by a day. Amount of discharge from wound was about 400-600 ml per day. The concentration of serum albumin was decreased 2.6 mg/dl (preoperation) to 1.6 mg/dl (the 4th day after operation) inspite of providing 50% albumin of 50 ml for three days. Intravenous Hyperalimentation (IVH) was considered but we could not introduce IVH because sepsis was highly suspected. Oral intake was not considered because of preventing from fecal contamination. DIC was not recovered and the general status was worse gradually. At the 10th day after operation, she was died.

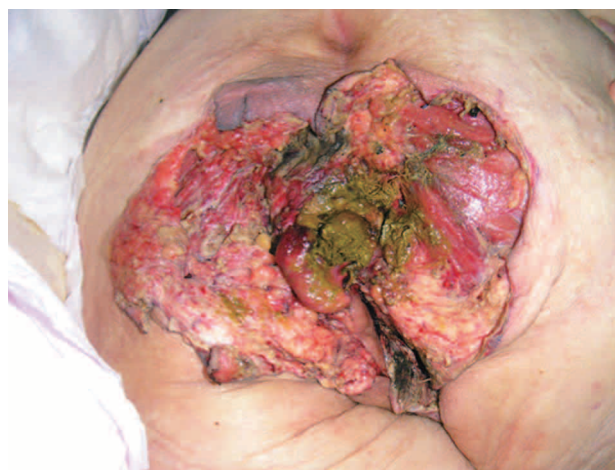

Figure 3 Anorectal and urogenital area 3rd day after operation. Necrotic tissue was completely resected.

## DISCUSSION

We present the case of FG patient who was treated with aggressive debridement, using broad-spectrum antibiotic, and controlled hypotension.

FG is a rapidly progressing acute gangrenous infection of the anorectal and urogenital area. Multiple laboratory makers have been suggested as useful in diagnosing necrotizing soft tissue infection

(NSTI). The Laboratory Risk Indicator for Necrotizing Fasciitis (LRINEC) score is weighted point system of such makers often used to stratify patients into low, moderate, or high risk for NSTIs (4) (Table 1, 2). In our case, calculated LRINEC score was 9 (high risk for NSTI). FG has a high mortality rate, so urgent diagnosis and treatment was required (1-3). Aggressive debridement was performed within 12 hours after high fever up. Her ADL was bedridden and she was dementia, so she could not tell her symptom. We could not detect the true onset time of FG. After operation, we could control blood pressure and urinary volume for 3 days using both dopamine and norepinephrine. However blood examination revealed that DIC was occurred 4th day after operation, even though the local infection was not observed in surgical site (Fig. 3). Long-standing steroid therapy is one of risk of FG. In our case, she had a long-termed steroid therapy. Ullah *et al.* reported that systemic predisposition such as diabetes mellitus, long-standing steroid therapy, and chronic alcoholism can contribute to this dreadful disease (5). Akcan *et al.* reported that colostomy should be performed during initial debridement for the FG patients. They said that mortality rate of FG patients who were underwent to be performed

Hartmann colostomy was significantly increased than that of those who were performed debridement alone (6). However we did not perform colostomy because the general condition was very poor at the initial operation time (ASA risk 4E). Furthermore they commented that colostomy may not be necessary in penile and scrotal FG because of relatively low fecal contamination, but in perianal FG it may be useful to accelerate wound healing by avoiding fecal contamination (6). Colostomy may lead to early oral intake and thus may help to improve the wound healing process with better nutrition. Total parenteral nutrition can also be achieved without colostomy, but this may reduce immunological competence. IVH was not introduced because sepsis was highly suspected. Much amount of wound discharge and low calorie intake induced malnutrition. Management of nutritional support for FG patients was not established. FG cause systemic immune response like sepsis. Marik *et al.* reported that immunomodulating diets with fish oil improved the outcome of medical Intensive Care Unit (ICU) patients with sepsis (7). Elental™ (elemental diet) is composed of aminoacids, vitamins, trace elements, very little fat and a major energy source, dextrin. Elental™ is little fiber and it may reduce fecal material, and it

Table 1 Laboratory Risk Indicator for Necrotizing Fasciitis Score (LRINEC)

Value	LRINEC score, points
<b>C-reactive protein, mg/l</b>	
<150	0
>150	4
<b>WBC count (cells/mm<sup>3</sup>)</b>	
<15	0
15-25	1
>25	2
<b>Hemoglobin level(g/dl)</b>	
>13.5	0
11-13.5	1
<11	2
<b>Serum sodium level, (mM)</b>	
≥135	0
<135	2
<b>Creatinine level, (mg/dl)</b>	
≤1.6	0
>1.6	2
<b>Glucose Level, (mg/dl)</b>	
≤180	0
>180	1

Table 2 Reference to the risk category of Necrotizing Soft Tissue Infection (NSTI) by the Laboratory Risk Indicator for Necrotizing Fasciitis Score (LRINEC)

Risk category	LRINEC Score, points	Probability of NSTI (%)
<b>Low</b>	≤5	<50
<b>Intermediate</b>	6-7	50-75
<b>High</b>	≥8	>75

is used for Crohn's patients (8). So we should consider to introduce Elental™ with fish oil into our patient.

In conclusion, we assessed the condition of patients who were suffered FG carefully in first of all. Urgent debridement should be performed and colostomy also should be performed if possible, and using broad-spectrum antibioticus and controlled hypotention was necessary. Adequate nutritional approach for FG patients was not established. We think that Elental™ with fish oil may be useful for avoiding malnutrition of FG patients.

## REFERENCES

1. Eke N : Fournier's gangrene : a review of 1726 cases. *Br J Surg* 87 : 718-728, 2000
2. Yanar H, Taviloglu K, Ertekin C, Guloglu R, Zorba U, Caboglu N : Fournier's gangrene : risk factors and strategies for management. *World J Surg* 30 : 1750-1754, 2006
3. Spirnak JP, Resnick MI, Hampel N, Persky L : Frounier's gangrene : Report of 20 patients. *J Urol* 131 : 289-291, 1984
4. Wong CH, Khin LW, Heng KS, Tan KC, Low CO : The LRINEC (Laboratory Risk Indicator for Necrotizing Fasciitis) score : a tool for distinguishing necrotizing fasciitis from other soft tissue infections. *Crit Care Med* 32 : 1535-1541, 2004
5. Ullah S, Khshn M, Asad Ullah Jan M : Fournier's gangrene : a dreadful disease. *Nephrol Dial Transplant* 7(3) : 138-142, 2009
6. Akcan A, Sözüer E, Akyldiz H, Yilmaz N, Küçük C, Ok E : Necessity of preventive colostomy for Fournier's gangrene of the anorectal region. *Ulus Travma Acil Cerrahi Derg* 15(4) : 342-346, 2009
7. Marik PE, Zaloga GP : Immunonutrition in critically ill patients : a systemic review and analysis of the literature. *Intensive Care Med* 34 (11) : 1980-1990, 2008
8. Yamamoto T, Nakahigashi M, Umegae S, Kitagawa T, Matsumoto K : Acute duodenal Crohn's disease successfully managed with low-speed elemental diet infusion via nasogastric tube : a case report. *World J Gastroenterol* 12(4) : 649-651, 2006