

CASE REPORT

Acute abdomen caused by both acute appendicitis and epididymitis

Hajime Nakatani, Shinichi Hamada, Toyotake Okanoue, Akihiro Kawamura, Yuichiro Inoue*, Shinya Yamamoto**, Takashi Chikai**, Makoto Hiroi***, and Kazuhiro Hanazaki****

*Department of Surgery, *Department of Urology, and **Department of Anesthesiology, Kubokawa Hospital, Kochi, Japan ; ***Laboratory of Diagnostic Pathology, and ****Department of Surgery, Kochi Medical School, Kochi University, Kochi, Japan*

Abstract : Acute appendicitis often presents as right lower quadrant (RLQ) pain, severe tenderness at the point of McBurney or Lanz, and Blumberg's sign. Scrotal events with appendicitis are very rare. In our case, a 63-year-old Japanese man presented with severe RLQ pain and high fever. Physical examination revealed severe tenderness (including both points of McBurney and Lanz) and Blumberg's sign. The scrotum was slightly swollen and showed local heat with severe testicular pain. Abdominal computed tomography revealed ascites in a pelvic space and the right side of the spermatic cord was swollen. Emergency operation was performed and the final diagnosis was catarrhal appendicitis and acute epididymitis. This is the first report of acute appendicitis concomitant with acute epididymitis. *J. Med. Invest.* 58 : 252-254, August, 2011

Keywords : right lower quadrant pain, acute appendicitis, epididymitis, acute abdomen

INTRODUCTION

Acute appendicitis is one of the most common acute abdominal diseases requiring emergency operation. The diagnosis is based on well-established clinical symptoms and basic radiological examination (1). Epididymitis is the most common cause of testicular pain, and usually shows acute onset (2). We present herein a case of concomitant acute catarrhal appendicitis and epididymitis with severe right lower quadrant (RLQ) pain and pelvic ascites.

Received for publication January 14, 2011 ; accepted March 7, 2011.

Address correspondence and reprint requests to Hajime Nakatani, Department of Surgery, Kubokawa Hospital, Shimantocho, Kochi 786-0002, Japan and Fax : +81-880-22-1166.

CASE REPORT

In November 2009, a 63-year-old Japanese man presented with RLQ pain that had been continuous for a night. Past history included poliomyelitis in infancy. Physical examination showed severe tenderness at the points of both McBurney and Lanz with Blumberg' sign, and a swollen scrotum with testicular pain. Body temperature was 38.3°C. Peripheral blood leukocyte count was 15,600/mm³ (normal, 4000-9000/mm³) and serum C-reactive protein level was 11.05 mg/dl (normal, 0.00-0.03 mg/dl). Urine sediment test showed a white blood cell count of 10-19/high-power field. Abdominal computed tomography (CT) revealed swelling of the spermatic cord on the right side (Fig. 1a, arrow) and ascites in the pelvic space (Fig. 1a, arrowhead), but we could not detect a swollen appendix. Ultrasonography showed a swollen epididymis (Fig. 1b,

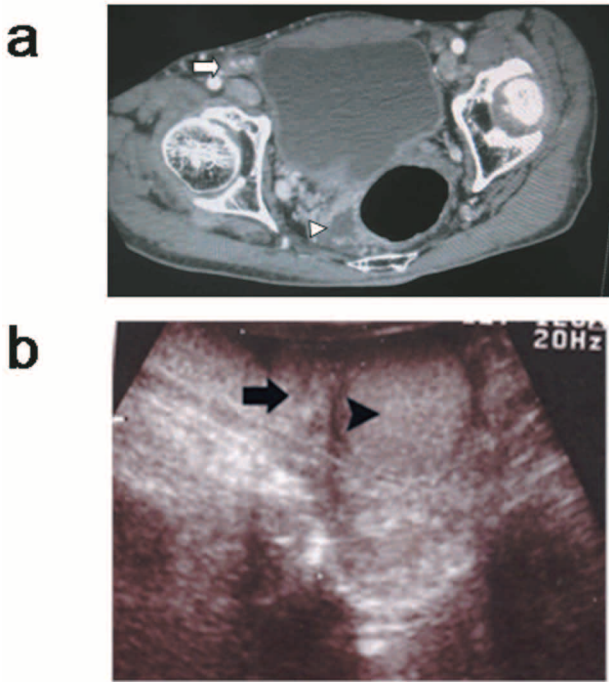


Figure 1 :
a : CT scan
Arrow, spermatic cord ; arrowhead, ascites.
b : Ultrasonography shows coronary section.
Arrow, epididymis ; arrowhead, testis.

arrow).

Given the above problems, acute appendicitis and acute epididymitis were considered. Appendectomy was performed using McBurny's incision. Ascites was serous, but not clear. No surgical drain was used. Pus was observed in the lumen of the appendix (Fig. 2, arrow). Pathological analysis revealed infiltrating leukocytes localized in the mucosal layer and exfoliation of the mucosa, so catarrhal appendicitis was diagnosed (Fig. 3a, b). *Enterobacter aerogenes* was detected in urine, but not in ascites. Cefmetazole (CMZ) was administered as antibiotic for 5 days.

Postoperatively, RLQ pain continued for about 4

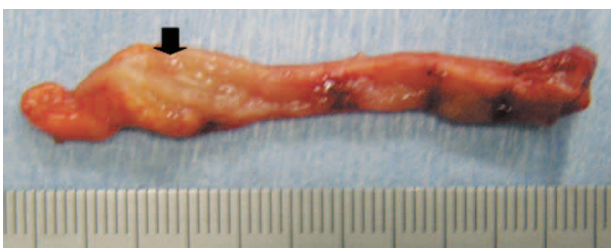

Figure 2 : Surgical specimen
Arrow, pus-coated lumen of the appendix.

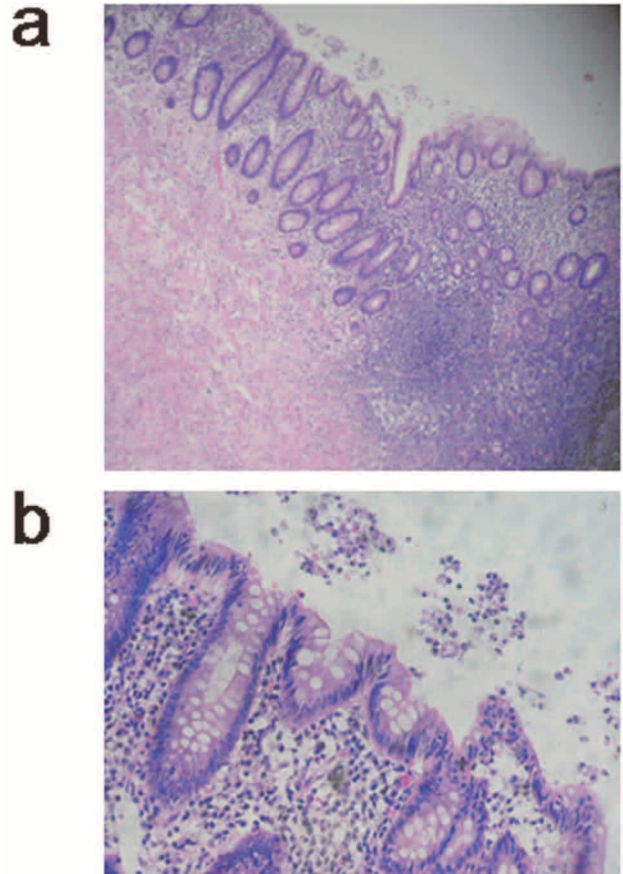


Figure 3 : Pathological analysis
a : ×100, b : ×400 magnification

days and testicular pain gradually disappeared (Fig. 4). However, the patient unfortunately developed herpes zoster during hospitalization and thus was not discharged until postoperative day 20.

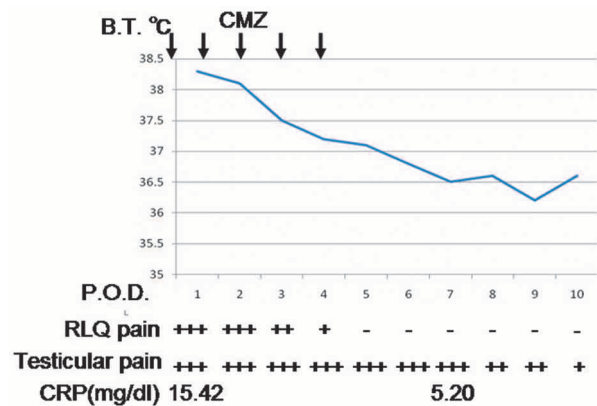


Figure 4 : Time course of body temperature, right lower quadrant pain (RLQ), testicular pain, and concentration of C-reacted protein.
X-axis : body temperature (B.T.) Y-axis : postoperative day (P.O.D)
+++ : severe pain, ++ : moderate pain, + : mild pain
Arrow, cefmetazole administration

DISCUSSION

We present the first report of concomitant acute appendicitis and epididymitis. Epididymitis is most often associated with sexually transmitted diseases, and the peak incidence is 25 years old. Conversely, in men over 50 years old, epididymitis is associated with urinary tract infection or prostatitis (2). Treatment of epididymitis is with antibiotics, based on the association with urinary tract infection (2). The frequency of lower abdominal pain with epididymitis is not clarified. During 2005-2010, in our hospital, 17 patients were diagnosed with epididymitis. Of these, 6 patients diagnosed with epididymitis showed lower abdominal pain, localized to the inguinal region and mild in all cases.

In the present case, the patient had severe RLQ pain at McBurny's and Lanz's points and testicular pain was severe. *Enterobacter aerogenes* was grown in urine culture, but not in ascites. Therefore, we could not confirm the involvement of *Enterobacter aerogenes* in this event. Saleem described a case in which a scrotal event occurred following a perforated appendicitis (3). In the present case, as pathological analysis indicated that the appendicitis was not severe, we could not confirm whether there was a relationship between acute appendicitis and epididymitis. Inflammatory diseases such as acute appendicitis or diverticulitis manifest as stranding of fat in tissues adjacent to the thickened bowel wall on CT (4). CT revealed intraperitoneal fluid collection in the pelvic space, but fat tissue in the RLQ of the abdomen and appendix did not display

inflammatory changes. The spermatic cord was swollen on the right side on CT. This swollen spermatic cord was probably followed by epididymitis. Appendectomy was performed on suspicion of appendicitis due to severe symptoms.

Pathological analysis revealed infiltrating leukocytes localized in the mucosal layer, and exfoliated mucosa was observed so catarrhal appendicitis was diagnosed. After appendectomy, testicular pain and RLQ pain continued for 10 days and 4 days, respectively.

In conclusion, we encountered a case of acute abdomen with severe RLQ pain due to acute appendicitis and spermatitis followed by epididymitis.

REFERENCES

1. Akbulut S, Ulku A, Senol A, Tas M, Yagmur Y : Left-sided appendicitis : Review of 95 published cases and a case report. *W J Gastroenterol* 16 (44) : 5598-5602, 2010
2. Schubert H : Emergency case. Acute testicular pain. *Can Fam Physician* 46 : 1289-1290, 2000
3. Saleem MM : Scrotal abscess as a complication of perforated appendicitis : a case report and review of the literature. *Cases J* 1(1) : 165, 2008
4. Lee MW, Kim YJ, Jeon HJ, Park SW, Jung SI, Yi JG : Sonography of acute right lower quadrant pain : importance of increased intraabdominal fat echo. *Am J Roentgenol* 192(1) : 174-179, 2009