

ORIGINAL**Wound sealing- related complications of 25-gauge vitrectomy in proliferative diabetic retinopathy versus simple macular pathology**

Khulood M Sayed^{1,2}, Takeshi Naito¹, Mahmoud M Farouk^{1,2}, Toshihiko Nagasawa¹, Takashi Katome¹, and Yoshinori Mitamura¹

¹Department of Ophthalmology and Visual Neuroscience, Institute of Health Biosciences, the University of Tokushima Graduate School, Tokushima, Japan ; and ²Department of Ophthalmology, Sohag Faculty of medicine, Sohag University, Egypt

Abstract : Purpose : To compare the incidence of wound sealing-related complications of 25-gauge transconjunctival sutureless vitrectomy (25-G TSV) for proliferative diabetic retinopathy (PDR) versus non-diabetic simple macular pathology (SMP). **Methods :** A retrospective comparative study was conducted on 377 eyes that underwent 25-G TSV for PDR ($n=189$ eyes) or non-diabetic SMP ($n=188$ eyes). Both groups were compared retrospectively and followed for at least 1 month (range 1-6 months). Main outcome measure was the incidence of postoperative wound sealing-related complications in both groups. **Results :** We found a statistically significant lower incidence of wound sealing-related complications on the 1st postoperative day in the PDR than SMP group (P -value <0.05). The incidence were as follows : 9% vs 18% for hypotony, 0% vs 2% for choroidal detachment, 0% vs 2% for external leakage and 1% vs 8% for conjunctival bleb formation, for the PDR and SMP groups respectively. This was associated with a significantly higher postoperative inflammation and IOP in PDR group. The day 1 higher postoperative IOP and inflammation were correlated with the presence of PDR pathology. **Conclusion :** The higher postoperative inflammation and IOP following vitrectomy in diabetic eyes, especially when combined with endolaser photocoagulation, makes such eyes less susceptible to wound sealing-related complications following sutureless vitrectomy. *J. Med. Invest.* 58 : 29-38, February, 2011

Keywords : *sutureless vitrectomy, proliferative diabetic retinopathy, simple macular pathology, wound sealing related complications, hypotony*

The 25-gauge transconjunctival sutureless vitrectomy (25-G TSV) system offers several advantages over the standard 20-gauge pars plana vitrectomy

Received for publication August 8, 2010 ; accepted October 6, 2010.

Address correspondence and reprint requests to Takeshi Naito, MD, PhD, Department of Ophthalmology, Institute of Health Biosciences, the University of Tokushima Graduate School, Kuramoto-cho, Tokushima 770-8503, Japan and Fax : +81-88-631-4848.

(PPV). It has been primarily used to treat less complicated vitreoretinal pathologic conditions, such as macular hole (MH) and epiretinal membrane (ERM) (1), but as a result of the recent (and ongoing) improvement in 25-gauge microsurgical instruments, more patients with complicated conditions are now being considered candidates for 25-G TSV (2). Studies have reported expanding applications and low rates of complication with 25-G TSV.³ However,

some complications are specifically related to the sutureless vitrectomy (4-6). Wound leakage and hypotony with choroidal detachment are the most common complications (7, 8) and the risk of more serious complications such as endophthalmitis may be greater due to the unsutured sclerotomy sites (9). Among the possible explanations for the self-sealing nature of transconjunctival sutureless sclerotomies are small wound size, internal vitreous plugging of small wounds, and covering of overlying conjunctiva and Tenon's capsule (1, 10, 11). Recently, it was reported that oblique insertion of a 25-gauge cannula reduced the incidence of postoperative hypotony (10, 11). A special concern was directed to the higher possibility of wound sealing-related complications in the complicated vitreoretinal pathologies managed with 25-G TSV, since the extensive peripheral vitrectomy often needed in such cases is considered to be a risk factor for postoperative hypotony (12, 13). In addition, Lakhanpal *et al.* suggested that the more extensive intraocular manipulation required in these patients, predisposed to transient hypotony (13). A possible delay in wound healing in patients with diabetes mellitus is another concern if a sutureless technique is used (2). Moreover, diabetic patients have an altered immunity at various levels and may be more susceptible to infection after ocular surgery (14). Accordingly, this risk become higher after leaving wounds without sutures. So it was very important and useful to investigate the incidence of such wound sealing-related complications of 25-G TSV in eyes with complicated pathology as proliferative diabetic retinopathy (PDR) and compare them with simple non diabetic eyes as those with ERM and MH as a control group.

PATIENTS AND METHODS

Design

A retrospective comparative case series study was performed on patients underwent primary 25-G TSV for the management of vitreoretinal complications of PDR from September 2006 to May 2009 and for non diabetic simple macular pathology (SMP) as ERM and MH from June 2006 to march 2010.

Patients

We reviewed the medical records of 377 eyes of 349 patients with PDR ($n=189$ eyes of 164 patients) or SMP ($n=188$ eyes of 185 patients) who underwent primary 25-G TSV.

Patients were recruited from the vitreoretinal clinics at Tokushima University Hospital, Ophthalmology Department, Tokushima, Japan. Informed consent was obtained from all patients before vitrectomy which was done by 3 surgeons. The study was conducted in accordance to the tenets of the Declaration of Helsinki of Human studies.

Inclusion criteria

Patients with SMP as ERM or MH or vitreoretinal complications of PDR as unresolved vitreous hemorrhage (VH), tractional retinal detachment (RD) and progressive fibrovascular proliferations requiring a primary vitrectomy.

Exclusion criteria

Eyes with prior vitreous surgery, glaucoma filtration surgery, patients with inadequate follow up and eyes with intraoperative injection of silicone oil tamponading agent.

Methods

Patients medical records were reviewed and the following data were collected : age, gender, intraocular pressure (IOP), which was measured preoperatively and on the 1st, 5th day, 1st, 3rd and 6th postoperative months using Goldmann applanation tonometer (the mean IOP of 3 successive measurements was taken). The degree of postoperative anterior chamber (AC) inflammation was also collected ; it was graded qualitatively by slit-lamp examination (anterior chamber cell count, presence or absence of flare and/or fibrin formation). Lens status, intraoperative vitreous fill, suture use, intraoperative and postoperative complications were also recorded with a special attention to wound sealing-related complications.

Patients who met the inclusion criteria were followed for at least 1 month which was considered by us to be the maximum period for occurrence of wound sealing-related complications. Patients who did not complete their follow up visits or underwent another surgery after the 1st postoperative month were excluded from 3rd or 6th month data analysis.

SURGICAL TECHNIQUE

All patients underwent a standardized surgical procedure for vitrectomy combined or not with phacoemulsification and intraocular lens (IOL) implantation under retrobulbar anesthesia. In cases when

phacoemulsification was combined with vitrectomy, it was performed before the vitrectomy after cannula insertion. All patients underwent primary 25-G TSV with the newly designed 25-gauge titanium Naito microcannula system (Duckworth & Kent Inc., Hertfordshire, UK) which has a precision engineered step in the cannula to prevent slippage. The conjunctiva and Tenon capsule were displaced over the sclera to avoid communication between the conjunctival and scleral entry sites and to minimize the risk of postoperative fluid leakage. The conjunctiva was fixed to the sclera with a fixation ring (Duckworth & Kent Inc., Hertfordshire, UK) and the incisions were made by inserting a 25-gauge microvitrectomy blade (Bauch & Lomb Inc., Rochester, USA) at a 30° to 40° angle through the conjunctiva, sclera and the pars plana 3.5-4 mm posterior to the limbus. The newly designed 25-gauge Naito microcannulas were inserted through the conjunctival incision and the scleral tunnel using a cannula inserter (Duckworth & Kent Inc., Hertfordshire, UK). The infusion catheter was connected to the inferotemporal microcannula (which was the first to be inserted and the last to be removed) and turned off till the beginning of the vitrectomy procedure. Scleral tunnel lens surgery with intraocular lens implantation was then performed for all cases with visually significant cataract which would preclude adequate fundus visualization for operative procedure and for postoperative care and also in all cases aged over 50 to avoid postoperative cataract progression. In both groups a core vitrectomy and vitrectomy around sclerotomy sites were performed. Intravitreal injection of triamcinolone acetonide (TA) (Kenacort-A; Bristol Myers Co Ltd, Tokyo, Japan; 4 mg/0.1 ml) was injected over the posterior pole for better visualization and complete removal of the posterior cortical vitreous. In eyes with no preoperative posterior vitreous detachment (PVD), the posterior hyaloid membrane was detached at the optic disc by aspiration using a vitreous cutter. In eyes with PDR, dissection and removal of proliferative fibrovascular and epiretinal membranes was performed efficiently using 25-G forceps, scissors and cutter. Transvitreal diathermy was used to coagulate bleeding vessels. Peripheral shaving of the vitreous base was then performed using indentation. The peripheral retina was checked at the same time for any breaks or fibrovascular tissue. A directional endolaser was used with indentation for panretinal photocoagulation (PRP) and to seal around retinal breaks: either iatrogenic,

detected during peripheral internal search or in cases with tractional rhegmatogenous RD.

In eyes with simple macular pathology, ERM was removed, with or without internal limiting membrane (ILM) peeling. In eyes with macular hole, ILM peeling was performed in all cases with indocyanine green injection (0.125%). All vitrectomies were performed with careful 360° scleral depression to assist peripheral retinal examination and to facilitate trimming the anterior as well as posterior vitreous base. For both groups, fluid-gas exchange with perfluoropropane (C3F8 12% to 16%), fluid-air exchange or no exchange were done according to the surgical indication or surgeon's preference. Finally, microcannulas were removed from the scleral tunnels. The infusion cannula was the last to be removed to maintain the stability of the globe, the conjunctiva was pushed laterally using a cotton wool applicator to separate its incision from the scleral incision and pressure was applied over the sclera for wound closure for a few seconds to promote wound seal. At the end of the case, all sclerotomy sites were inspected to detect bleb formation or any frank leakage that may require suture placement. Subconjunctival injections of antibiotics and steroid were given and antibiotic eye ointment was applied at the conclusion of surgery. Main outcome measures were: 1) Preoperative and postoperative IOP 2) Postoperative inflammation and 3) Postoperative wound sealing-related complications and 4) The correlation between postoperative hypotony and preoperative eye disease.

STATISTICAL ANALYSIS

Visual acuities were measured with a Landolt C chart and then converted to the logarithm of the minimum angle of resolution (logMAR) equivalents for statistical analysis. All data were statistically analyzed using the paired Student's *t* test and independent samples *t* test when appropriate; using SPSS software for Windows, with a *P* value of less than 0.05 was considered to be statistically significant. Bivariate relationships were examined using *Pearson* correlation test or by *Spearman* correlation test. *Z* test was used to compare between proportions of the 2 groups. Hypotony was defined as an IOP of less than 8 mmHg as it was defined in previous studies (15, 16). High IOP was defined as IOP of ≥ 22 mmHg considering 21 mmHg as the upper limit of normal. Anterior chamber cell grading was done

according to the SUN (Standardization of Uveitis nomenclature) working group grading scheme for anterior chamber cells (17) as follows : 0 = < 1 cell, 0.5+ = 1-5 cells, 1+ = 6-15 cells, 2+ = 16-25 cells, 3+ = 26-50 cells, 4+ = > 50 cells.

RESULTS

Patients characteristics

Three hundred seventy seven (377) eyes of 349 patients met the inclusion criteria and underwent 1ry 25-G TSV for the management of SMP or the vitreoretinal complications of PDR. The patient demographics and base line preoperative data for all patients are summarized in (Table 1).

There was a female predominance in SMP group ($P=0.00$) and a significantly younger age and a higher preoperative mean IOP ($P=0.00$) in PDR group than SMP group. Such differences were expected from the natural occurrence, and pathophysiology of each disease which will not affect our statistical analysis of data as we will compare the postoperative results of each group with its own base line values ; not with results from the other group. The follow up period was for at least 1 month range (range 1-6 months). Surgical indications for vitrectomy in PDR group were vitreous hemorrhage, tractional retinal detachment, progressive fibrovascular proliferations and tractional rhegmatogenous retinal detachment. For SMP group, surgical indications were idiopathic or secondary ERM, idiopathic or traumatic MH, MH with ERM and macular schisis.

Intraoperative results

In PDR group, endodiathermy was used to control bleeding during membrane dissection in 14 eyes (7%). Directional endolaser with indentation was used for supplementary or primary panretinal photocoagulation in all cases with a mean number of spots of 1002 ± 678.3 . Retinotomy was required in 2 eyes only (1%) and subretinal strand removal in 2 eyes (1%). In SMP group, intraoperative, small petechiae from the perifoveal capillary bed were noted during ERM removal in 28 eyes (27%) and in 2 cases of MH during ILM peeling. However, in all cases, this phenomenon was always readily controlled simply by temporarily elevating the intraocular pressure and it had no effect on the early or final visual outcomes. Most of these petechiae completely disappeared before the 1st postoperative month. Posterior vitreous detachment was surgically induced in 115 (61%) eyes with SMP. Epiretinal membranes were successfully removed from the fovea in all except 10 (10%) eyes where residual membrane was left in the macular area, far from the fovea. Successful macular hole closure had been achieved in 78 (91%) eyes by the time of the 6 month follow up visit. In both groups, all intraoperative breaks were treated by intraoperative endolaser photocoagulation and if necessary, gas tamponade. At the conclusion of surgery, there was no significant difference between both groups as regard the number of fluid filled eyes (58% vs 52%) or eyes with air/gas tamponade (42% vs 48%) for PDR and SMP groups respectively ($P=0.1$). There

Table 1. Patients Demographics

Characteristic	PDR	SMP	P-value†
Eyes	189	188	0.47
Male	119	78	0.00*
Female	70	110	0.00*
Average age(yrs±)	56.81± 11.42	66.11± 8.63	0.00*
Preop. IOP	15.22± 4.77	14.01± 3.39	0.005*
Phakic	164 (87%)	172(91%)	0.07
Pseudoph.	25 (13%)	16 (9%)	0.07

PDR=proliferative diabetic retinopathy ; SMP=simple macular pathology ; OD=right eye ; OS=left eye ; Preop.=preoperative ; IOP= intraocular pressure.

Values are expressed in number of eyes

Age, IOP are presented as mean± standard deviation (SD)

† Z-test to compare between 2 proportions

* P-value is statistically significant

was no statistically significant differences between both groups regarding the intraoperative complications ($P > .05$) except for the incidence of intraoperative retinal breaks, which was significantly higher in the PDR group ($P=0.00$). We did not recognize any intraoperative technical problems or any intraoperative complications related to small gauge instrumentation such as deformation of the microcannula, disconnection of the infusion cannula or breakage of the vitreous cutter in either groups. No patients in either group required a suture at the sclerotomy site because of leakage and no sclerotomies were converted to the 20-gauge procedure for the management of existing surgical pathology or intraoperative complications.

Postoperative results

In both groups, the mean baseline logMAR BCVA improved significantly at the 1st, 3rd and 6th month postoperative visits ($P=0.000$). In PDR group, the mean IOP at the 1st postoperative day was higher (15.77 ± 7.88) than the baseline values (15.22 ± 4.77), albeit insignificant ($P=0.161$), this was not the case for the SMP group, where the mean day 1 IOP (12.93 ± 6.33) was significantly lower than the baseline preoperative values (14.01 ± 3.39 ; $P=0.02$),

(Figure 1). We reported a significant decrease in the mean IOP on the 5th postoperative day compared to baseline values for both groups (13.48 ± 5.96 mmHg) and (12.72 ± 4.28 mmHg) for PDR and SMP groups respectively. Postoperative IOP returned closer to the baseline levels in both groups by the 1st postoperative month (Figure 1) and thereafter. As the mean preoperative IOP was significantly higher for PDR group, we were not able to compare between both groups in terms of postoperative IOP, but when we made a subgroup analysis we found that, the mean preoperative IOP for gas/air filled eyes in both groups was comparable (15.36 ± 4.3 and 14.42 ± 3.29) for PDR and SMP groups respectively ($P=0.08$), allowing us to compare the postoperative IOP in this subgroup in both main groups (Figure 2).

We found a significantly higher mean IOP for PDR group at the 1st postoperative day (15.77 ± 7.89 mmHg) than for SMP group (13.43 ± 6.68 mmHg; $P= 0.023$) but not thereafter (Figure 2).

The mean postoperative anterior chamber cell grading was significantly higher in PDR group than in SMP group at the postoperative day 1 (2.27 ± 0.93 vs 1.48 ± 0.96 ; $P=0.00$) and day 5 (1.59 ± 0.96 vs 0.97 ± 0.79 ; $P=0.00$) but not thereafter. In PDR

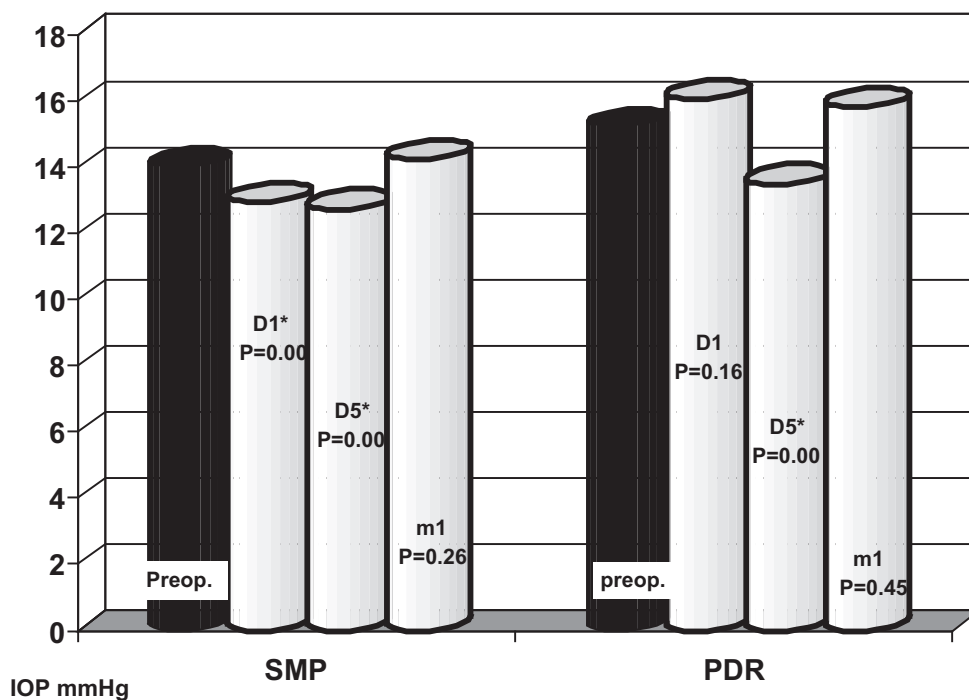


Figure 1. Comparing preoperative & postoperative mean IOP for each group after exclusion of silicon oil filled eyes. IOP=intraocular pressure ; PDR=proliferative diabetic retinopathy ; SMP=simple macular pathology ; Preop.=preoperative ; D1=1st postoperative day ; D5=5th postoperative day ; M1=1st postoperative month. *P-value is statistically significant

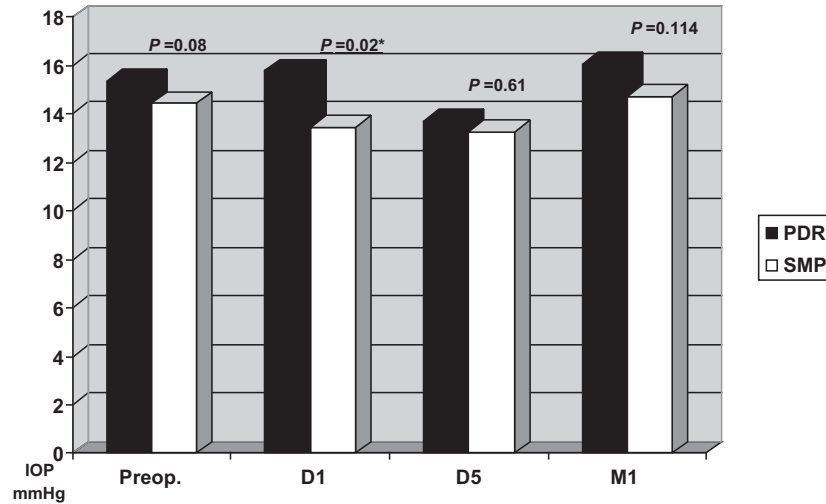


Figure 2. Comparing preoperative & postoperative mean IOP in air/gas filled eyes between both groups IOP=intraocular pressure ; PDR=proliferative diabetic retinopathy ; SMP=simple macular pathology ; Preop.=preoperative ; D1=1st postoperative day ; D5=5th postoperative day ; M1=1st postoperative month. *P-value is statistically significant

group anterior chamber cell grading was significantly higher at the postoperative day 1 than day 5 (2.27 ± 0.92 vs 1.59 ± 0.96 ; $P=0.00$).

At the 1st postoperative day, PDR group showed a significantly higher incidence of anterior chamber flare (23% vs 6% ; $P=0.00$) and fibrin (12% vs 2% ; $P=0.00$), (Figure 3) the same was at the postoperative day 5 (16% vs 4% for flare ; $P=0.00$ and 7% vs 0.5% for fibrin ; $P=0.00$) for PDR and SMP group respectively.

The higher postoperative day 1 IOP was correlated with the presence of PDR pathology ($r=0.219$, $P=0.00$) and with postoperative day 1 anterior chamber cell grading ($r=0.192$, $P=0.00$). Also, the higher

postoperative day 1 anterior chamber cell grading was correlated with the presence of PDR pathology ($r=0.385$, $P=0.00$). Absence of hypotony also was correlated to the presence of PDR pathology ($r=0.14$, $P=0.007$). No correlations were found between the postoperative day 1 IOP and preoperative IOP, type of vitreous filling or the age of the patient.

The incidence of early postoperative complications which were attributed to the sutureless technique itself are summarized in table 2, (Figure 3). Postoperative bleb was defined as subconjunctival fluid collection indicating subconjunctival fluid leakage which may, or may be not associated with external leakage (positive Seidle test). Proliferative diabetic

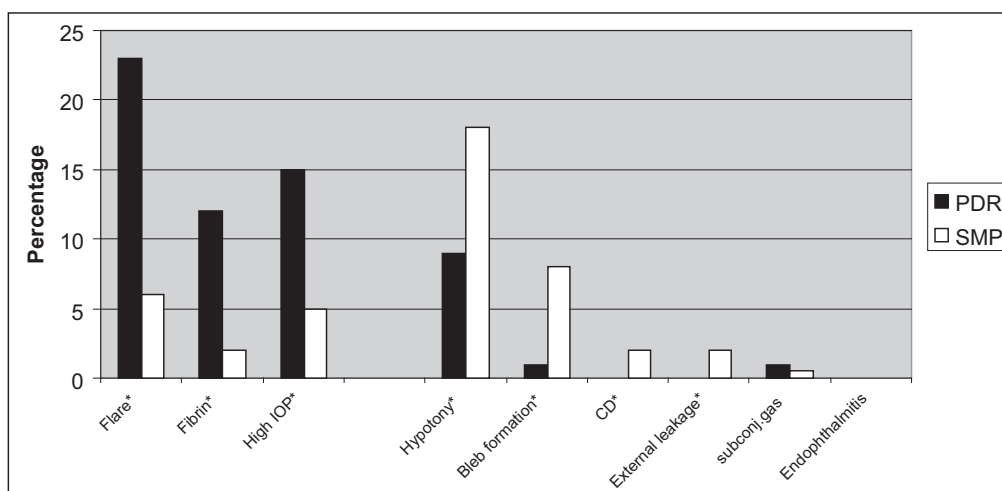


Figure 3. Percentage of the 1st postoperative day inflammation, high IOP and wound-sealing related complications in both groups PDR=proliferative diabetic retinopathy ; SMP=simple macular pathology ; IOP=intraocular pressure ; CD=choroidal detachment ; subconj.=subconjunctival *P-value is statistically significant

Table 2. Postoperative wound sealing related complications in both groups

Early postoperative complications	1 st postoperative day			5 th postoperative day		
	PDR	SMP	<i>P</i> -value†	PDR	SMP	<i>P</i> -value†
Hypotony	18(9%)	35(18%)	0.000*	15(8%)	14(7%)	0.47
Choroidal detachment	0(0%)	4(2%)	0.02*	2(1%)	1(0.5%)	0.29
External leakage (+ve Seidle)	0(0%)	3(2%)	0.04*	0(0%)	0(0%)	
Bleb formation	2(1%)	16(8%)	0.000*	3(2%)	7(4%)	0.09
Subconjunctival gas	2(1%)	1(0.5%)	0.29	1(0.5%)	1(0.5%)	0.49
Endophthalmitis	0(0%)	0(0%)		0(0%)	0(0%)	

PDR=proliferative diabetic retinopathy ; SMP=simple macular pathology ; +ve=positive.

Values are presented as number of eyes (%)

† Z-test to compare between 2 proportions

*P-value is statistically significant

retinopathy group showed a significantly lower incidence of day 1 hypotony, choroidal detachment, external leakage and conjunctival bleb formation on the 1st postoperative day than SMP group ($P < 0.05$), however, there was no significant difference between both groups in the incidence of these complications at the 5th postoperative day or thereafter. No eyes with external leakage were noted in PDR group. All cases of postoperative wound sealing-related complications in both groups passed uneventually, none of them required scleral suturing or air infusion. On the other hand, we reported a significantly higher incidence of the 1st postoperative day high IOP (≥ 22 mmHg) in PDR group (15.5%) compared to (4%) only in SMP group ($P = 0.000$), no significant difference was found thereafter (Figure 3).

There were no cases of early or late postoperative endophthalmitis in either of the 2 study groups, however, there was one eye in each group suffered from sterile (non-infectious) postoperative endophthalmitis on the 1st and 5th postoperative days (for SMP and PDR groups respectively). This was suggested to be a reaction to the intraoperatively injected intravitreal triamcinolone (after exclusion of microbial causes by culture and sensitivity). Both patients were successfully treated with the use of topical and systemic steroids.

DISCUSSION

Wound sealing related complications as wound leakage and hypotony with choroidal detachment were recorded previously to be the most common complications related to the 25-G TSV (7, 8). Some factors were reported to be protective against or minimize the occurrence of wound sealing complications

following sutureless vitrectomy as the older patient age (18), angled sclerotomy (10, 11), absence of previous vitrectomy,³ minimal peripheral vitrectomy,^{12,13} minimal manipulation, short operating times and small wound size (1, 10-13). On the other hands, straight sclerotomy incision (10, 11), young patients (18), extensive peripheral vitrectomy (12, 13), extensive intraocular manipulation (13, 19), previous vitrectomy (3) and long operation times were reported to be associated with a higher incidence of wound sealing related complications. These risk factors are mostly associated with the complicated vitreoretinal pathologies as PDR and so eyes with PDR are theoretically susceptible to a higher risk of wound sealing related complications. Accordingly it was so important to investigate the incidence of such complications in eyes with PDR and to compare them with a control group as SMP group. In our study, both groups were equal in the presence of some protective factors against hypotony regarding the small wound size, angled sclerotomy and primary vitrectomy. However, risk factors were more in the PDR group regarding the younger patients' age, extensive peripheral vitrectomy, extensive intraocular manipulation and longer operating times which theoretically would expose them to an increased risk of postoperative wound sealing related complications. This was not noted in our study but the reverse happened. Interestingly, the group of the complicated PDR pathology showed a significantly lower incidence of the 1st postoperative day hypotony and wound sealing related complications than the SMP group. The postoperative day 1 was reported previously to have the peak incidence of hypotony and hypotony related complications (20). At the same time the PDR group showed a significantly higher postoperative inflammation and IOP at the same day than SMP group, both were correlated

with each other and with the PDR pathology.

We can explain our results as follows : the postoperative diabetic eye experiences more severe postoperative inflammation than a non diabetic one. Inflammation is one of the important processes in wound healing and some postoperative inflammation is inevitable in any surgery (20). In general, PPV may cause the breakdown of blood-ocular barrier, but the underlying microangiopathy of eyes with PDR may aggravate the postoperative changes due to increased capillary leakage (20, 21) and thus results in much more tissue edema and uveal tract congestion. A stronger inflammatory response was reported to be associated with phacovitrectomy more than vitrectomy alone for diabetic eyes (22). In addition, cataract removal in diabetic patients can upregulate the angiogenic and proinflammatory cytokines in the anterior chamber (23). In our study, other potential causes for short-term IOP rises may include choroidal edema and alterations in ciliary body function related to inflammation (24) which may be aggravated in our study due to the performance of endolaser photocoagulation for all eyes with PDR with a mean number of shots of (1002 ± 678.3) . Endolaser photocoagulation could contribute to IOP elevation in PDR group in the early postoperative period by several possible mechanisms including breakdown of the blood-retinal barrier with leakage of fluid into the eye. Abnormal leakage of fluid into the eye would raise pressure in a manner similar to an increase in aqueous formation (25). A second possible mechanism is a decreased uveoscleral outflow due to congestion of the ciliary body. Laser damage to the short ciliary nerves that innervate the ciliary muscle causing decreased ciliary muscle tone and a resulting impairment of outflow facility may be a third possibility. Finally, IOP rise due to the release of prostaglandins was previously reported (25). The combination of higher postoperative IOP and inflammation may affect wound sealing by the following mechanisms : inflammation leads to uveal congestion which in turn seems to bring the lips of the internal orifice (uveal side) of the sclerotomy incision into a more approximate position, making it narrower than the outer scleral orifice thus, it becomes less prone to leakage. The analysis of our results support this mechanism, as the significantly lower incidence of wound sealing-related complications is evident for PDR group only on the postoperative day one when the postoperative inflammation was at its peak. Once the postoperative inflammation appeared to settle down, eyes with PDR

behaved in a similar way as did those of the SMP group and the IOP drops significantly than preoperative levels at the postoperative day 5. In our study, although the postoperative inflammations in PDR group was also significantly higher than SMP group at the postoperative day 5, its effect did not appear at the 5th postoperative day because it was also significantly lower than the 1st postoperative day inflammation levels for PDR group. The 2nd explanation is that, the higher early postoperative IOP in diabetic eyes due to postoperative inflammation and endolaser photocoagulation as described above increases the appositional forces of the angled sclerotomy. This mechanism is supported by the study of Taban *et al.* (19) when they reported that, there are important variables that contribute to the dynamic morphology of sclerotomies in the early postoperative period, namely the incision angle and IOP which act together to determine the wound structure and thus wound gapping, leakage and endophthalmitis and they found that, angled (beveled) incisions provide better wound apposition under dynamic IOP conditions. In our study, the 1st postoperative day mean IOP was significantly higher in PDR group and high IOP tended to compress against the scleral tunnel from inside making it more angled and more slit-like. Once the effect of endolaser photocoagulation and postoperative inflammation on IOP had gradually subsided, the IOP of PDR group began to follow the natural course of the control group.

Our study also revealed that there was no correlation between the postoperative day 1 IOP and the age of the patient, type of vitreous filling or the preoperative IOP values. In contrast to previous reports that found correlations between wound leakage and both younger patient age (18) and fluid filled eyes (8). this discrepancy in results may be because the relatively younger age in PDR group was not so young but in the middle age. Also the use of angled sclerotomies in all eyes in our study make the effect of vitreous filling on postoperative hypotony and leakage irrelevant. We conclude that, although a stronger postoperative inflammation and a higher IOP tend to occur more in diabetic than in non-diabetic eyes on the 1st postoperative day, they appear to act as a protective factor against the occurrence of postoperative wound sealing-related complications and it means that diabetic eyes are overall exposed to a shorter period of low IOP as these factors increase the likelihood of wound sealing until the point at which natural wound healing takes place

(between 1-2 weeks postoperatively) (19, 26). This study demonstrates a statistical strength over the previously published reports. To the author's best knowledge, this study is the 1st to investigated wound sealing-related complications in eyes with PDR and to compare these results with a control group. It has revealed a new concept regarding the less incidence of such well-known complications related to sutureless vitrectomy in eyes with PDR due to the different postoperative behavior in such eyes. Our results add more information regarding the safety and decreased incidence of the most common complications of 25-G TSV in eyes with PDR. Moreover, the 25-G TSV was done by the same surgeons in both groups thus eliminating operator bias. Further work in this area should involve an anterior chamber optical coherence tomography study of the wound architecture on the day after vitrectomy for PDR and non diabetic patients to confirm the effect of postoperative inflammation on the swelling and approximation of the lips of the internal orifice (uveal side) of the sclerotomy incision as well as the effect of the high postoperative IOP on the modification of the architecture and beveling of the angled incision.

REFERENCES

1. Fujii GY, de Juan E Jr, Humayun MS, Chang TS, Pieramici DJ, Barnes A, Kent D : Initial experiences using the transconjunctival sutureless vitrectomy system for vitreoretinal surgery. *Ophthalmology* 109 : 1814-1820, 2002
2. Yang SJ, Yoon SY, Kim JG, Yoon YH : Transconjunctival Sutureless Vitrectomy for the Treatment of Vitreoretinal Complications in Patients With Diabetes Mellitus. *Ophthalmic Surg Lasers Imaging* 40 : 461-46, 2009
3. Amato JE, Akduman L : Incidence of Complications in 25-Gauge Transconjunctival Sutureless Vitrectomy Based on the Surgical Indications. *Ophthalmic Surg Lasers Imaging* 38 : 100-102, 2007
4. O' Reilly P, Beatty S : Transconjunctival sutureless vitrectomy : initial experience and surgical tips. *Eye* 21 : 518-521, 2007
5. Yanyali A, Celik E, Horozoglu F, Oner S, Nohutcu AF : 25-gauge transconjunctival sutureless pars plana vitrectomy. *Eur J Ophthalmol* 16 : 141-147, 2006
6. Byeon SH, Chu YK, Lee SC, Koh HJ, Kim SS, Kwon OW : Problems associated with the 25-gauge transconjunctival sutureless vitrectomy system during and after surgery. *Ophthalmologica* 220 : 259-265, 2006
7. Byeon SH, Lew YJ, Kim M, Kwon OW : Wound Leakage and Hypotony After 25-Gauge Sutureless Vitrectomy : Factors Affecting Postoperative Intraocular Pressure. *Ophthalmic Surg Lasers Imaging* 39 : 94-99, 2008
8. Gupta OP, Weichel ED, Regillo CD, Fineman MS, Kaiser RS, Ho AC, McNamara JA, Vander JE : Postoperative complications associated with 25-gauge pars plana vitrectomy. *Ophthalmic Surg Lasers Imaging* 38(4) : 270-5, 2007
9. Taylor SR, Aylward GW : Endophthalmitis following 25-gauge vitrectomy. *Eye* 19 : 1228-1229, 2005
10. Shimada H, Nakashizuka H, Mori R, Mizutani Y, Hattori T : 25-gauge scleral tunnel transconjunctival vitrectomy. *Am J Ophthalmol* 142 : 871-873, 2006
11. López-Guajardo L, Pareja-Esteban J, Teus-Guezala MA : Oblique sclerotomy technique for prevention of incompetent wound closure in transconjunctival 25-gauge vitrectomy. *Am J Ophthalmol* 141 : 1154-1156, 2006
12. Shimada H, Nakashizuka H, Mori R, Mizutani Y : Expanded indications for 25-gauge transconjunctival vitrectomy. *Jpn J Ophthalmol* 49 : 397-401, 2005
13. Lakhanpal RR, Humayun MS, de Juan E Jr, Lim JI, Chong LP, Chang TS, Javaheri M, Fujii GY, Barnes AC, Alexandrou TJ : Outcomes of 140 consecutive cases of 25-gauge transconjunctival surgery for posterior segment disease. *Ophthalmology* 112 : 817-824, 2005
14. Phillips WB : Postoperative endophthalmitis in association with diabetes mellitus. *Ophthalmology* 101(3) : 508-518, 1994
15. Shaikh S, Ho S, Preston P, Olson JC, Barnes CD : Untoward outcomes in 25-gauge versus 20-gauge vitreoretinal surgery. *Retina* 27 : 1048-1053, 2007
16. Ibarra MS, Hermel M, Prenner JL, Hassan TS. Longer-term outcomes of transconjunctival sutureless 25-gauge vitrectomy. *Am J Ophthalmol* 2005 ; 139 : 831-836.
17. Jabs DA, Nussenblatt RB, Rosenbaum JT : Standardization of uveitis nomenclature for reporting clinical data. Results of the First International Workshop. *Am J Ophthalmol* 140(3) : 509-516, 2005

18. Pallikaris IG, Kymionis GD, Ginis HS, Kounis GA, Tsilimbaris MK. Ocular rigidity in living human eyes. *Invest Ophthalmol Vis Sci* 46 : 409-414, 2005
19. Taban M, Ventura AA, Sharma S, Kaiser PK : Dynamic evaluation of sutureless vitrectomy wounds : an optical coherence tomography and histopathology study. *Ophthalmology* 115 : 2221-2228, 2008
20. Sakamoto T, Miyazaki M, Hisatomi T, Nakamura T, Ueno A, Itaya K, Ishibashi T : Triamcinolone-assisted pars plana vitrectomy improves the surgical procedures and decreases the postoperative blood-ocular barrier breakdown. *Graefes Arch Clin Exp Ophthalmol* 240 : 423-429, 2002
21. Park SP, Ahn JK, Lee GH : Morphologic changes in the anterior segment after phacovitrectomy for proliferative diabetic retinopathy. *J Cataract Refract Surg* 35 : 868-873, 2009
22. Treumer F, Bunse A, Rudolf M, Roider J : Pars plana vitrectomy, phacoemulsification and intraocular lens implantation. Comparison of clinical complications in a combined versus two-step surgical approach. *Graefes Arch Clin Exp Ophthalmol* 244 : 808-815, 2006
23. Patel JI, Hykins PG, Cree IA : Diabetic cataract removal : postoperative progression of maculopathy growth factor and clinical analysis. *Br J Ophthalmol* 90 : 697-701, 2006
24. Singh CN, Iezzi R, Mahmoud TH : Intraocular Pressure Instability After 23-Gauge Vitrectomy. *Retina* 30 : 629-634, 2010
25. Blondeau P, Pavan PR, Phelps CD : Acute Pressure Elevation Following Panretinal Photocoagulation. *Arch Ophthalmol* 99 : 1239-1241, 1981
26. Gupta A, Schwartz SD : Complications of 25-Gauge Vitrectomy. In Rizzo S, Patelli F, eds. *Essentials in Ophthalmology Vitreo-retinal Surgery*. Springer Inc, Verlag Berlin Heidelberg, 2009, pp.181-185