

ORIGINAL

Transconjunctival sutureless 25-gauge vitrectomy with newly designed microcannulas

Takeshi Naito

Department of Ophthalmology and Visual Neuroscience, Institute of Health Biosciences, The University of Tokushima Graduate School, Tokushima, Japan

Abstract :

Aim : To evaluate the usefulness of the newly designed 25-gauge (25-G) microcannula for transconjunctival sutureless vitrectomy (TSV).

Methods : 25-G TSV was performed on 20 consecutive eyes with the newly designed 25-G microcannulas. We studied usefulness, intraoperative and postoperative complications in these cases .

Results : No complications were recognized during surgery. Postoperative complications included blebs in five eyes, vitreous hemorrhage in one eye, high intraocular pressure (more than 22 mmHg) in one eye and a retinal tear in one eye. No eyes with low intraocular pressure (less than 10 mmHg) were noted.

Conclusions : This microcannula for 25-G vitrectomy is thought to be very useful and effective for performing 25-G vitrectomy safely. *J. Med. Invest.* 55 : 51-53, February, 2008

Keywords : 25-gauge vitrectomy, transconjunctival sutureless vitrectomy, microcannula

INTRODUCTION

Use of the 25-gauge (25-G) transconjunctival sutureless vitrectomy (TSV) system developed by Fujii, *et al.* (1) has recently been advocated (2, 3). Microcannulas for this procedure are thin and the scleral incisions may self-seal without suturing after microcannula removal. However, thin and flexible vitreo-retinal instruments have disadvantages, for example, the thin-walled polyamide microcannulas may be bent or deformed at the time of insertion, making insertion difficult (4). An extensive vitrectomy on the retinal periphery is difficult, and slippage or loss of microcannulas can easily occur. This microcannula is therefore designed to address the disad-

vantages of the polyamide microcannula of the 25-G TSV.

METHODS

Technique

The newly designed microcannula (Duckworth & Kent Inc., Hertfordshire, UK) is made of titanium and has a step to avoid slippage or loss. The internal diameter of the microcannula is 0.55 mm, the external diameter is 0.65 mm, the diameter of the step is 0.75 mm, and the length is 4.5 mm without its head (Fig. 1). The opening of the microcannula is designed for easy insertion of instruments. I performed 25-G TSV on 20 eyes of a consecutive series of 18 patients with this microcannula. The surgical procedure was almost the same as for the 23-G vitrectomy reported by Eckardt (5). The conjunctiva was fixed to the sclera with a fixation ring (Duckworth & Kent Inc., Hertfordshire, UK) and

Received for publication September 10, 2007 ; accepted October 25, 2007.

Address correspondence and reprint requests to Takeshi Naito, MD, Ph.D., Department of Ophthalmology and Visual Neuroscience, Institute of Health Biosciences, The University of Tokushima Graduate School, Kuramoto-cho, Tokushima 770-8503, Japan and Fax : +81-88-631-4848.




Fig. 1. a The newly designed microcannula is made of titanium and has a step to avoid slippage or loss. b The opening of the microcannula is designed for easy insertion of instruments.

the incisions were made by inserting a 25-G micro vitreoretinal blade (Bausch & Lomb Inc., Rochester, USA) at a 30° to 40° angle through the conjunctiva, sclera, and pars plana 3.5 mm from the corneoscleral limbus. The microcannulas were then inserted through the conjunctival incision and into the scleral tunnel using a cannula inserter (Duckworth & Kent Inc., Hertfordshire, UK). The cannula inserter is a blunt instrument holding the microcannula. Vitrectomy was performed through three ports using the microcannulas (Fig. 2). In the cases which combined lens surgery with the 25-G vitrectomy, phacoemulsification with intraocular lens implantation was performed. All incisions self-sealed without suturing. We studied intraoperative and postoperative complications of these cases.

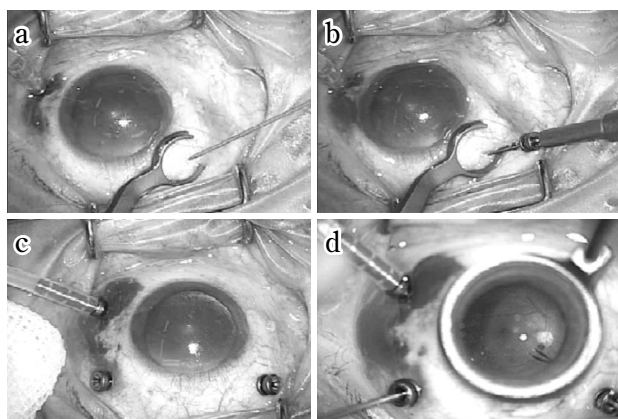


Fig. 2. a The conjunctiva was fixed to the sclera with a fixation ring and the incisions were made by inserting a 25-G micro vitreoretinal blade at a 30° to 40° angle through the conjunctiva, sclera, and pars plana 3.5 mm from the corneoscleral limbus. b The microcannulas were inserted through the conjunctival incision and into the scleral tunnel using a cannula inserter. c, d Vitrectomy was performed through three ports using the microcannulas.

Patients

Informed consents were obtained from all patients before surgery.

25-G TSV was performed on 20 consecutive eyes. The indications for vitrectomy were: proliferative diabetic retinopathy in nine eyes, epiretinal membrane in six eyes and macular hole in five eyes. In 11 eyes, vitrectomy was combined with phacoemulsification and implantation of a posterior chamber intraocular lens. In these cases, the three cannulas were emplaced before phacoemulsification. Four eyes were already pseudophakic. Six eyes received gas tamponade and four eyes received air tamponade at the end of the surgery. The microcannulas were simply removed from the scleral tunnels and the conjunctiva was pushed laterally using a cotton-wool applicator to separate its incision from the scleral incision. A mixture of antibiotic and corticosteroid was injected into the subconjunctival space. The patients were examined daily for the first 5 days after surgery and at 2 weekly intervals thereafter. The follow-up period lasted more than 3 months.

RESULTS

25-G TSV was performed on 20 eyes with the newly designed microcannulas without any problems. No operations were converted to conventional 20-G vitrectomy. Peripheral vitrectomy with scleral indentation could be performed the same way as a 20-G vitrectomy. Intraocular laser photocoagulation to the peripheral retina was performed without any problems. The microcannulas were stable, without slippage or loss during the insertion and removal of instruments, or the peripheral vitrectomy and peripheral laser photocoagulation. No complications were recognized during surgery. Postoperative complications included blebs in five eyes, vitreous hemorrhage in one eye, high intraocular pressure (more than 22 mmHg) in one eye and a retinal tear in one eye. No eyes with low intraocular pressure (less than 10 mmHg) were noted.

DISCUSSION

Use of the 25-G TSV developed by Fujii, *et al.* (1) has recently been advocated (2, 3). The most important advantage of this procedure is the self-sealing without suturing after removal of the microcannu-

las. Some disadvantages have however been recognized when it is compared to the 20-G system (4), the main ones being thin and flexible instruments, difficulty with peripheral vitrectomy, slippage or loss of the microcannula, and reduced efficiency of vitrectomy. The 23-G TSV was developed by Eckardt to address these disadvantages (5), and was thought to be a transitional system until the 25-G TSV was improved. The newly designed microcannula was made of metal to address the disadvantages of the 25-G TSV using the polyamide microcannula. The metal microcannula seemed to be less flexible than the polyamide microcannula. The step of the microcannula was quite effective in preventing slippage or loss. The insertion and removal of instruments through the microcannula, peripheral vitrectomy and intraocular laser photocoagulation with indentation of the sclera were performed safely without any problems. The scleral incisions self-sealed without suturing after removal of the microcannulas in all cases. Surgical procedures were performed the same way as with the 20-G system without any serious complications. Notably, there were few complications during surgery. The reason is thought to be that there is no incarceration of the vitreous during surgery. With the 20-G system, incarceration of the vitreous into the incisions sometimes causes peripheral retinal breaks during the insertion or removal of instruments. In the 25-G system, the insertion or removal of instruments through the microcannula can prevent the occurrence of peripheral retinal breaks. In this case series, retinal break formation was recognized postoperatively. It is not clear if the retinal break formation is an in-

traoperative complication or due to contraction of the residual vitreous postoperatively. This retinal break was well managed with a gas injection and laser photocoagulation without further vitrectomy. This new microcannula is thought to be very useful, effective and safe for 25-G vitrectomy.

REFERENCES

1. Fujii GY, de Juan E Jr, Humayun MS, Pieramici DJ, Chang TS, NgE, Barnes A, Wu SL, Sommerville DN : A new 25-gauge instrument system for transconjunctival sutureless vitrectomy surgery. *Ophthalmology* 109 : 1807-1813, 2002
2. Lakhanpal RR, Humayun MS, de Juan E Jr, Lim JI, Chong LP, Chang TS, Javaheri M, Fujii GY, Barnes AC, Alexandrou TJ : Outcomes of 140 consecutive cases of 25-gauge transconjunctival surgery for posterior segment disease. *Ophthalmology* 112 : 817-824, 2005
3. Ibarra MS, Hermel M, Prenner JL, Hassan TS : Longer-term outcomes of transconjunctival sutureless 25-gauge vitrectomy. *Am J Ophthalmol* 139 : 831-836, 2005
4. Byeon SH, Chu YK, Lee SC, Koh HJ, Kim SS, Kwon OW : Problems associated with the 25-gauge transconjunctival sutureless vitrectomy system during and after surgery. *Ophthalmologica* 220 : 259-265, 2006
5. Eckardt K : Transconjunctival sutureless 23-gauge vitrectomy. *Retina* 25 : 208-211, 2005