

REVIEW

Current status of sentinel lymph node navigation surgery in breast and gastrointestinal tract

Akira Tangoku, Junichi Seike, Kiichiro Nakano, Taeko Nagao, Junko Honda, Takahiro Yoshida, Hiromichi Yamai, Hisashi Matsuoka, Kou Uyama, Masakazu Goto, Takanori Miyoshi¹, and Tadaoki Morimoto²

¹Department of Oncological and Regenerative Surgery, Institute of Health Bioscience The University of Tokushima Graduate School, and ²Department of Adult and Gerontological Nursing, School of Health Sciences, The University of Tokushima, Tokushima, Japan

Abstract : Sentinel lymph node biopsy (SLNB) has been developed as a new diagnostic and therapeutic modality in melanoma and breast cancer surgery. The purpose of the SLNB include preventing the operative morbidity and improving the pathologic stage by focusing on fewer lymph nodes using immunocytochemic and molecular technology has almost achieved in breast cancer surgery. The prognostic meaning of immunocytochemically detected micrometastases is also evaluating in the SLN and bone marrow aspirates of women with early-stage breast cancer.

SLNB using available techniques have suggested that the lymphatic drainage of the gastrointestinal tract is much more complicated than other sites, skip metastasis being rather frequent because of an aberrant lymphatic drainage outside of the basin exist.

At the moment, the available data does not justify reduced extent of lymphadenectomy, but provides strong evidence for an improvement in tumor staging on the basis of SLNB. Two large scale prospective multi-center trials concerning feasibility of gamma-probe and dye detection for gastric cancer are ongoing in Japan.

Recent studies have shown favorable results for identification of SLN in esophageal cancer. CT lymphography with endoscopic mucosal injection of iopamidol was applicable for SLN navigation of superficial esophageal cancer.

The aim of surgical treatment is complete resection of the tumor-infiltrated organ including the regional lymph nodes. Accurate detection of SLN can achieve a selection of a more sophisticated tailor made approach. The patient can make a individualized choice from a broader spectrum of therapeutic options including endoscopic, laparoscopic or laparoscopy-assisted surgery, modified radical surgery, and typical radical surgery with lymph node dissection. Ultrastaging by detecting micrometastasis at the molecular level and the choice of an adequate treatment improve the postoperative quality of life and survival. However these issues require further investigation. *J. Med. Invest.* 54 : 1-18, February, 2007

Keywords : Sentinel Lymph node, Lymphatic mapping, Breast cancer, Esophageal cancer, Less invasive surgery

Received for publication October 10, 2006 ; accepted November 9, 2006.

Address correspondence and reprint requests to Akira Tangoku, Department of Oncological and Regenerative Surgery Institute of Health Biosciences, The University of Tokushima Graduate School, Kuramoto-cho, Tokushima 770-8503, Japan, and Fax : +81-88-633-7144

INTRODUCTION

Sentinel lymph node (SLN) concept was first described in malignant tumor of the parotid by Gould in 1960 (1). The existence of SLN was demonstrated in penile cancer treatment by Cavanis

from the study of lymphangiography and surgical experience (2). The primary cancer cells reach a lymph node near the site of a cancerous tumor. They are filtered, trapped and grow the cancer nests. The node is known as SLN because it acts like a sentry to warn that a patient's cancer is spreading (Fig. 1). Cabanas showed a negative SLN was a predictor of superior survival than positive SLN.

A technique that uses blue dye to map the lymphatic system was developed in the 1980s and applied to the treatment of melanoma. Morton and colleagues showed the efficacy of clinical use of SLN mapping with blue dye for malignant melanoma treatment in the early 1990s (3). Alex, *et al.* established the technique of gamma-probe (GP) -guided localization of the SLN with technetium-99 labeled sulfur colloid and showed the efficacy of SLN biopsy (SLNB) with gamma-probe technique under local anesthesia with preoperative lymphoscintigraphy in malignant melanoma treatment (4).

SLNB has been developed by researchers in several different cancer centers, and has become a widely accepted element in the routine surgical management of breast cancer (5-8).

I. GOAL OF SLNB

For the last century, axillary lymph node dissection (ALND) and histopathological evaluation of the axillary nodes have represented the gold standard for determining the status of the regional lymph nodes, the prognosis, and the appropriate treatment even in early staged breast cancer patients with no lymph node involvement. The purpose of the SLNB

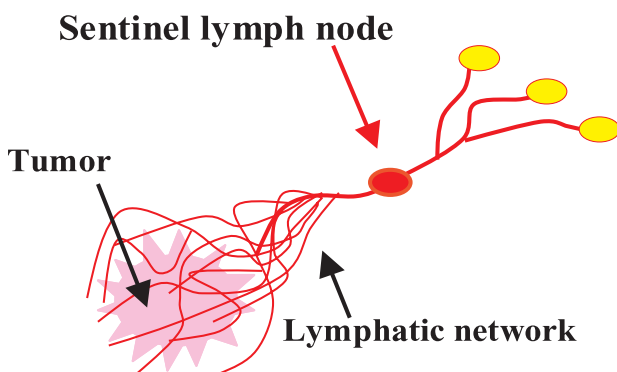


Fig. 1. What is a sentinel lymph node?
The primary cancer cells reach a lymph node near the tumor. They are filtered, trapped and grow the cancer nests. The node is known as sentinel lymph node (SLN) because it acts like a sentry to warn that a patient's cancer is spreading.

include avoiding removal of uninvolved lymph nodes with a standard ALND, preventing the morbidity and improving the pathologic examination by focusing on fewer lymph nodes. The ALND brings about several postoperative complications, like a lymph edema of the arm, discomfort of the axilla, and motor dysfunction. A drainage tube need to be placed for one to two weeks and the patient must undergo physical therapy after ALND. If the SLN was found to contain no cancer cells, the surgeon can abbreviate a full lymph node dissection. In fact SLNB has a significantly lower rate of complications compared to ALND, one study found that only 2.6% of patients who had SLNB developed lymphedema, compared to 27% of patients who had ALND. Another study found that 71% of SLNB patients were able to return to normal activity within 4 days of the procedure, compared to 7% of the ALND patients (9). Mild discomfort, lymphedema and swelling of the arm due to disruption of the lymphatic system can be recognized even after the SLNB procedure. Damage to the nerves in the area of the biopsy, a temporary discoloration of the skin in the area of the dye injection also can be occurred (10).

Another purpose of the SLNB is an improving the accuracy of cancer staging during operation. Cancer staging is a system that classifies malignant tumors according to the extent of their spread in the body. The stage of the patient is determined by the state of LNs. It is used to guide decisions about treatment after the operation. An individualization of therapeutic modality can be chosen. With an intraoperative SLNB, a surgeon can get the information of the spread of cancer to nearby lymph nodes as soon as possible. The patients with SLN metastases may be treated immediately with lymph node dissection.

II. METHODS : How to enhance success rates of SLN identification

i) Tracer and injection site

Proposed SLNB needs a high degree of accuracy with relatively fewer false negative rates. A false negative means that there is cancer in other lymph nodes in spite of the absence of cancer in the SLN. It usually results from either a timing or place of the tracer injection, the detection error of the SLN, or the way in which the pathologist's preparation of the tissue for examination.

As for detection, a surgeon can achieve 95% ac-

curacy with a false-negative rate under 5% in combination with a blue dye and a gamma-probe technique ; peritumoral injection with radioisotopes (RI) including preoperative radiosciintigraphy and subdermal or subareolar injection with blue dye (11, 12). Some studies used intradermal injection of RI in the subareolar lesion and peritumoral dye injection preventing tattoo formation by blue dye. Recent studies recommended subareolar intradermal injection, because it increased success rate of SLN detection both with radioisotope and blue dye (13). Cody, *et al.* reported three variables ; intradermal isotope injection, a positive lymphoscintigraphy and age<60, associated with successful SLN localization by blue dye or by isotope overlap. They emphasized dye and isotope complemented each other, and SLNB should be done with both tracers (14). SLNB is done in two stages. In the first procedure, the patient goes to the nuclear medicine department for an injection of a RI. The radioactive technetium labeled colloid was injected into the area around the tumor by a nuclear medicine with a local anesthetic. A lymphatic mapping with a lymphoscintigraphy is taken before surgery. The patient must wait several hours for the radioactive tracer to flow from the tissues around the tumor to the SLN. Next step is done in the operation room the surgeon injects the blue dye into the area around the tumor, subdermal and/or subareolar. The surgeon then uses a hand-held probe connected to a gamma ray counter to scan the area for the radioactive technetium. The area over the SLN can be pinpointed by the gamma counter. The surgeon makes an incision to remove the SLN. The blue dye that has been injected helps to verify that the surgeon is removing the right node. The tissue is sent to the hospital laboratory for pathological examination. The pathologist makes diagnosis from the frozen sections or imprint cytology. If the SLN was found to contain cancer cells, the surgeon will usually recommend a full ALND.

ii) Mechanism by which the tracer is trapped in SLN

The mechanism by which detects SLN with RI or dye are quite different. Lymph capillaries are lined with a single layer of endothelial cells with openings 10-25 nm wide. These openings permit the entrance of small particles like blue dye. Larger particles such as nanocolloid enter the lymph system more slowly by active pinocytosis. Lymph flow is generated by lymph formation, active contraction of the lymph channel and external interstitial

pressure. Lymph formation and interstitial pressure are influenced by the volume of the injected tracer. This may at least partly account for the variation in the detection rates found in studies injecting different tracer volumes.

A commonly used tracer is 99m Tc-radio-labeled colloidal albumin (Nanocoll, particle size under 80nm) in Europe, whereas the most commonly used in USA is 99mTc radio-labeled sulphur colloid, which is characterized by its larger particle size. Migration kinetics and uptake in LN of different colloids can vary considerably according to the particle size (15). Radio-colloid is retained in the LN through active saturable phagocytosis by antigen presenting cells lining the sinusoid spaces (16). Prerequisite for this uptake is a negative surface charge and preliminary opsonisation by a variety of proteinaceous compounds e.g., C3, C4B and C5 (17). The capacity of radiocolloid retention also seems to be determined by the grade of malignant infiltration. Several authors reported that false-negative LN showed extensive tumor infiltration. Following their theory, tumor-free SLN or SLN harboring small number of malignant cells will take up radio colloid normally. If numerous tumor cells infiltrate the LN, radiocolloid uptake is reduced. After complete infiltration and destruction of the nodal reticuloendothelial system and in cases of malignant obstruction of the afferent lymphatic vessel, tracer uptake will be abolished.

Although direct priming of the anti-tumoral immune response can occur directly in the tumor under certain conditions, it is an established consensus that cross priming in lymphoid organs is an important step in the induction of tumor rejection. From the immunological concept, the SLN may be the place of cross-presentation of tumor-derived antigens to the immune system. This lymphoid organ may thus be essential for the induction of an effective immune response (18, 19). Recent study showed that cellular immune response appeared to be less active in SLNs compared with non SLNs. Once metastasis was established in SLN, dendric cell maturation was triggered and followed by the up-regulation of Th-1 responses, which may reflect antigen-specific immune responses in SLN (20).

Blue dye is not assumed to be phagocytosed. Its capacity to enter and remain in the lymphatic seems to be determined by the presence of at least one sulphonic acid group, resulting in optimum protein binding conditions. Patent blue is the most

commonly used dye in Europe. Isosulfan blue dye (Lymphazurin : US Surgical Corp.) is used in USA. Evans blue, methylene blue, indigo carmine, indocyanine green (ICG) and other dyes have also been inject by investigators. Soluble dyes, like Evans blue, patent blue, and ICG are bound to endogenous protein by sulphonation and thus trapped within lymphatic capillaries (21, 22). Since dye migration toward the SLN through the lymph channel is quite fast, the prolonged preparation time increase blue staining of secondary, third and sequential nodes. A traumatic preparation may result in the rupture of the afferent lymphatic channel and diffuse contamination of the operative field compromising any further detection of the SLN. Alternative lymphatic drainage is difficult to visualize by this method. Allergic incidents of varying severities were reported in up to 1.5% (23).

iii) Lymphatic anatomy of the breast and internal mammary route

Preoperative lymphoscintigraphy is most useful for detecting an internal mammary SLN. But the internal mammary route image is not detected always. Tracer injected to the superficial skin including within the breast gland mostly migrates through the superficial pathway to the axillary basin. In contrast, the tracer injected superficial in combination with deep breast gland migrate through both the superficial and retro mammary lymphatic pathways. Therefore subtumoral injection (retro mammary pathway) of radio-colloid in combination with peritumoral, dermal, or periareolar injection (superficial pathway) might be clinically useful in eliminating false-negative results. But the practicability of internal mammary SLN biopsy is still in the investigative stage (24). The draining lymphatic vessels usually are not visible because of slow migration of radio-colloids, and the location of SLN cannot be determined accurately because of low spatial resolution of scintigram. Resected SLNs often have radioactivity that is less than the detection sensitivity of the GP (25).

iv) Computed Tomography Lymphography (CT-LG)

In Japan, use of RI is strictly limited in the special facilities. The preparation of radiotracer needs cost and time. The blue dye-method is inexpensive compared with the use of radiotracer. Therefore, the blue dye method became more popular in Japan. But the technique is a strictly intra-operative. Detection of correct SLNs needs an experience and a

technical learning curve.

We have developed a new, simple, and inexpensive technique of SLN navigation that uses a commercially available, water-soluble contrast medium iopamidol (26, 27). We believe that interstitial CT-LG with iodinated contrast agents addresses the disadvantages of the RI/dye methods by allowing quick visualization of the direct connection between the primary SLN and its afferent lymphatic channel and by providing detailed anatomy of breast lymphatic basin on high-resolution cross-sectional three-dimensional (3D) CT (Fig. 2). The contrast agent rapidly migrates from the interstitial space to the lymphatics similarly to other water-soluble, low-molecular-weight solutes and it has been proven to be safe and to be tolerated well even when extravasated. Although the exact mechanisms of iopamidol uptake and transport in the lymphatic system are unknown, this agent appears to easily penetrate into the lymphatics through clefts in the terminal lymphangioles of the interstitial space. The relatively long duration of nodal enhancement by iopamidol may be related to its slow transit and sequestration in the nodal sinusoids. Gentle massage of the injection sites facilitates migration and nodal accumulation of iopamidol, and this procedure is advantageous for shortening the examination time. Although iopamidol may partly drain

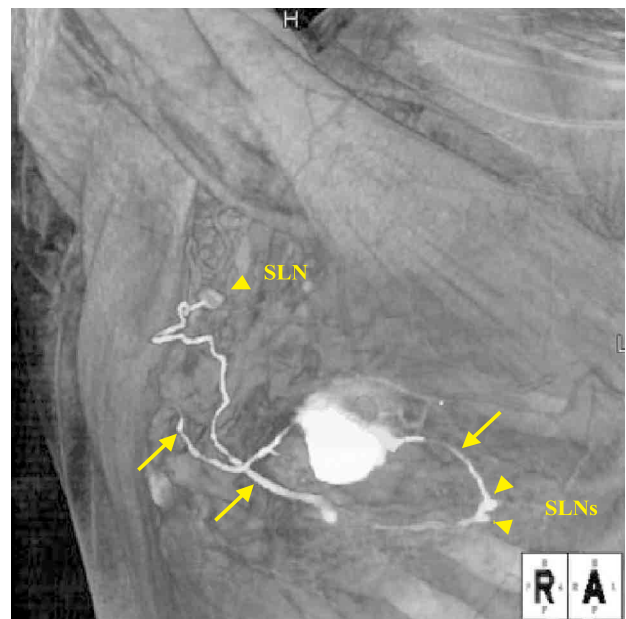


Fig. 2. 3D CT lymphography of breast cancer
CT lymphography with iodinated contrast agents addresses the disadvantages of the RI/dye methods by allowing quick visualization of the direct connection between the primary SLN and its afferent lymphatic channel (arrows) and by providing detailed anatomy of breast lymphatic basin on high-resolution cross-sectional three-dimensional (3D) CT.

into the venous system, this volume appears to be negligible when iopamidol is used in the breast because we observed no noticeable venous enhancement. Following CT-LG, the contrast-enhanced computed tomography to evaluate distant metastases is obtained with shortening the pre-surgical examination schedule. Guided by these CT-LG images, SLNB is easily performed during a minimally invasive procedure (28, 29). Overall, the sensitivity, false-negative rate, and accuracy of CT-LG navigated SLNB were 92%, 7%, and 98%. Drainage lymphatic pathways on these images were classified into four patterns, single route/single SLN (57%), multiple routes/single SLN (15%), single route/multiple SLNs (13%), and multiple routes/multiple SLNs (15%) (29). False negative results might have occurred due to missing the multiple lymphatic routes from peritumor and subareolar injection site.

In case of extensive tumor infiltration, the primary SLN may not accumulate any markers because of mechanical obstruction by tumor infiltration, and alternate nodes may become sentinel as a result of lymph flow rerouting. Even in such cases, the detailed view of the lymphatic anatomy provided by our CT-LG technique allows accurate interpretation on the basis of the SLN pattern and lymph vessel staining (28).

SLN detection using the fluorodeoxyglucose positron emission tomography (PET-CT) is also available to detect SLN metastasis, small number of distant metastasis and synchronous other malignancies (30).

III. SENTINEL LYMPH NODE BIOPSY : technique and pitfall

The accuracy of SLNB depends greatly on the skill of the surgeon who removes the node. Recent studies indicate that most surgeon need to perform 20-30 SLNBs before they achieve an 85% success rate in identifying the SLNs and 5% or fewer false negatives (11). They can obtain the necessary experience through special residency programs, fellowships, or training protocols. They emphasized this method had several potential advantages to an invasive method using blue dye which needs to dissect the subcutaneous adipose tissue widely to visualize the blue nodes ; it can precisely detect the position of an underlying SLN from the surface of the skin, and guide the surgeon to the SLNs during dis-

section. It also can determine the possible presence of residual nodes to be harvested rapidly through a small incision as opposed to raising a skin flap with ease.

SLNB is preferable for patients with no axillary LN metastasis (N0) regardless of size of breast tumor. SLNB is also indicated for the patients with wide spreaded ductal carcinoma in situ (DCIS) detected as a palpable mass or those with large calcification areas in the breast (31). Some cancer patients should not be given an SLNB. They are such women who have cancer in more than one part of the breast, who have had previous breast surgery, including plastic surgery, women with breast cancer in advanced stages, and women who have had radiotherapy. The patients who have undergone wide excision (removal of surrounding skin as well as the tumor) of the original skin cancer are also not candidates for an SLNB. Obesity and preoperative chemotherapy also decrease the identification rate and increase the false-negative rates (11, 12, 32). If the SLN is missed even with the radiotracer in combination with dye method, Carmon and colleagues recommend a systematic palpation of the axilla after RI and dye detection reduces the false-negative rate (33).

Since surgeons around the world have adopted SLNB, consistency of technique and case selection has attained great significance. The accuracy of SLNB after neoadjuvant chemotherapy is considered to be unproven (34).

IV. PATHOLOGICAL EXAMINATION : accuracy of SLN status and “false negative report”

Intraoperative diagnosis of SLN is useful because patients with SLN metastases may be treated immediately with ALND, but the best method for pathologic examination of the SLN remains controversial. Rubio (35) and Motomura (36) showed the efficacy of intraoperative touch or imprint cytology in finding micro metastasis. However, intraoperative techniques such as cytological examination and frozen section lack sensitivity, and can result in loss of up to 50% of the SLN tissue (37).

For years there was a speculation that micro metastases in axillary lymph nodes were clinically insignificant and thus lymph nodes did not require sectioning at close intervals. Yet essentially all studies, including a recent large prospective study, have found a significantly poorer prognosis

associated with metastases less than 2 mm in size which is the most common definition of micro metastasis, therefore even such small metastases cannot be safely overlooked. The use of immunohistochemistry (IHC) to detect keratin proteins will reveal metastatic breast carcinoma in about 18% of axillary lymph nodes that appear negative on routine stains. The preponderance of evidence to date suggests a significantly poorer prognosis in patients with such occult metastases, although data from large prospective studies are lacking. Molecular techniques such as reverse transcriptase-polymerase chain reaction (RT-PCR) offer even more sensitive methods for detecting occult metastasis in SLNs, although false positives are a particular problem in techniques that do not permit morphologic correlation, and for now they remain a research tool (37).

V. ONGOING CLINICAL STUDY

The National Surgical Adjuvant Breast and Bowel Project (NSABP) B-32 started to randomize women to SLNB followed by a standard level I and II axillary dissection or SLNB without dissection unless metastatic disease is noted by H&E examination in May 1999 (38). Overall survival, disease-free survival, and morbidity will serve as end points. Further pathologic evaluation of the lymph nodes with immunohistochemistry will be performed by the study center. The trial opened recently concerning educational program in a prospective fashion. Two hundred twenty-six registered surgeons underwent site visit training by a core surgical trainer and 187 completed training and were approved to randomize patients on the trial. The results of 815 training (nontrial) cases demonstrated a technical success rate for identifying SLN at 96.2% with a false negative rate of 6.7% (39). Another randomized control study (the ALMANAC Trial) comparing arm and shoulder morbidity and quality of life of outcomes between patients with clinically node-negative invasive breast cancer who received SLNB and patients who received standard axillary treatment showed that SLNB is associated with reduced arm morbidity and better quality of life than standard axillary treatment (40). American College of Surgeons Oncology Group (ACOSOG) Z0010 is a prospective multicenter trial designed to evaluate the prognostic significance of micrometastases immunocytochemically detected in the SLN and bone marrow aspirates of women with early-stage breast

cancer (41). Surgical outcomes were reported as a validation of the trial at 30 days and 6 months after surgery for 5327 patients with clinical T1/2 N0 M0 breast cancer. Patients who had a failed SLN mapping (n=71 ; 1.4%) or a completion lymph node dissection (n=814 ; 15%) were excluded. Univariate and multivariate analyses were performed to identify predictors for the measured surgical complications. And in patients who blue dye alone (n=783) or a combination of radiocolloid (n=4192), anaphylaxis was occurred in the patients received isosulfan blue dye was reported in 0.1% of subjects (5 of 4975). Other complications included axillary wound infection in 1.0%, axillary seroma in 7.1%, and axillary hematoma in 1.4% of subjects. Only increasing age and an increasing number of SLN removed were significantly associated with an increasing incidence of axillary seroma. At 6 months, 8.6% of patients reported axillary paresthesias, 3.8% had a decreased upper extremity range of motion, and 6.9% demonstrated proximal upper extremity lymphedema (change from baseline arm circumference of > 2cm). Significant predictors for surgical complications at 6 months were a decreasing age for axillary paresthesias and increasing body mass index and increasing age for upper extremity lymphedema (42). ACOSOG Z0011 randomizes women undergoing breast-conserving therapy with low-volume axillary disease to completion ALND or observation. Overall survival, disease-free survival, local regional control, and morbidity serve as end points. This trial is currently enrolling patients.

VI. SLNB OF THE OTHER NEOPLASM

i) Application of gynecologic, urologic, head and neck, and lung cancer

Clinical applications of SLNB have been performed with the aim of defining the rationale, the methods of detection, the accuracy, and the current indications to SLNB in different solid neoplasms (43). In gynecologic malignancies, appreciable results are available in patients with vulvar and uterine cervical cancer only. Patients with squamous cell vulvar cancer may benefit by SLNB because a complete bilateral inguino-femoral lymph-node dissection may be avoided whenever the SLN is free of metastasis (44). As regards to cervical cancer, further studies are required with the combined blue dye and GP guided surgery, which seems more prom-

ising, before abandoning pelvic lymphadenectomy in patients with histologically-negative SLN (45). The experience in urologic cancer deals mainly with penile and prostate cancer ; the modern procedures for the dynamic detection of SLN are going to clarify its role in the surgical management of penile cancer and bladder cancer (46). These preliminary results suggest that the SLNB may enhance the pathologic staging of these neoplasms compared to modify pelvic lymphadenectomy, due to the individual variability of the lymphatic drainage of these cancers. Laparoscopic minimally invasive surgery is technically feasible with SLNB as a tool for staging of intermediate and high risk prostate cancer (47). In patients with clinically node-negative squamous head and neck cancer, the reliability of SLN-guided neck lymph node dissection seems promising. SLNB represents a standard procedure for staging purpose in melanoma patients, although its therapeutic value is still under examination (48). The SLNB is also technically feasible in patients with differentiated thyroid cancer. However, the future role of this procedure in the clinical decision-making of patients with thyroid cancer remains to be defined due to the questionable biological meaning of nodal metastases (49). Patients with non-small-cell lung cancer should be investigated by means of radiotracers injected at the time of thoracotomy or under CT-scan guidance in order to achieve a satisfactory identification rate (over 80%) ; the focused histopathologic staging of the SLN improves current pathologic staging by conventional assessment of all the lymph nodes of the surgical specimen ; moreover, the prognostic role of isolated N2 metastasis can be better elucidated (50).

ii) SLNB in gastrointestinal tract

1) SLNB in colorectal cancer

In patients with gastrointestinal (GI) malignancies, the intraoperative lymphatic mapping with SLNB using available techniques have suggested that the lymphatic drainage of the GI tract is much more complicated than other sites, skip metastasis being rather frequent. Unpredictable drainage patterns, high background signal, and the inability to image lymphatic tracers relative to surgical anatomy in real time increased false-negative rate of GI malignancies (Fig. 3). In malignant melanoma or breast cancer, SLNB can reduce the invasiveness of the surgical therapy by improving the patient's nodal staging, with subsequent restriction of unnecessary LN dissections in nodal-negative

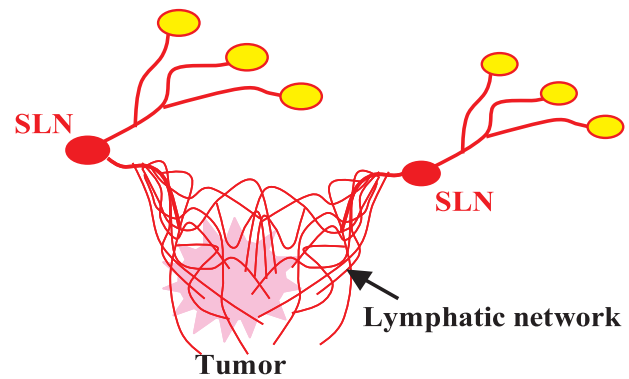


Fig. 3. Problem of SLN navigation in gastrointestinal tract. The lymphatic drainage of the GI tract is much more complicated, skip metastasis being rather frequent. Unpredictable multi-centric drainage patterns, and the inability to image lymphatic tracers relative to surgical anatomy increase the false-negative rate.

patients. By contrast, in most cases of colorectal cancer, the extent of the surgical procedure will remain unchanged by the results of the SLN mapping, since all regional LNs are routinely removed en bloc with the resected bowel segment.

As regards to colorectal cancer patients, the focused analysis of the SLN may reveal disease that might otherwise go undetected by conventional surgical and pathological methods, and those patients which are upstaged can benefit by adjuvant chemotherapy.

In present practice, 20-30% of nodal-negative patients will develop locoregional or systemic disease (51). Adjuvant chemotherapy can significantly improve the 5-year survival of patients with node-positive colorectal cancer (51-53). This emphasizes the importance of the correct LN staging as prognostic factor as well as criteria for patient selection for adjuvant or neoadjuvant therapy (53, 54). Several techniques have been reported to improve LN detection in surgical specimens by LN revealing solutions or fat-clearing methods (55, 56).

Unfortunately, these techniques are labor-intensive. Modern diagnostic methods like immunohistochemistry and RT-PCR can increase the sensitivity of detection of even micrometastatic disease. However, these techniques are also labor- and cost-intensive and thus inappropriate for large-scale application on all LNs found in the surgical specimen. The restriction of the refined histopathological examination to intraoperatively suspicious or enlarged LNs is also not useful, since 69% of metastatic nodes are smaller than 5 mm in size (57). SLNB may constitute a method to limit the use of the full range of very sensitive histopathological

techniques, like serial sectioning, immunohistochemistry and RT-PCR, to the SLN with the highest probability of metastatic involvement.

Published studies on SLNB in colorectal cancer showed considerable heterogeneity in the detection techniques used, in the practical definition of the SLN, in the time interval chosen between dye injection and SLN-detection, in the histopathological techniques applied and in the composition of the patient groups. Consequently, the detection rate, sensitivity and rate of false-negative LNs vary considerably.

Most SLNB trials in colorectal cancer have used intraoperative subserosal injection of blue dye method. However, metastasis was found more frequently in the blue/hot LNs than in blue-only LNs (58).

Several authors have reported the feasibility of ex vivo SLN-detection with detection rates and sensitivities comparable to the in vivo technique (59-61). This postoperative approach may reduce the operation time needed for classical detection and the potential risk of dislodging tumor cells through manual manipulation. But aberrant lymphatic drainage cannot be detected by this method (59). Intraoperative SLN mapping can identify aberrant lymphatic drainage outside of the field of the planned resection. It has been reported to be present in 2-8% of patients with colon cancer (62, 63). This may be due to partial obstruction of the lymphatic channels by tumor cells with consecutive blockage of tracer migration. In these cases, an understaging of the primary disease may have occurred, either due to an incomplete harvest of LNs or inadequate histopathological evaluation. The number of SLNs that have to be submitted to obtain a reliable nodal staging remains the subject of debate. Recommendations for LN retrieval vary between six and 17 (64).

In general, the rate of false-negative SLNB increases with the size and depth of infiltration (pT) of the primary tumor. But the data could not establish a correlation between tumor infiltration and the rate of false-negatives (65).

The improved nodal staging by means of SLN mapping and subsequent selective application of immunohistochemical staining and RT-PCR techniques results in an upstaging of up to 46% for patients with micrometastasis (63, 66-78). In RT-PCT detection, the multimarker approach presented some advantages over the classical single marker approach, since it eliminates some classical problems caused

by tumor heterogeneity, loss of expression of tumor markers, clonal selection and unspecific positive results due to low level antigen expression in non-malignant tissue (63, 79-81). However SLNB and the consecutive intensified histopathological work-up of the SLN may improve the quality of the staging of colon cancer, the question persists whether the presence of micrometastasis detected by immunohistochemistry is a prognostic indicator for disease-free and overall-survival in patients staged node-negative by routine HE-staining. Some studies reported a significant survival benefit for patients without micrometastasis (68, 69), whereas others could not detect any difference in disease-free survival between patients with or without micrometastatic SLN involvement (69-78). Histopathological ultrastaging may also lead to a considerable reduction in the SLN false-negative rate (63). However, as long as the non-SLNs are not examined with the same sensitive techniques as for the SLN, no definitive conclusion on this reduction of false negative rate can be drawn.

The growing acceptance of laparoscopic colectomy for colorectal cancer has raised the question of whether SLNB can be applied in laparoscopic procedures. Recent small number of studies about laparoscopic SLNB procedures, showed an acceptable detection rate and sensitivity (82-84). Bilchik and colleagues published a series of 30 patients undergoing laparoscopic SLNB. The detection rate was 100%, accuracy was 93%, but the false-negative rate was relatively high (33%), since there were quite a low number of patients with nodal disease (six patients ; 20%). Interestingly, in eight cases, aberrant lymphatic drainage was detected (85).

SLNB has been shown to be less reliable in rectal cancer compared to colon cancer (86, 87). The false-negative rate was 56% from the study of Schlag, *et al* (88). There was no statistical difference between patients with early and advanced tumor stage, but many patients suffered advanced tumor stage in this series. The extremely high false-negative rate was thought to be due to the close vicinity of SLN in the pararectal tissue to the primary tumor (shine-through phenomenon) as well as the effects of neoadjuvant radio-chemotherapy. Therefore early staged tumors are good object for SLNB in colorectal cancer.

2) SLNB in gastric cancer

The optimal extent of lymphadenectomy in gastric cancer is still under discussion and is thought

to vary with the individual characteristics of the primary tumor, i.e., location, depth of invasion, maximal diameter, macroscopic and histological type (89). From the study of the patients who underwent curative gastrectomy for carcinoma, none of the patients with mucosal tumors had lymph node metastases while 18 (20%) submucosal tumors were node positive. This data support the use of conservative limited surgical procedures for appropriate patients with mucosal gastric cancer. Patients with submucosal lesions require the same treatment approach as those with more advanced gastric cancer unless clinical usefulness of SLNB will be established (90).

The lymphatic drainage of the stomach is considerably more complex than that of ectodermal organs like breast and skin due to the complex embryological development. Frequency of skip metastasis is as high as 15-20% (88, 91). Because many gastric tumors also spread by way of lymphatics, histological assessment of the first draining lymph nodes has both prognostic and therapeutic significance. All regional LNs are routinely removed en bloc with the resected segment. Value of the SLNB is still controversial.

During the past two years, a growing number of clinical trials evaluating the feasibility and accuracy of SLNB in gastric cancer have been published. Results of the trials with the largest patient numbers are summarized in recent literature (88, 92-100).

In summary, these clinical trials showed a higher percentage of false-negative results than use of SLNB in melanoma or breast cancers. Moreover, the number of patients with SLN as the only LN with metastatic involvement is lower than in the aforementioned tumor types. The number of SLNs per patient is 2-7, it varies significantly according to the techniques of SLN definitions employed by the authors (95, 97, 101). It has been considerable debate on the advantages and disadvantages of different detection methods, radiocolloid and vital dye. While early studies of SLNB preferred the vital dye method, a growing number of investigators used radiocolloid or a combination of both methods in more recent studies. Uenosono and colleagues examined the influence of particle size of radiocolloids on the detection rate. Uptake of large size (500 nm) of radiocolloids was reduced compared with that of smaller particle sizes (50 and 100 nm). Thus, the authors recommend the use of radiocolloids with particle sizes of around

100 nm (102). Hayashi and colleagues compared blue dye and radiocolloid. Each method had detection rates of 90%, whereas the combination of both techniques achieved a detection rate of 100%. The false-negative rate was 14% in the blue dye and 29% in the radiocolloid group, and the combination of both techniques resulted in a reduction of the false-negative rate to 0% (99). Consequently, the authors consider both techniques as complementary and recommend their combined use. The recent articles also recommends combination because of dye-technique salvaged the missing SLN due to the shine-through effect (103). At the moment, the available data does not justify reduced extent of lymphadenectomy on the basis of SLNB in gastric carcinoma, but provides strong evidence for an improvement in tumor staging using this procedure (88). Only clinical stage T1N0 gastric cancer seems to be a good entity to try to change the therapeutic approach based on the SLNB (104). The SLNB can be a procedure not only for accurate staging by detecting micrometastasis using immunohistochemistry and RT-PCT technique but also a great tool to change the patient care of GI cancer by individualized minimally invasive treatment including laparoscopic approach (93, 105, 106).

At present, two large-scale prospective multi-center trials are on going in Japan. The Gastric Cancer Surgical Study Group of the Japan Clinical Oncology Group (JCOG) organized a multi-center prospective study of SLN mapping by the dye-guided method using subserosal injection of indocyanine green. If the JCOG study reveals favorable results, in terms of false-negative rates, the dye-guided method will be utilized as a routine practice for open surgery in a wide range of institutions. If not, we should introduce radioguided method or add further technical improvements, even for open surgery. A study group in the Japan Society of Sentinel Node Navigation Surgery (SNNS) is also conducting a multi-center prospective trial of SLN mapping by a dual tracer method with blue dye and radioactive colloid. Feasible study of laparoscopic SLN mapping for gastric cancer will be conducted as the next step. The results of these clinical trials will provide useful perspectives on the future direction of SLN navigation surgery for gastric cancer (107). Laparoscopic local resection for superficial gastric cancer with negative SLN status would be a reasonable and less-invasive novel procedure based on the SLN concept. However, further prospective studies are needed to confirm the findings

of the aforementioned studies in larger patient groups.

3) SLNB in esophageal cancer

The esophagus that lacks the serosa with extended lymphatic networks in the lamina mucosa and submucosa exists in the mediastinum. It involves a large number of lymphatic organs, the trachea, the aorta, the other important vessels and nerves in the narrow space. The lymphatic drainage of the esophagus is complex and early spreads of regional LN stations are located in different anatomical sites.

The two most frequent malignancies of the esophagus, adenocarcinoma and squamous cell carcinoma (SCC), seem to differ in their characteristic metastatic pattern. Although the location of the primary tumor has a strong influence on the site of metastasis in SCC, early tumors of this type most frequently metastasize to perigastric LN basins or the LNs at the thoracocervical junction (108).

Early diagnosis, development of multimodal treatment like endoscopic mucosal resection (EMR) (109, 110), standardization of the surgical procedure including routine lymph node dissection (110-112), and improved perioperative management of patients have led to a better survival for patients with esophageal SCC (113).

However, clinical results of EMR are not satisfactory because of early occurrence of lymph node recurrence even in superficial esophageal cancer.

Metastasis even to distant anatomical LN stations appears frequently and metastatic disease may be present in up to 35% of submucosal tumors (113).

Traditional curative trans thoracic esophagectomy are associated substantial morbidity and mortality (114). Another report showed more than 77% of patients with superficial esophageal cancer has no nodal metastases (115). Such extensive operation should be avoided in patients without lymph node metastasis to reduce morbidity and mortality. Accurate SLN mapping and biopsy examination could contribute to a less invasive operation and reduction of postoperative complications. (116).

Therefore, these patients with superficial esophageal cancer may profit from improved staging by SLNB (106, 117). Two larger trials investigated the practical application of SLNB in esophageal cancer. Recent studies have shown favorable results using an endoscopic scintigraphic method with radionuclide-labeled colloids and intraoperative gamma-probe counting for identification of SLNs

in esophageal cancer.

Kato and colleagues reported detection rates of 92% using technetium 99 m colloidal rhenium sulphide injected endoscopically in 25 patients. The sensitivity of the procedure was 86.7%. In two patients with advanced disease, nodal metastasis was not detected by SLNB, resulting in a false-negative rate of 13.3%. Fifty percent of patients with negative LNs on routine HE staining, including both patients with false-negative SLNs, had micrometastasis detected by immunohistochemistry (118). Yasuda *et al.* reported on 21 SLNB performed in patients with esophageal cancer. The detection rate was 100%, the false-negative rate reached 25%. Two of the three patients with nodal metastasis that was not detected had advanced tumor stages (119).

In contrast, the first involved LN of Barrett's esophagus was most frequently located in the lower posterior mediastinum, the right or left paracardiac region or along the lesser gastric curvature in early stages of esophageal adenocarcinoma. Skip metastasis occurred in only 5% of patients (120).

Burian and colleagues reported the applicability of SLNB to patients with Barrett's and cardiac cancer. Twenty patients were studied with technetium colloid preoperatively, ten received an additional intraoperative injection of blue dye. The detection rate was 85%. The accuracy of the method varied between 100% and 75%, with reduced values for Type I and II tumors. They indicated that the method is, even in this anatomical area, feasible and yields good results in early tumors. In advanced tumors, the method lacks sensitivity. Mapping should be done with blue dye combined with a radiocolloid (121).

Mapping with vital blue dyes or technetium 99m often fails to identify intrathoracic sentinel lymph nodes. Rapid transit of blue dye through the lymph node chain limits its use at the time of operation, and blue-staining SLN and lymphatic vessels often are not visualized clearly among anthracitic mediastinal nodes (119). There is also the risk for labeling non-SLN because of further migration of radiocolloids to subsequent distant LNs; the LNs with the highest radioactivity are not necessarily defined as SLN. Preoperative imaging and intraoperative detection of SLN is difficult when the node is close to either the injection site or physiologically radioactive liver because of the shine-through phenomenon (119).

To overcome these problems, feasibility of fluorescent microspheres (124), near-infrared fluorescence

(123), invisible light (124) which provides highly sensitive, real-time image-guided dissection, a sonographic contrast agent (i.e., lymphosonography) (125) and lymphoseek which was a radio-pharmaceutical designed product characteristic of rapid injection site clearance, detectable SLN uptake, and low second-echelon node uptake (126) have been investigated. However these intraoperative methods cannot predict the accurate localizations of primary SLNs preoperatively, because of the limited spatial resolution of images and the lack of the detailed anatomy of the surrounding structures. Therefore use of magnetic resonance (MR) lymphangiography and carbon dye (Gadomer/carbon dye mixture) is also studying (127).

We showed an interstitial CT lymphography with endoscopic mucosal injection of iopamidol was applicable for SLN navigation of superficial esophageal cancer. It appears to allow accurate identification of direction and location of lymph flow and SLNs in surrounding anatomy on the high-resolution images (Fig. 4 A, B). Under guidance using the detailed anatomy on CT-lymphography images, these SLNs could be found at the image guided predicted location (128). Less invasive therapeutic selection including mediastinoscope-assisted transhiatal esophagectomy, which avoid morbid thoracotomy (129) or the preservation of the esophagus by using EMR and SLNB could be realized soon.

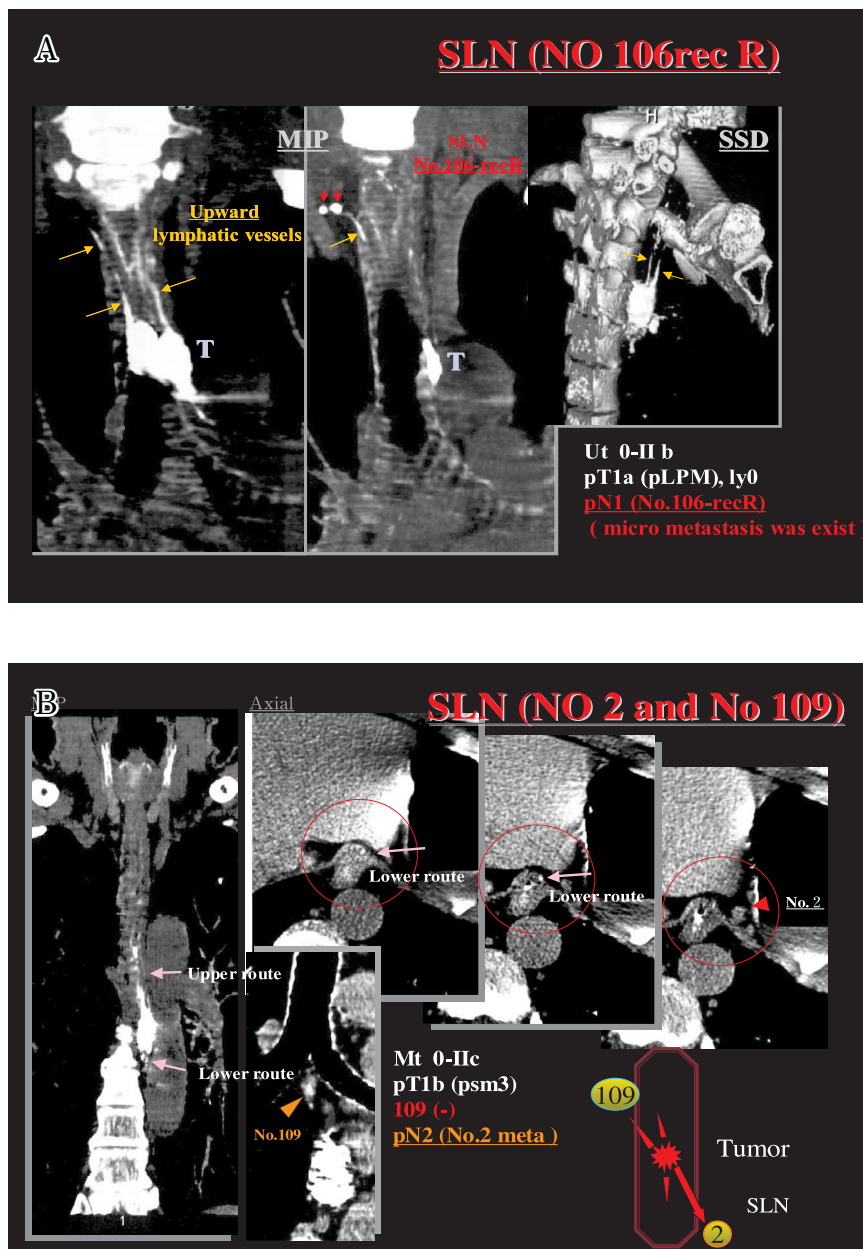


Fig. 4 A B. 3D CT lymphography of esophageal cancer
CT lymphography with endoscopic mucosal injection of iopamidol was applicable for SLN navigation of superficial esophageal cancer. It appears to allow accurate identification of direction and location of lymph flow (arrows) and SLNs (arrow heads) in surrounding anatomy on the high resolution images (Ref. No 128).
A : Upward lymphatic route and two SLNs (No 106 rec R) are enhanced by CT lymphography.
B : Upward and Downward lymphatic routes and SLNs (No 109 and No 2) are enhanced by CT lymphography.

CONCLUSION

The aim of surgical treatment is complete resection of the tumor in all dimensions of its growth. This can be achieved by resection of the tumor-infiltrated organ including the regional lymph nodes. But the extent of lymph node dissection is still under discussion. Current trends in the treatment of solid tumor indicate the emergence of a more sophisticated approach, with tailor made therapy applied to individual cases. Accurate detection of SLN can achieve a selection of not only a minimal invasive curative surgery, but also a broader spectrum of therapeutic options including EMR, laparoscopic or laparoscopy-assisted surgery, modified radical surgery, and typical radical surgery with lymph node dissections. Ultrastaging by detecting micrometastasis at the molecular level using immunohistochemical and RT-PCR and the choice of an adequate treatment improve the post-operative quality of life and survival. These issues require further investigation.

REFERENCES

- Gould EA, Winship T, Philbin Ph, Kerr HH : Observations on "sentinel lymph node" in cancer of the parotid. *Cancer* 13 : 77-78, 1960
- Cabanas RM : An approach for the treatment of penile carcinoma. *Cancer* 39 : 456-466, 1977
- Morton DL, Wen DR, Wong JH, Economou JS, Cagle LA, Storm FK, Foshag LJ, Cochran AJ : Technique details of intraoperative lymphatic mapping for early-stage melanoma. *Arch Surg* 127 : 392-399, 1992
- Alex JC, Weaver DL, Fairbank JT, Rankin BS, Krag DN : Gamma-probe-guided lymph node localization in malignant melanoma. *Surg Oncol* 2 : 303-308, 1993
- Krag DN, Weaver DL, Alex JC, Fairbank JT. Surgical resection and radio-localization of sentinel node in breast cancer using a gamma probe. *Surg Oncol* 2 : 335-340, 1993
- Giuliano AE, Kirgan DM, Guether V, Morton DL. Lymphatic mapping and sentinel lymphadenectomy for breast cancer. *Ann Surg* 220 : 391-398, 1994
- Veronesi U, Paganelli G, Galimberti V, Viale G, Zurrida S, Bedoni M, Costa A, de Cicco C, Geraqhty JG Luini A, Sacchini V, Veronesi P : Sentinel-node biopsy to avoid axillary dissection in breast cancer with clinically negative lymph-nodes. *Lancet* 349 : 1864-1867, 1997
- Borgstein PJ, Meijer S, Pijpers R : Intradermal blue dye to identify sentinel lymph-node in breast cancer. *Lancet* 384 : 149-157, 1997
- Burak WE, Hollenbeck ST, Zervos EE, Hock KL, Kemp LC, Young DC : Sentinel lymph node biopsy results in less postoperative morbidity compared with axillary lymph node dissection for breast cancer. *Am J Surg* 183 : 23-27, 2002
- Golshan M, Martin WJ, and Dowlatshahi K : Sentinel lymph node biopsy lowers the rate of lymphedema when compared with standard axillary lymph node dissection. *Am Surgeon* 69 : 209-211, 2003
- Schwartz GF, Giuliano AE, Veronesi U : Proceedings of the consensus conference on the role of sentinel lymph node biopsy in carcinoma of the breast April 19 to 22, 2001, Philadelphia, Pennsylvania. *Cancer* 94 : 2542-51, 2002
- Noguchi M : Current controversies concerning sentinel lymph node biopsy for breast cancer. *Breast Cancer Res Treat* 84 : 261-271, 2004
- Motomura K, Komoike Y, Hasegawa Y, Kasugai T, Inaji H, Noguchi S, Koyama H : Intradermal radioisotope injection is superior to subdermal injection for the identification of the sentinel node in breast cancer patients. *J Surg Oncol* 82 : 91-96, 2003
- Cody HS 3rd, Fey J, Akhurst T, Fazzari M, Mazumdar M, Yeung H, Yeh SDJ, Borgen PI : Complementary of blue dye and isotope in sentinel node localization for breast cancer : Univariate and multivariate analysis of 966 procedures. *Ann Surg Oncol* 8 : 13-19, 2001
- Tanis PJ, Nieweg OE, Valdes Olmos RA, Kroon BB : Anatomy and physiology of lymphatic drainage of the breast from the perspective of sentinel node biopsy. *J Am Coll Surg* 192 : 399-409, 2001
- Bergqvist L, Sundberg R, Ryden S, Strand SE : The critical colloid dose" in studies of reticuloendothelial function. *J Nucl Med* 28 : 1424-1429, 1987
- Moghimi SM, Hawley AE, Christy NM, Gray T, Illum L, Davis SS : Surface engineered nanoparticles with enhanced drainage into lymphatics and uptake by macrophages of the regional lymph nodes. *FEBS Lett* 344 : 25-30, 1994
- Cochran AJ, Morton DL, Stern S, Lana AM, Essner R, Wen DR : Sentinel lymph nodes show profound downregulation of antigen-presenting

- cells of the paracortex : implications for tumour biology and treatment. *Mod Pathol Mod Pathol* 14 : 604-608, 2001
19. Leong SP, Peng M, Zhou YM, Vaquerano JE, Chang JW : Cytokine profiles of sentinel lymph nodes draining the primary melanoma. *Ann Surg Oncol* 9 : 82-87, 2002
 20. Matsuura K, Yamaguchi Y, Ueno H, Osaki A, Arihiro K, Toge T : Mutation of dendritic cells and T-cell responses in sentinel lymph nodes from patients with breast carcinoma. *Cancer* 106 : 1227-1236, 2006
 21. Tsopeles C and Sutton R : Why certain dyes are useful for localizing the lymph node. *J Nucl Med* 43 : 1377-1382, 2002
 22. Cherrick GR, Stein SW, Leevy CM, Davidson CS : Indocyanine green : observations on its physical properties, plasma decay and hepatic extraction. *J Clin Invest* 39 : 592-600, 1960
 23. Efron P, Knudsen E, Hirshorn S, Copeland EM : Anaphylactic reaction to isosulfan blue used sentinel node biopsy : case report and literature review. *Breast J* 8 : 396-399, 2002
 24. Shimazu K, Tamaki Y, Taguchi T, Akazawa K, Inoue T, Noguchi S : Lymphoscintigraphic visualization of internal mammary nodes with sub-tumoral injection of radiocolloid in patients with breast cancer. *Ann Surg* 237 : 390-398, 2003
 25. Borgstein PJ, Pijper R, Comans EF, van Diest PJ, Boom RP, Meijer S : Sentinel lymph node biopsy in breast cancer : guideline and pitfalls of lymphoscintigraphy and gamma probe detection. *J Am Coll Surg* 186 : 275-283, 1998
 26. Suga K, Ogasawara N, Okada M, Matsunaga N, Tangoku A : Visualization of breast lymphatic pathways with an indirect computed tomography lymphography using a nonionic monometric contrast medium iopamidol : preliminary results. *Invest Radiol* 38 : 73-84, 2003
 27. Suga K, Yuan Y, Okada M, Matsunaga N, Tangoku A, Yamamoto S, Oka M : Breast sentinel lymph node mapping at CT lymphography with iopamidol : preliminary experience. *Radiology* 230 : 543-552, 2004
 28. Tangoku A, Yamamoto S, Suga K, Ueda K, Nagashima Y, Hida M, Sato T, Sakamoto K, Oka M : Sentinel lymph node biopsy using computed tomography—lymphography in patients with breast cancer. *Surgery* 135 : 258-265, 2004
 29. Suga K, Yamamoto S, Tangoku A, Oka M, Kawakami Y, Matsunaga N : Breast sentinel lymph node navigation with three-dimensional interstitial multidetector-row computed tomographic lymphography. *Invest Radiol* 40 : 336-342, 2005
 30. Gil-Rendo A, Zomoza G, Garcia Velloso MJ, Regueira FM, Beorlegui C, Cervera M : Fluorodeoxyglucose positron emission tomography with sentinel node biopsy for evaluation of axillary involvement in breast cancer. *Br J Surg* 93 : 707-712, 2006
 31. Goyal A, Douglas—Jones A, Monypenny I, Sweetland H, Stevens G, Mansel RE : Is there a role of sentinel lymph node biopsy in ductal carcinoma in situ? : analysis of 587 cases. *Breast Cancer Res Treat* 98 : 311-314, 2006
 32. Derossis AM, Fey JV, Cody HS 3rd, Borgen PI : Obesity influences outcome of sentinel lymph node biopsy in early-stage breast cancer. *J Am Coll Surg* 197 : 896-901, 2003
 33. Carmon M, Olsha O, Rivkin L, Spira RM, Golomb E : Intraoperative palpation for clinically suspicious axillary sentinel lymph nodes reduces the false-negative rate of sentinel lymph node biopsy in breast cancer. *Breast J* 12 : 199-210, 2006
 34. Schrenk P, Hochreiner G, Fridrik M, Wayand W : Sentinel node biopsy performed before preoperative chemotherapy for axillary node staging in breast cancer. *Breast J* 9 : 282-287, 2003
 35. Rubio IT, Korourian S, Cowan C, Krag DN, Colvet M, Klimberg VS : Use of touch preps for intraoperative diagnosis of sentinel lymph node metastases in breast cancer. *Ann Surg Oncol* 5 : 689-694, 1998
 36. Motomura K, Inaji H, Komoike Y, Kasugai T, Nagumo S, Noguchi S, Koyama H : Intraoperative sentinel node examination by imprint cytology and frozen sectioning during breast surgery. *Br J Surg* 87 : 597-601, 2000
 37. Treseler P. Pathologic examination of sentinel lymph node : what is the best method? *Breast J* 12 (Suppl 2) : S143-S151, 2006
 38. Krag DN, Julian TB, Harlow SP, Weaver DL, Ashikaga T, Bryant J, Single RM, Wolmark N : NSABP-32 : Phase III, randomized trial comparing axillary resection with sentinel lymph node dissection : a description of trial. *Ann Surg Oncol* 11 (Suppl 3) : 208S-210S, 2004
 39. Harlow SP, Krag DN, Julian TB, Ashikaga T, Weaver DL, Feldman SA, Klimberg VS, Kusminsky R, Moffat FL Jr, Noyes RD,

- Beitsch PD : Prerandomization Surgical Training for National Surgical Adjuvant Breast and Bowel Project (NSABP) B-32 trial, a randomized phase III clinical trial to compare sentinel node resection to conventional axillary dissection in clinically node-negative breast cancer. *Ann Surg* 241 : 48-54, 2005
40. Mansel RE, Fallowfield L, Lissin M, Goyal A, Newcombe RG, Dixon JM, Yiangou C, Horgan K, Bundred N, Monypenny I, England D, Sibbering M, Abdullah TI, Barr L, Chetty U, Sinnette DH, Fleissig A, Clarke D, Ell PJ : Randomized multicenter trial of sentinel node biopsy versus standard axillary treatment in operable breast cancer the ALMANAC Trial. *J Natl Cancer Inst* 98 : 599-609, 2006
 41. Leitch AM, Beitsch PD, McCall LM, Posther K, Newman LA, Herndon JE II, Hunt KK, Giuliano AE : Patterns of participation and successful patient recruitment to American College of Surgeons Oncology Group Z0010, a phase II trial for patients with early-stage breast cancer. *Am J Surg* 190 : 539-542, 2005
 42. Wilke LG, McCall LM, Posther K, Whitworth PW, Reintgen DS, Leitch AM, Gabram SGA, Lucci A, Cox CE, Hunt KK, Herndon JE 2nd, Giuliano AE : Surgical complications associated with sentinel lymph node biopsy : results from a prospective international cooperative group trial. *Ann Surg Oncol* 13 : 491-500, 2006
 43. Gipponi M : Clinical applications of sentinel lymph-node biopsy for the staging and treatment of solid neoplasms. *Minerva Chir* 60 : 217-33, 2005
 44. Balega J, Van Trappen PO : The sentinel node in gynecological malignancies. *Cancer Imaging* 6 : 7-15, 2006
 45. Frumovitz M, Coleman RL, Gayed IW, Ramirez PT, Wolf JK, Gershenson DM, Levenbach CF : Usefulness of preoperative lymphoscintigraphy in patients who undergo radical hysterectomy and pelvic lymph adenectomy for cervical cancer. *Am J Obstet Gynecol* 194:1186-1195, 2006
 46. Liedberg F, Chebil G, Davidsson T, Gudjonsson S, Mansson W : Intraoperative sentinel node detection improves nodal staging in invasive bladder cancer. *J Urol* 175 : 84-89, 2006
 47. Corvin S, Scilling D, Eichhorn K, Hundt I, Hennenlotter J, Anastasiadis AG, Kuczyk M, Bares R, Stenzl A : Laparoscopic sentinel lymph node dissection- a novel technique for the staging of prostate cancer. *Eur Urol* 49 : 280-285, 2005
 48. Doting EH, de Vries M, Plukker JT, Jager PL, Post WJ, Suurmeijer AJ, Hoekstra HJ : Does sentinel lymph node biopsy in cutaneous head and neck melanoma alter disease outcome? *J Surg Oncol* 93 : 564-570, 2006
 49. Fukui, Y, Yamakawa, T, Taniki, Numoto S, Miki H, Monden Y : Sentinel lymph node biopsy in patients with papillary thyroid carcinoma. *Cancer* 9 : 2868-2874, 2001
 50. Rzyman W, Hagen OM, Dziadziuszko R, Kobierska-Gulida G, karmolinski A, Lothe IM, Babovic Murawski M, Paleczka W, Jastrzebski T, Kopacz A, Jassem J, Lass P, Skokowski J : Intraoperative radio-guided sentinel lymph node mapping in 110 nonsmall cell cancer patients. *Ann Thorac Surg* 82 : 4-5, 2006
 51. Investigators IMPACT B2 : Efficacy of adjuvant fluorouracil and folinic acid in B2 colon cancer. International Multicentre Pooled Analysis of B2 Colon Cancer Trials (IMPACT B2) Investigators. *J Clin Oncol* 17 : 1356-1363, 1999
 52. Moertel CG, Fleming TR, Macdonald JS, Haller DG, Laurie JA, Goodman PJ, Ungerleider JS, Emerson WA, Tormey DC, Glick JH : Levamisole and fluorouracil for adjuvant therapy of resected colon carcinoma. *N Eng J Med* 322 : 352-358, 1990
 53. Daneker GW Jr, Ellis LM : Colon cancer nodal metastasis : biologic significance and therapeutic considerations. *Surg Oncol Clin North Am* 5 : 173-189, 1996
 54. Hernenz F, Revuelta S, Redondo C, Madeazo C, Castillo J, Gomez-Fleitas M : Colorectal adenocarcinoma : quality of the assessment of lymph node metastases. *Dis Colon Rectum* 37 : 373-376, 1994
 55. Scott KW, Grace RH, Gibbons P : Five-year follow-up study of the fat clearance technique in colorectal carcinoma. *Dis Colon Rectum* 37 : 126-128, 1994
 56. Cawthorn SJ, Gibbs NM, Marks CG. : Clearance technique for the detection of lymph nodes in colorectal cancer. *Brit J Surg* 73:58-60, 1986
 57. Rodriguez-Bigas MA, Maamoun S, Weber TK, Penetrante RB, Blumenson LE, Petrelli NJ : Clinical significance of colorectal cancer : metastases in lymph nodes <5 mm in size. *Ann Surg Oncol* 3 : 124-130, 1996
 58. Trocha SD, Nora DT, Saha SS, Morton DL, Wiese D, Bilchik AJ : Combination probe and dye-directed lymphatic mapping detects mi-

- crometastases in early colorectal cancer. *J Gastrointest Surg* 7 : 340-345, 2003
59. Wong JH, Steineman S, Calderia C, Bowles J, namiki T : *Ex vivo* sentinel node mapping in carcinoma of the colon and rectum. *Ann Surg* 233 : 515-521, 2001
 60. Fitzgerald TL, Khalifa MA, Al Zahrani M, Law CH, Smith AJ. *Ex vivo* sentinel lymph node biopsy in colorectal cancer : a feasibility study. *J Surg Oncol* 80 : 27-32, 2002
 61. Wood TF, Saha S, Morton DL, Tsioulis GJ, Rangel D, Hutchinson W Jr, Foshag LJ, Bilchik AJ : Validation of lymphatic mapping in colorectal cancer : *in vivo*, *ex vivo*, and laparoscopic techniques. *Ann Surg Oncol* 8 : 150-157, 2001
 62. Paramo JC, Summerall J, Poppiti R, Mesko TW : Validation of sentinel node mapping in patients with colon cancer. *Ann Surg Oncol* 9 : 550-554, 2002
 63. Bilichik AJ, Nora D, Tollenaar RA, van de Velde CJ, Wood R, Turner R, Morton DL, Hoon DS : Ultrastaging of early colon cancer using lymphatic mapping and molecular analysis. *Eur J Cancer* 38 : 977-985, 2002
 64. Goldstein NS : Lymph node recoveries from 2427 pT3 colorectal resection specimens spanning 45 years : recommendations for a minimum number of recovered lymph nodes based on predictive probabilities. *Am J Surg Pathol* 26 : 179-189, 2002
 65. Broderick-Villa G, Ko A, O'Connell TX, Guenther JM, Danial T, DiFronzo LA : Does tumour burden limit the accuracy of lymphatic mapping and sentinel lymph node biopsy in colorectal cancer? *Cancer J* 8 : 445-450, 2002
 66. Liefers GJ, Cleton-Jansen AM, van de Velde CJ, Hermans J, van Krieken JH, Cornelisse CJ, Tollenaar RA : Micrometastases and survival in stage II colorectal cancer. *N Eng J Med* 339 : 223-228, 1998
 67. Clarke G, Ryan E, O'Keane JC, Crowe JU, MacMathuna P. The detection of cytokeratins in lymph nodes of Duke's B colorectal cancer subjects predicts a poor outcome. *Eur J Gastroenterol Hepatol* 12 : 549-552, 2000
 68. Rosenberg R, Hoos A, Mueller J, baier P, Stricker D, Werner M, Nekarda H, Siewert JR : Prognostic significance of cytokeratin-20 reverse transcriptase polymerase chain reaction in lymph nodes of node-negative colorectal cancer patients. *J Clin Oncol* 20 : 1049-1055, 2002
 69. Isaka N, Nozue M, Doy M, Fukai K : Prognostic significance of perirectal lymph node micrometastases in Dukes' B rectal carcinoma : an immunohistochemical study by CAM5.2. *Clin Cancer Res* 5 : 2065-2068, 1999
 70. Greenson JK, Isenhardt CE, Rice R, Mojzisek C, Houchens D, Martin EW Jr : Identification of occult micrometastases in pericolic lymph nodes of Duke's B colorectal cancer patients using monoclonal antibodies against cytokeratin and CC49. Correlation with long-term survival. *Cancer* 73 : 563-569, 1994.
 71. Haboubi NY, Abdalla SA, Amini S, Clark P, Dougal M, Dube A, Schofield P : The novel combination of fat clearance and immunohistochemistry improves prediction of the outcome of patients with colorectal carcinomas : a preliminary study. *Int J Colorectal Dis* 13 : 99-102, 1998
 72. Cutait R, Alves VA, Lopes LC, Cutait DE, Borges JL, Singer J, da Silva JH, Goffi FS : Restaging of colorectal cancer based on the identification of lymph node micrometastases through immunoperoxidase staining of CEA and cytokeratins. *Dis Colon Rectum* 34:917-920, 1991
 73. Jeffers MD, O'Dowd GM, Mulcahy H, Stagg M, O'Donoghue DP, Toner M : The prognostic significance of immunohistochemically detected lymph node micrometastases in colorectal carcinoma. *J Pathol* 172 : 183-187, 1994
 74. Adell G, Boeryd B, Franlund B, Sjodahl R, Hakansson L : Occurrence and prognostic importance of micrometastases in regional lymph nodes in Dukes' B colorectal carcinoma : an immunohistochemical study. *Eur J Surg* 162 : 637-642, 1996
 75. Broll R, Schauer V, Schimmelpenning H, Strik M, Woltmann A, Best R, Noura S, Yamamoto H, Miyake Y, Kim B, Takayama O, Seshimo I, Ikenaga M, Ikeda M, Sekimoto M, Matsuura N, Monden M : Immunohistochemical assessment of localization and frequency of micrometastases in lymph nodes of colorectal cancer. *Clin Cancer Res* 8 : 759-767, 2002
 76. Choi HJ, Choi YY, Hong SH : Incidence and prognostic implications of isolated tumour cells in lymph nodes from patients with Dukes B colorectal carcinoma. *Dis Colon Rectum* 45 : 750-755, 2002
 77. Nakanishi Y, Ochiai A, Yamauchi Y, Moriya Y, Yoshimura K, Hirohashi S : Clinical impli-

- cations of lymph node micrometastases in patients with colorectal cancers. A case control study. *Oncology* 57 : 276-280, 1999
78. Oberg A, Stenling R, Tavelin B, Lindmark G. : Are lymph node micrometastases of any clinical significance in Dukes Stages A and B colorectal cancer? *Dis Colon Rectum* 41 : 1244-1249, 1998
 79. Mori M, Mimori K, Inoue H, barnard GF, Tsuji K, Nanbara S, Ueno H, Akiyoshi T : Detection of cancer micrometastases in lymph nodes by reverse transcriptase—polymerase chain reaction. *Cancer Res* 55 : 3417-3420, 1995
 80. Rosenberg R, Hoos A, Mueller J, Nekarda H : Impact of cytokeratin-20 and carcinoembryonic antigen mRNA detection by RT—PCR in regional lymph nodes of patients with colorectal cancer. *Brit J Cancer* 83 : 1323-1329, 2000
 81. Cagir B, Gelmann A, park J, Fava T, Tankelevitch A, Bittner EW, Weaver EJ, Palazza JP, Weinberg D, Fry RD, Waldman SA : Guanylyl cyclase C messenger RNA is a biomarker for recurrent stage II colorectal cancer. *Ann Intern Med* 131 : 805-812, 1999
 82. Bouvet M, Mansfield PF, Skibber JM, Curley SA, Ellis LM, Giacco GG, Madry AR, Ota DM, Ferg BW : Clinical, pathologic, and economic parameters of laparoscopic colon resection for cancer. *Am J Surg* 176 : 554-558, 1998
 83. Stage JG, Schulze S, Moller P, Overgaard H, Andersen M, Rebsdorf-Pedersen VB, Nielsen HJ : Prospective randomized study of laparoscopic versus open colonic resection for adenocarcinoma. *Br J Surg* 84 : 391-396, 1997
 84. Kitagawa Y, Ohgami M, Fujii H, Mukai M, Kubota T, Ando N, Watanabe M, Otani Y, Ozawa S, Hasegawa H, Furukawa T, Matsuda J, Kumai K, Ikeda T, Kubo A, Kitajima M : Laparoscopic detection of sentinel lymph nodes in gastrointestinal cancer : a novel and minimally invasive approach. *Ann Surg Oncol (Suppl 9)* : 86S-89S, 2001
 85. Bilchik AJ, Trocha SD : Lymphatic mapping and sentinel node analysis to optimize laparoscopic resection and staging of colorectal cancer : an update. *Cancer Control* 10 : 219-223, 2003
 86. Bembenek A, Rau B, Moesta T, Markwardt J, Ulmer C, Gretschel S, Schneider U, Slison W, Schlag PM : Sentinel lymph node biopsy in rectal cancer — not yet ready for clinical routine use. *Surgery* 135 : 498-505, 2004
 87. Tsioulis GJ, Wood TF, Morton DL, Bilchik AJ : Lymphatic mapping and focused analysis of sentinel lymph nodes upstage gastrointestinal neoplasms. *Arch Surg* 135 : 926-932, 2000
 88. Schlag PM, Bembenek A, Schlze T : Sentinel node biopsy in gastrointestinal tract cancer. *Eur J Cancer* 40 : 2022-2032, 2004
 89. Kampschoer GH, Maruyama K, van de Velde CJ, Sasako M, Kinoshita T, Okabayashi K : Computer analysis in making preoperative decisions : a rational approach to lymph node dissection in gastric cancer patients. *Brit J Surg* 76 : 905-908, 1989
 90. Skoropad V, Berdov B, Zagrebin V : Clinicopathological features and outcome of surgical treatment of 149 patients with early (pT1) gastric cancer. *Oncologie* 28 : 247-252, 2005
 91. Kosaka T, Ueshige N, Sugawa J, Nakano Y, Akiyama T, Tomita F, Saito H, Kita I, Takashima S : Lymphatic routes of the stomach demonstrated by gastric carcinomas with solitary lymph node metastasis. *Surg Today* 29 : 695-700, 1999
 92. Palaia R, Cremona P, Delrio P, Izzo F, Ruffolo F, Parisi V : Sentinel node biopsy in gastric cancer. *J Chemother* 11 : 230-231, 1999
 93. Hiratsuka M, Miyashiro I, Ishikawa O, Furukawa H, Motomura K, Ohigashi H, Kameyama M, Sasaki Y, Kabuto T, Ishiguro S, Imaoka S, Koyama H : Application of sentinel node biopsy to gastric cancer surgery. *Surgery* 129 : 335-340, 2001
 94. Ichikura T, Morita D, Uchida T, Okura E, majima T, Ogawa T, Mochizuki H : Sentinel node concept in gastric carcinoma. *World J Surg* 26 : 318-322, 2002
 95. Kitagawa Y, Fujii H, Mukai M, Kubota T, Otani Y, Kitajima M : Radio-guided sentinel node detection for gastric cancer. *Brit J Surg* 89 : 604-608, 2002.
 96. Miwa K, Kinami S, Taniguchi K, Fushida S, Fujimura T, Nonomura A : Mapping sentinel nodes in patients with early-stage gastric carcinoma. *Brit J Surg* 90 : 178-182, 2003
 97. Tonouchi H, Mohri Y, Tanaka K, Konishi N, Ohmori Y, Kobayashi M, Konishi N, Ohmori Y, Kusunoki M : Lymphatic mapping and sentinel node biopsy during laparoscopic gastrectomy for early cancer. *Dig Surg* 20 : 421-427, 2003
 98. Ryu KW, Lee JH, Kim HS, Kim YW, Choi IJ, Bae JM : Prediction of lymph nodes metasta-

- sis by sentinel node biopsy in gastric cancer. *Eur J Surg Oncol* 29 : 895-899, 2003
99. Hayashi H, Ochiai T, Mori M, Karube T, Suzuki T, Gunji Y, Hori S, Akutsu N, Matsubara H, Shimada H : Sentinel lymph node mapping for gastric cancer using a dual procedure with dye- and γ probe-guided techniques. *J Am Coll Surg* 196 : 68-74, 2003
 100. Song X, Wang L, Chen W, Pan T, Zhu H, Xu J, Jin M, Finley RK 3rd, Wu J : Lymphatic mapping and sentinel node biopsy in gastric cancer. *Am J Surg* 187 : 270-273, 2004
 101. Shiozawa M, Kawamoto M, Ishiwa N, Rino Y, Takanashi Y, Nakatani Y, Inayama Y, Imada T : Clinical usefulness of intraoperative sentinel-node biopsy in gastric cancer. *Hepatogastroenterology* 50 : 1187-1189, 2003
 102. Uenosono Y, Natsugoe S, Higashi H, Ehi K, Miyazono F, Ishigami S, Hokita S, Aikou T : Evaluation of colloid size for sentinel nodes detection using radioisotope in early gastric cancer. *Cancer Lett* 200 : 19-24, 2003
 103. Tonouchi H, Mohri Y, Tanaka K, Kobayashi M, Ohmori Y, Kusunoki M : laparoscopic lymphatic mapping and sentinel node biopsies for early-stage gastric cancer : the cause of false negativity. *World J Surg* 29 : 418-421, 2005
 104. Arigami H, Natsugoe S, Uenosono Y, Mataka Y, Ehi K, Higashi H, Arima H, Yanagida S, Ishigami S, Hokita S, Aikou T : Evaluation of sentinel node concept in gastric cancer based on lymph node micrometastasis determined by reverse transcription-polymerase chain reaction. *Ann Surg* 243 : 341-347, 2006
 105. Kitagawa Y, Ohgami M, Fujii H, Mukai M, Kubota T, Ando N, Watanabe M, Otani Y, Ozawa S, Hasegawa H, Furukawa T, Matsuda J, Kumai K, Ikeda T, Kubo A, Kitajima M : Laparoscopic detection of sentinel lymph nodes in gastrointestinal cancer : a novel and minimally invasive approach. *Ann Surg Oncol Suppl* 9 : 86S-89S, 2001
 106. Kitagawa Y, Fujii H, Mukai M, Kudo A, Kitajima M : Sentinel lymph node mapping in esophageal and gastric cancer. *Cancer Treat Res* 127 : 123-139, 2005
 107. Kitagawa Y, Fujii H, Kumai K, Kubota T, Otani Y, Saikawa Y, Yoshida M, Kubo A, Kitajima M : Recent advances in sentinel node navigation for gastric cancer : a paradigm shift of surgical management. *J Surg Oncol* 90 : 147-152, 2005
 108. Shimada H, Okazumi S, Matsubara H, Nabeya Y, Shiratori T, Shuto K, Shimizu T, Akutsu Y, Tanizawa Y, Hayashi H, Ochiai T : Location and clinical impact of solitary lymph node metastasis in patients with thoracic esophageal carcinoma. *Am J Surg* 192 : 306-310, 2006
 109. May A, Ell C : Diagnosis and treatment of early esophageal cancer. *Curr Opin Gastroenterol* 22 : 433-436, 2006
 110. Eguchi T, Nakanishi Y, Shimoda T, Iwasaki M, Igaki H, Tachimori Y, Kato H, Yamaguchi H, Saito D, Umemura S : Histopathological criteria for additional treatment after endoscopic mucosal resection for esophageal cancer : analysis of 464 surgical resected cases. *Mod Pathol* 19 : 475-80, 2006
 111. Altorki N : En-bloc esophagectomy—the three field dissection. *Surg Clin North Am* 85 : 611-619, 2005
 112. Fujita H, Sueyoshi S, Tanaka T, Fujii T, Toh U, Mine T, Sasahara H, Sudo T, Matono S, Yamana H, Shirouzu K : Optimal lymphadenectomy for squamous cell carcinoma in the thoracic esophagus : comparing the short- and long term outcome among the four types of lymphadenectomy. *World J Surg* 27 : 571-579, 2003
 113. Tachibana M, Kinugasa S, Shibakita M, Tonomoto Y, Hattori S, Hyakudomi R, Yoshimura H, Dhar DK, Nagasue N : Surgical treatment of superficial esophageal cancer. *Langenbecks Arch Surg* 391 : 304-321, 2006
 114. Fang W, Kato H, Tachimori Y, Igaki H, Sato H, Daiko H : Analysis of pulmonary complications after three-field lymph node dissection for esophageal cancer. *Ann Thorac Surg* 76 : 903-908, 2003
 115. Endo M, Yoshino K, Kawano T, Nagai K, Inoue H : . Clinicopathologic analysis of lymph node metastasis in surgically resected superficial cancer of the thoracic esophagus. *Dis Esophagus* 13 : 125-129, 2000
 116. DeMeester SR : Endoscopic mucosal resection and vagal-sparing esophagectomy for high grade dysplasia and adenocarcinoma of the esophagus. *Semin Thorac Cardiovasc Surg* 17 : 320-325, 2005
 117. Kitagawa Y, Fujita H, Mukai M, Kubota T, Ando N, Ozawa S, Ohtani Y, Furukawa T, Yoshida M, Nakamura E, Matsuda J, Shimizu Y, Nakamura K, Kumai K, Kubo A, Kitajima M : Intraoperative mapping and sentinel lymph node sampling in esophageal and gastric can-

- cer. *Surg Oncol Clin N Am* 11 : 293-304, 2002
118. Kato H, Miyazaki T, Nakajima M, Takita J, Sohda M, Fukai Y, Masuda N, Tukuchi M, Manda R, Ojima H, Tsukada K, Asao T, Kumano H, Oriuchi N, Endo K : Sentinel lymph nodes with technetium-99m colloidal rhenium sulfide in patients with esophageal carcinoma. *Cancer* 98 : 932-999, 2003
119. Yasuda S, Shimada H, Chino O, Tanaka H, Kenmochi T, Takeuchi M, Nabeshima K, Okamoto Y, Kato Y, Kijima H, Suzuki Y, Ogoshi K, Tajima T, Makuuchi H : Sentinel lymph node detection with Tc-99m tin colloids in patients with esophagogastric cancer. *Jpn J Clin Oncol* 33 : 68-72, 2003
120. Feith M, Stein HJ, Siewert JR : Pattern of lymphatic spread of Barrett's cancer. *World J Surg* 27 : 1052-1057, 2003
121. Burian M, Stein HJ, Sendler A, Piert M, Nahrig J, Feith M, Sievert JR. Sentinel node detection in Barrett's and cardia cancer. *Ann Surg Oncol (Suppl 3)* : 255S-258S, 2004
122. Ueno H, Hihara J, Shimizu K, Osaki A, Yamashita Y, Yoshida K, Toge T : Experimental study on fluorescent microspheres as a tracer for sentinel node detection. *Anticancer Res* 25 : 821-582, 2005
123. Parungo CP, Ohnishi S, Kim SW, Kim S, Laurence RG, Soltesz EG, Chen FY, Colson YL, Cohn LH, Bawendi MG, Frangioni JV : Intraoperative identification of esophageal sentinel lymph nodes with near-infrared fluorescence imaging. *J Thorac Cardiovasc Surg* 129 : 844-50, 2005
124. Soltesz EG, Kim S, Kim SW, Laurence RG, De Grand AM, Parungo CP, Cohn LH, Bawendi MG, Frangioni JV : Sentinel lymph node mapping of the gastrointestinal tract by using invisible light. *Ann Surg Oncol* 13 : 386-96, 2006
125. Goldberg BB, Merton DA, Liu JB, Murphy G, Forsberg F : Contrast-enhanced sonographic imaging of lymphatic channels and sentinel lymph nodes. *J Ultrasound Med* 24 : 953-965, 2005
126. Ellner SJ, Mendez J, Vera DR, Hoh CK, Ashburn WL, Wallace AM : Sentinel lymph node mapping of the colon and stomach using lymphoseek in a pig model. *Ann Surg Oncol* 11 : 674-681, 2004
127. Nason RW, Torchia MG, Morales CM, Thliveris J : Dynamic MR lymphangiography and carbon dye for sentinel lymph node detection : a solution for sentinel lymph node biopsy in mucosal head and neck cancer. *Head Neck* 27 : 333-338, 2005
128. Hayashi H, Tangoku A, Suga K, Shimizu K, Ueda K, Yoshino S, Abe T, Sato T, Oka M : CT lymphography-navigated sentinel lymph node biopsy in patients with superficial esophageal cancer. *Surgery* 139 : 224-235, 2006
129. Tangoku A, Yoshino S, Abe T, Hayashi H, Satou T, Ueno T, Oka M : Mediastinoscope-assisted transhiatal esophagectomy for esophageal cancer. *Surg Endosc* 18 : 383-389, 2004