

CASE REPORT

Two cases of retroperitoneal hematoma caused by combination of anticoagulant therapy and 5-fluorouracil

Naomi Morita^{1,2)}, Kennichi Kashihara¹⁾, Hiroshi Tagashira¹⁾, Hideki Otsuka²⁾, Kazuhide Yoneda²⁾, Tomoya Murase²⁾, Tetsuya Tsujikawa²⁾, Syunnsuke Furutani²⁾, Kaori Furutani²⁾, Masako Minato²⁾, and Hiromu Nishitani²⁾

¹⁾*Department of Radiology, Ehime Prefectural Central Hospital, Ehime, Japan ; and* ²⁾*Department of Radiology, Institute of Health Biosciences, The University of Tokushima Graduate School, Tokushima, Japan*

Abstract : We reported two cases of retroperitoneal hematoma in patients who received a combination of anticoagulant therapy and 5-fluorouracil (5-FU). We should be aware of the possible interaction of this combination therapy and monitor prothrombin time (PT) prolongation. CT is useful for evaluation of the disease. *J. Med. Invest.* 52 : 114-117, February, 2005

Keywords : retroperitoneal hematoma, warfarin, 5-FU, CT

INTRODUCTION

Anticoagulant therapy is known to be one of the causes of retroperitoneal hematoma (1-5). The mortality rate of patients with retroperitoneal hematoma who have undergone anticoagulant therapy has been reported to be higher than that of patients who have not undergone anticoagulant therapy (1). It has also been reported that the combination of warfarin, an anticoagulant drug, and 5-FU can prolong coagulation time (6-10).

We describe two cases of retroperitoneal hematoma in patients who underwent combination therapy with anticoagulant drugs and 5-FU. CT scans showed characteristic findings of hematoma and were useful to know the extent of the hematoma.

CASE REPORT

Patient 1 :

A 71-year-old male was admitted to our institute with increasing dyspnea and hoarseness. He had been

treated for chronic heart failure and had undergone total esophageal resection for esophageal cancer (moderate differentiated squamous cell carcinoma). A CT scan showed a recurrent tumor in the upper mediastinum, and chemoradiation therapy was started with 500 mg/m² of 5-FU and 20 mg/m² of cisplatin (CDDP) for five days a week and 6 mg/m² of mitomycin (MMC) once a week. Focal irradiation at 2 Gy/day (total of 50 Gy) was also performed. After completion of the 2-week chemotherapy, he started to feel left back pain. The cause of the pain could not be confirmed clinically by X rays or spinal MRI. Because of renal dysfunction (BUN/CRNN, 84.4/2.4) due to severe heart failure, continuous hemofiltration therapy (CHF) with 10000 U/day of heparin was performed for 2 weeks. The hemoglobin level gradually decreased during the CHF, and the patient was followed conservatively. On the 15th day after starting CHF, he complained of progressive left abdominal pain and fullness. Physical examination demonstrated a firm, tender mass in the left flank. Hemoglobin level had decreased to 5.7g/dl. WBC was 11900/ μ l and platelet count was 10.1×10^4 / μ l, but the prothrombin time was prolonged by only 15.1% (average : 80-120). Intra-abdominal hemorrhage was suspected and abdominal US was performed. US showed a mixed high-echoic mass in the left pelvis and ascites in Douglas' pouch (Fig. 1A). A CT scan without

Received for publication September 7, 2004 ; accepted October 25, 2004.

Address correspondence and reprint requests to Naomi Morita, M.D., Department of Radiology, Institute of Health Biosciences, The University of Tokushima Graduate School, Kuramoto-cho, Tokushima 770-8503, Japan and Fax : +81-88-633-7174.

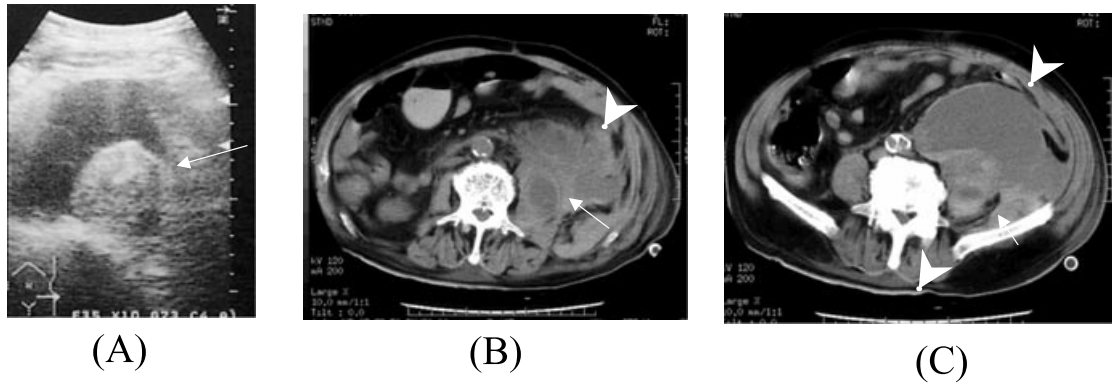


Fig 1 . Patient 1.
 (A) Abdominal US showed a heterogeneous high-echoic pelvic mass representing hematomas (arrow) and ascites in Douglas' pouch.
 A CT scan without a contrast-enhancing agent demonstrated a mixed-density mass within the left psoas muscle (arrow):
 (B)(C). Low-density hematomas were demonstrated within the left psoas muscle and left retroperitoneal space (arrowhead).

a contrast-enhancing agent demonstrated an enlarged left ileopsoas muscle with mixed density and a capsulated cystic mass within the left psoas muscle and posterior pararenal space (Fig. 1 B, C). The diagnosis of retroperitoneal hematoma was confirmed by these CT findings. The patient was treated conservatively with a change in drugs from heparin to nafamostat mesilate (futhan), but the hemorrhage repeated again, and he finally died due to severe heart and renal failure.

Patient 2 :

A 70-year-old male was transferred to our hospital with the diagnosis of panperitonitis due to perforation of the sigmoid colon. The sigmoid colon was resected, and pathological examination revealed an adenocarcinoma. He also had a history of mitral valve replacement about twenty years ago and had continued medication with warfarin. About one month after admission, intra-arterial injection of 5-FU (at 1250mg/m² per week) was started for multiple liver metastases, confirmed by

CT. After the completion of 4 cycles of 5-FU treatment, he felt severe lumbago. The next day, he vomited frequently, and his blood pressure dropped to 70mmHg. Hemoglobin level decreased from 9.6 to 6.9g/dl within a day. WBC was 22500/ μ l and platelet count was 25.7×10^4 / μ l. Prothrombin time (PT) and International Normalized Ratio (INR) could not be measured because of the lack of fibrinogen. Abdominal US revealed a mixed echo lesion within the psoas muscle and ascites (Fig. 2 A). CT scans with and without a contrast-enhancing agent showed heterogeneous density masses within the bilateral retroperitoneal space (Fig. 2B, C) with slight leakage of contrast medium from the left psoas muscle (Fig.2 C). Warfarin therapy was withheld, and the patient was treated conservatively for 2 weeks. Three days after restarting warfarin therapy, a transient ischemic attack occurred, and treatment was changed from intra-arterial injection of 5-FU to peroral administration of UFT.

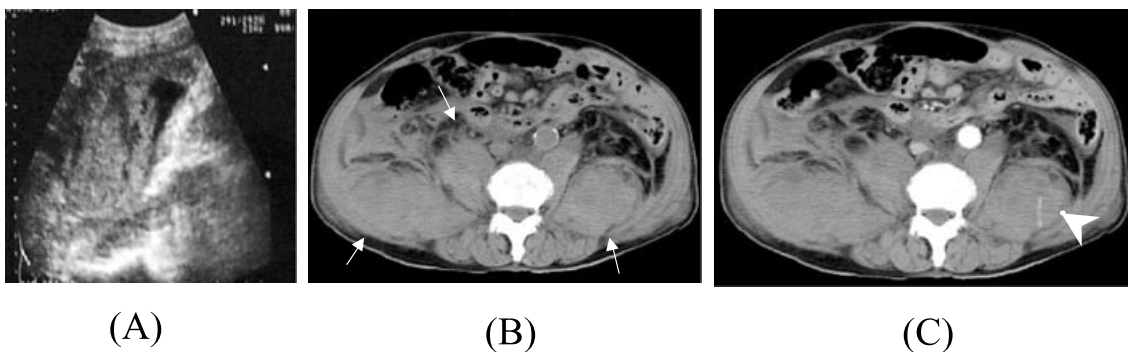


Fig 2 . Patient 2.
 (A) Abdominal US showed a mixed-density mass within the ileopsoas muscle.
 (B) A plain CT scan showed bilateral mixed-density retroperitoneal masses and swelling of ileopsoas muscles (arrow).
 (C) A contrast-enhanced CT scan showed linear leakage of the contrast-enhancing agent within the hematoma (arrowhead).

DISCUSSION

Retroperitoneal hematoma can occur in various situations such as trauma, rupture of an aortic aneurysm and presence of a retroperitoneal tumor. CT clearly demonstrates the site and extent of the hematoma and is helpful for confirming the diagnosis. A high-density lesion on unenhanced CT images indicates a hematoma in the acute phase. Enhanced CT sometimes demonstrates extravasation of the intravenously injected contrast-enhancing agent, consistent with acute hemorrhage. Anticoagulant therapy is also one of the causes of retroperitoneal hematoma (1-5). Femoral nerve disturbance is observed in 27-79% of such patients, the disturbance being due to compression of the nerve by the hematoma, commonly located in the iliopsoas muscle (51-60%)(1). Retroperitoneal hematoma was also suspected in our patients based on their clinical histories and symptoms despite the absence of femoral nerve disturbance. It has been reported that the mortality rate of patients with retroperitoneal hemorrhage who received anticoagulant therapy (20%) was higher than that of patients who did not receive anticoagulant therapy (12%)(1). Conservative therapy with fresh-frozen plasma and vitamin K may be the first choice and can be followed by surgery and intervention for persistent hemorrhage. Choo reported the use of transcatheter embolization for a patient with retroperitoneal hematoma who had undergone anticoagulant therapy (11). Detection of a bleeding artery is difficult because of the complexity of the blood supply. Indication for interventional procedures such as embolization and percutaneous drainage remains unclear. Percutaneous drainage might be useful for patients such as patient 1 who show focal low densities in the hematoma on CT images.

The combination of 5-FU and warfarin is known to prolong PT for several weeks from the initiation of 5-FU treatment (6-10). Although the mechanism of the interaction is unclear, it has been postulated that 5-FU interferes with the synthesis of hepatic cytochrome P-450C9, the enzyme that principally metabolizes warfarin by 7- and 6-hydroxylation (6, 7). Our patients were also thought to have been affected by this interaction. It is difficult to determine the appropriate dose of warfarin to be used in combination with 5-FU. Kolesar reported 5 patients who required warfarin dose reduction (mean reduction of 44%) regardless of the 5-FU regimen (8). They recommended weekly PT and INR monitoring for all patients undergoing warfarin and 5-FU therapy. In our cases, retroperitoneal hemorrhage occurred before the first PT examination, indicating the importance of PT examination within one week after starting

combination therapy.

It is sometimes difficult to determine the best treatment option for patients with major hemorrhage. Ananthasubramaniam reported that none of twenty-eight patients with prosthetic heart valves had thromboembolic complications despite discontinuation of anticoagulant therapy for a mean period of 15 ± 4 days (12). One of our patients in whom warfarin therapy was discontinued for 14 days had a transient ischemic attack.

We should be aware of this interaction of 5-FU and warfarin and regularly monitor PT. CT is useful for evaluation of retroperitoneal hematoma.

CONCLUSION

We have described two cases of retroperitoneal hematoma in patients who underwent combination therapy with warfarin and 5-FU. We should be aware of the interaction of 5-FU and warfarin and the importance of monitoring PT. Retroperitoneal hemorrhage might occur in patients receiving combination therapy, and a CT scan is useful for diagnosis and for determining the extent of a hematoma.

REFERENCES

1. Gonzalez C, Penado S, Liata L, Valero C, Riancho JA : The Clinical Spectrum of Retroperitoneal Hematoma in Anticoagulated Patients. *Medicine* 82 : 257-262, 2003
2. Cisternino SJ, Neiman HL, Malave SR : Diagnosis of Retroperitoneal Hemorrhage by Serial Computed Tomography. *J Comput Assist Tomogr* 3(5) : 686-688, 1979
3. Linder A, Zierz S : Retroperitoneal hematoma. *N Engl J Med* 344(5) : 348, 2001
4. Heilbronn YD, Williams VL, Kranzler LI, Banuchi FF, Siqueira EB : CT scan of Retroperitoneal Hematoma with Neuropathy. *Surg Neurol* 12:251-252, 1979
5. Merrick HW, Zeiss J, Woldenberg LS : Percutaneous Decompression for Femoral Neuropathy Secondary to Heparin-Induced Retroperitoneal Hematoma : Case Report and Review of the Literature. *Am Surg* 57 : 706-711, 1991
6. Brown MC : An Adverse Interaction between Warfarin and 5-Fluorouracil : A Case Report and Review of the Literature. *Chemotherapy* 45:392-395, 1999
7. Brown MC : Multislice Mucous Membrane Bleed-

- ing Due to a Possible Interaction Between Warfarin and 5-Fluorouracil. *Pharmacotherapy* 17(3) : 631-633, 1997
8. Kolesar JM, Johnson CL, Freeberg BL, Berlin JD, Schiller JH : Warfarin-5-FU Interaction-A consecutive Case Series. *Pharmacotherapy* 19(12):1445-1449, 1999
 9. Scarfe MA, Israel MK : Possible Drug Interaction Between Warfarin and Combination of Levamisole and Fluorouracil. *Ann. Pharmacotherapy* 28 : 464-467, 1994
 10. Chlebowski RT, Gota CH, Chan KK, Weiner JM, Block JB, Bateman JR : Clinical and Pharmacokinetic Effects of Combined Warfarin and 5-Fluorouracil in Advanced Colon Cancer. *Cancer Res* 42 : 4827-4830, 1982
 11. Choo IW, Sproat IA, Cho KJ : Transcatheter Embolization of the Marginal Artery of Drummond as treatment for Life-Threatening Retroperitoneal Hemorrhage Complicating Heparin Therapy. *Cardiovasc Intervent Radiol* 17 : 161-163, 1994
 12. Ananthasubramaniam K, Beattie JN, Rosman HS, Jayam V, Borzak S : How Safe and for How Long Can Warfarin Therapy Be Withheld in Prosthetic Heart Valve Patients Hospitalized With a Major Hemorrhage ?. *CHEST* 119:478-484, 2001