

CASE REPORT

Repair of incisional hernia with prolene hernia system

Takayuki Miyauchi, Masashi Ishikawa, and Yoshifumi Tagami

Department of Surgery, National Kochi Hospital, Kochi, Japan

Abstract : A 70-year-old woman was admitted to our hospital with a complaint of bulging in the right lower portion of the abdomen. The bulging was in accordance with an old operative scar for appendicitis. The findings of computed tomography (CT) showed defects in the abdominal muscles and the protrusion of the intestine into the subcutaneous fat. The patient was diagnosed with incisional hernia after appendectomy and underwent a repair of the incisional hernia, using the prolene hernia system double-layer mesh. The patient's post-operative course was excellent. Recently, the prolene hernia system, double-layer mesh was reported to be effective for groin hernias due to its advantageous protection the recurrence through reinforcement of the patient's myopectrial orifice. It is suggested that this new device is also useful for small incisional hernias. *J. Med. Invest.* 50 : 108-111, 2003

Keywords : *incisional hernia, prolene hernia system*

INTRODUCTION

Despite the developments in surgical techniques, operative devices, and materials, incisional hernia remains a significant problem in abdominal surgery because it sometimes complicates the incarceration, which may cause severe complications, such as strangulation obstruction and perforation of the intestine (1). Incisional hernias have been treated using various procedures (2), and are currently mainly repaired by techniques using a polypropylene artificial mesh for medium or large incisional hernias (3). In the treatment of groin hernias, some devices have recently been investigated with the aim of tension-free (4, 5). In our hospital, we also treat groin hernias with such devices, including the prolene hernia system double layer device. A 70-year-old woman was admitted to our hospital for the repair of an incisional hernia after a laparotomy for appendicitis and, we applied the prolene hernia system in the treatment.

We report a new method in the repair of incisional hernia, using the prolene hernia system.

CASE REPORT

On November, 19, 2001, a 70-year-old woman was admitted to our hospital with a complaint of bulging in the right lower portion of the abdomen, which was in accordance with the site of the old operative scar for appendectomy. She had undergone the appendectomy at 40 years old at a near hospital, and a hernioplasty for bilateral inguinal hernia at 50 years old. The operative course was straight forward after both operations. She had also been suffering frequently from asthma for 10 years. In the spring of 2000, bulging in the right lower portion of the abdomen suddenly appeared. The bulging sometimes appeared with no relation to the position, walking, or exertion. On admission, the patient was markedly obese. Her height was 143.4 cm and her weight was 61.5 kg. Her blood pressure was 142/80 mmHg, pulse rate was 64 beats per minute and irregular, and her body temperature was 36.2 °C. In a standing posture, the bulging was apparent in the right lower portion of the abdomen, and it was soft on palpation, however, its

Received for publication August 8, 2002 ; accepted September 5, 2002.

Address correspondence and reprint requests to Dr. Takayuki Miyauchi, Department of Surgery, Tokushima Prefectural Miyoshi Hospital, Shima, Ikeda-Cho, Miyoshi-Gunn, Tokushima 778-0001, Japan and Fax : +81-883-72-6910.

border was unclear. On lying down, the bulging disappeared and a cavity was detected on palpation in accordance with the site of the oblique scar from the operation for acute appendicitis. The other physical examinations showed no abnormalities. The abdominal CT findings showed a defect in the muscle layer in accordance with the area of the hernia. Air density from the prolapsed intestine was found in the subcutaneous fatty layer, and the abdominal muscle was thin (Fig. 1). From these findings, the complaint was diagnosed as an incisional hernia, associated with the operative scar from the old appendectomy. On November 21, 2001, repair of the incisional hernia was repaired under lumbar anesthesia. An 8 cm skin incision was made, crossing the old oblique operative scar in the right lower

portion of the abdominal wall. The subcutaneous fat was carefully dissected, and the hernia sac was located. The sac was freed from the circumferential tissue, and we reached the pre-peritoneal space. The size of the anterior orifice of the hernia on the aponeurosis was 3.5 × 2.0 cm. The hernia sac was opened, revealing adhesion of the large omentum, which was easily freed from the peritoneum. Around the posterior orifice of the peritoneum, the intestine showed no adhesion. We dissected the hernia sac and closed the peritoneum using a continuous suture at the base with No. 3-0 Vicryl (absorbable thread). From the aponeurosis finding, it was suggested that the aponeurosis could not ensure the strength of the tight suture for closing the defect because it was thin and weak, furthermore, the muscle was also thin and weak around the hernia orifice. To reinforce the posterior wall, we decided to use the prolene hernia system. To insert the underlay patch, the pre-peritoneal fatty tissue was freed from the fascia of the transversalis approximately 10 cm in diameter. The underlay patch was inserted beneath the posterior wall of the transverse abdominal muscle with no fixing sutures (Fig. 2). The Onlay patch was placed on the surface of the aponeurosis (Fig. 3) and fixed with interrupted sutures using No. 3-0 Vicryl (Fig. 2). Two aspiration drains were placed on the onlay patch, and then the subcutaneous layer was closed with No. 3-0 Vicryl and the skin with No. 4-0 nylon. The had an excellent post-operative course with no complications. The sump drains were removed on post-operative

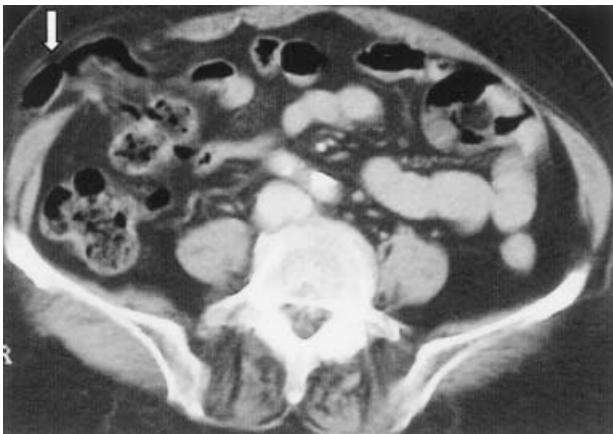

Fig. 1. Findings of abdominal CT. The symbol shows air density, which suggests herniated intestine into the subcutaneous layer.

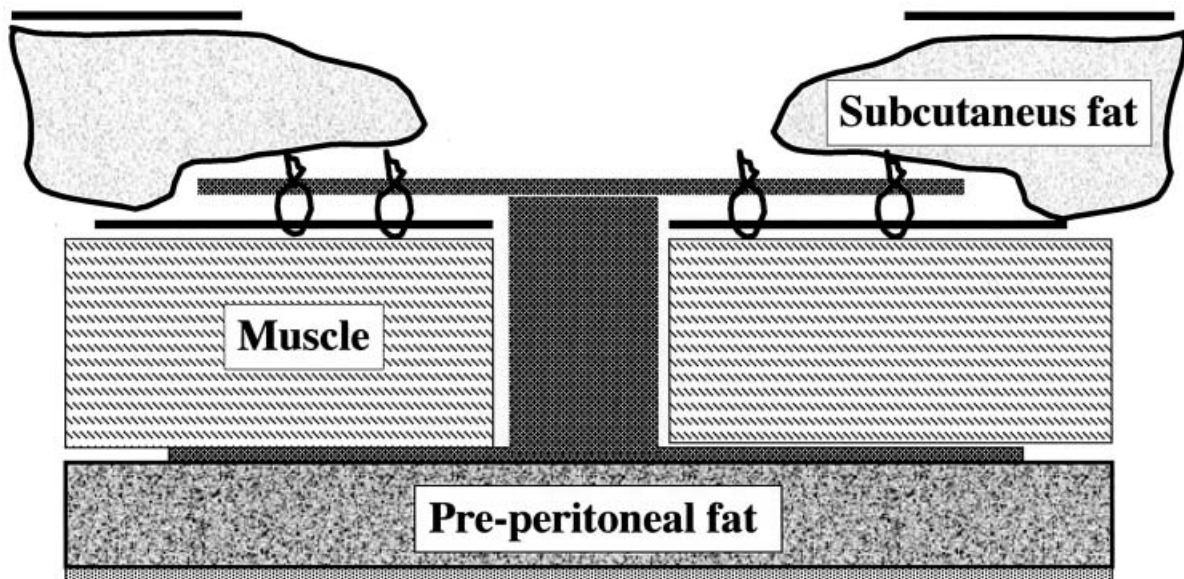


Fig. 2. Operative procedures. The underlay patch was inserted through the hernia orifice and placed in the pre-peritoneal fat layer with no sutures. The connector was placed through the hernia canal, and then the onlay patch was placed on the aponeurosis and fixed with No.3-0 Vicryl (absorbable thread).

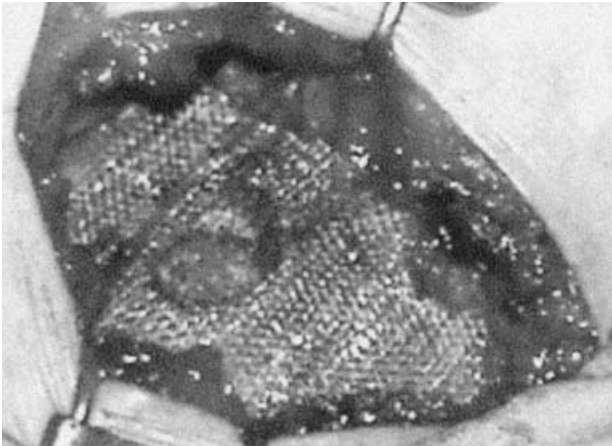


Fig. 3. Operative finding. The onlay patch of the prolene hernia system placed on the aponeurosis.

day 2, and the patient was discharged on post-operative day 10. Three months after the operation, the patient had not complained of trouble.

DISCUSSION

Despite the developments and improvements in suture materials and the closure techniques of abdominal incisions, incisional hernia remains a significant postoperative disorder in abdominal surgery (6, 7).

The incidence of incisional hernia ranges from 2 to 11% after abdominal operations, however, it depends widely on the presence or absence of the following factors: 1) infected and closed wounds; 2) severance of the nerves supplying the muscles in the region of the incision; 3) dehiscence of wounds; 4) hematoma in the wound; 5) marked postoperative abdominal distention; 6) increased intra-abdominal pressure caused by ascites, intra-abdominal tumors, and postoperative cough; 7) obesity (8). With respect to the area of the incisional hernia, Flament *et al.* recently reported; 30.1% in midline supra-umbilical hernia, 29.3% in midline infra-umbilical, both 26.9% in supra- and infra-umbilical, 4% in sub-chondral, 8.1% in inguinal, and 1.2% in the flank (2).

The surgical procedures for incisional hernia are mainly divided into the classic methods and prosthetic repair. The classic methods by simple closure are based on aponeurotic or muscular reconstructive surgery using the structures of the abdominal wall (2). Various procedures have been reported for simple closure, however, these procedures can be used to treat relatively simple incisional hernias when there is no true loss of abdominal

wall substance or a hernia caused by sclerotic retraction of the muscles (2).

On the other hand, prostheses allow the repair of complex herniations and can be used to treat formidable lesions, often considered beyond the scope of surgical repair (2). The ideal material should be as light and as solid as possible, with a certain degree of elasticity and suppleness (2). It is also important that the material be a fairly open mesh structure so that the connective tissue response is able to infiltrate the prosthesis (2). Chevrel described the sites in which prostheses may be inserted as follows: 1. The peritoneal cavity (intra-peritoneal); 2. The peritoneal space (Stoppa procedure), for low midline supra-pubic, or iliac fossa incisional hernias; 3. The prefascial space, posterior to rectus abdominus muscle (Rives procedure) (underlay); 4. Sandwich-like, between two muscle layers, for lateral incisional hernias (interparietal); 5. Patch-like, bridging the gap when closure is impossible (inlay); 6. The premuscular aponeurotic space (Chevrel), for all types of abdominal incisional hernia (onlay) (3).

We recently used a new type, the prolene hernia system double layer device. This new version of the polypropylene mesh patch was conceived as a three-dimensional device. It is a three-in-one attached device that functions as a unit. It has an underlay graft and an onlay graft, held together by a connector. The device comes in three sizes, medium, large, and extended, as follows: Medium; onlay, 10 cm, underlay, 7.5 cm, connector, 1.5 cm. Large; 10 cm, 10 cm, 1.5 cm, respectively. Extended; 12.5 cm, 10 cm, 1.5 cm, respectively (9). In the repair of groin hernias, the underlay patch is placed in the layer of preperitoneal fatty tissue with no fixing sutures, and the onlay patch is inserted between the external and internal oblique muscles, and then laid on the inguinal ligament and the pubic bone surface, with fixing sutures, using the absorbable thread (9). We previously recognized the advantages of the prolene hernia system in the repair of direct, indirect and femoral hernias. It is suggested that its superior advantage is the wide, strong reinforcement of the posterior wall, added to the low risk of post-operative pain. This case showed marked weakness and atrophy in the tissue around the hernia orifice, especially in the anterior oblique aponeurosis and muscle layers. Furthermore, CT revealed prominent muscle weakness and atrophy in a wide region. Therefore, we stressed the necessity of reinforcement of the posterior wall. Fortunately, the hernia

sac was easily freed from the adhesion without damage to the circumferential tissue and we could dissect and enclose the hernia sac completely. The size of the hernia orifice was 3.5×2.0 cm, therefore, we could envelope the hernia orifice by laying the onlay patch on the anterior aponeurosis. The sizes of the devices of the prolene hernia system are limited, therefore, It is suggested that it might not be adequate to cover large incisional hernias. Fortunately, the aponeurosis defect was small in this case, and the prolene hernia system could be fixed easily and the implantation of this device was precise. We think double the layer system of the prolene hernia system reinforces the abdominal wall more tightly than the conventional methods, using a mesh sheet, and stress that the connector is useful for successful implantation to protect migration of the onlay and underlay patches. Furthermore, we suggest that the addition of prolene mesh to this device may be effective for larger incisional hernias.

In conclusion, a new type of prolene hernia system, a double-layer mesh device, was useful for the repair of a small sized incisional hernia, which occurred at an appendectomy scar. This method is easy, and the reinforcement of the abdominal wall is strong. Furthermore, this method can be applied for the repair of large incisional hernias by the addition of prolene mesh sheet.

REFERENCES

1. Feliciano DV : Incisional hernias as emergencies. In : Bendavid R, Abrahamson J, Arregui M, Flament JB, Phillips ED, eds. Emergency surgery. Abdominal wall hernias. Springer-Verlag Inc, New York, 2001, pp582-587.
2. Flament JB, Palot JP, Burde A, Delattre JF, Avisse C : Treatment of major incisional hernias. In : Bendavid R, Abrahamson J, Arregui M, Flament JB, Phillips ED, eds. Open techniques of incisional hernia repair. Abdominal wall hernias. Springer-Verlag Inc, New York, 2001, pp508-516.
3. Chevrel JP : Treatment of incisional hernias by an overlapping herniorraphy and onlay prosthetic implant. In : Bendavid R, Abrahamson J, Arregui M, Flament JB, Phillips ED, eds. Open techniques of incisional hernia repair. Abdominal wall hernias. Springer-Verlag Inc, New York, 2001, pp500-503.
4. Butkow IM, Robbin A : The Mesh Plug Repair. In : Bendavid R, Abrahamson J, Arregui M, Flament JB, Phillips ED, eds. Techniques of open groin hernia repair. Abdominal wall hernias. Springer-Verlag Inc, New York, 2001, pp382-387.
5. Amid PK : Lichtenstein Tension-free hernioplasty for the repair of primary and recurrent inguinal hernias. In : Bendavid R, Abrahamson J, Arregui M, Flament JB, Phillips ED, eds. Techniques of open groin hernia repair. Abdominal wall hernias. Springer-Verlag Inc, New York, 2001, pp423-427.
6. Jenkins TP : The burst abdominal wound : a mechanical approach. Br J Surg 63 : 873-876, 1976
7. Israelsson LA, Jonsson T. Closure of midline laparotomy incisions with polydioxanone and nylon : the importance of suture technique. Br J Surg 81 : 1606-1608, 1994.
8. Santora TA, Roslyn JJ : Incisional hernia. Surg Clin North Am 73 : 557-570, 1993.
9. Gilbert AI, Graham MF, Voigt WJ : Gilbert's repair of inguinal hernias. In : Bendavid R, Abrahamson J, Arregui M, Flament JB, Phillips ED, eds. Techniques of open groin hernia repair. Abdominal wall hernias. Springer-Verlag Inc, New York, 2001, pp377-381.