

ORIGINAL

Angiostatic effects of corticosteroid on wound healing of the rabbit ear

Ichiro Hashimoto^{*}, Hideki Nakanishi^{*}, Yoshitaka Shono^{*}, Maki Toda^{*},
Hidetaka Tsuda^{**}, and Seiji Arase^{**}

^{*} *Department of Plastic and Reconstructive Surgery, and* ^{**} *Department of Dermatology, The University of Tokushima School of Medicine, Tokushima, Japan*

Abstract: Wound healing is a complex biologic process with initial inflammation, granulation tissue formation, and matrix remodeling. We observed the relation between angiostatic effects and corticosteroid administration time in the rabbit ear chamber. Angiogenesis in the chamber was studied using a microscope-television system. Two experiments were undertaken to represent the systemic and the topical administration of steroids. In experiment 1, 10 mg of triamcinolone acetonide was injected three times intramuscularly (on the day of implantation of the chamber, and the 7th and 14th day after implantation). Vascularization in this group was significantly delayed at the 7th, 14th, and 21st days but no difference from controls was observed in the size and density of vessels after its completion. In experiment 2, 3 mg of triamcinolone acetonide was injected once into the skin adjacent to the chamber on the 10th day after installment of chambers or on the day of installment. In the former group, new vascular growth was delayed until the 21st day after installment. The hemorrhagic zone had narrowed and vascular dilation was observed. In the latter group, endothelial budding was delayed and vascular constriction occurred. New vascular growth was severely delayed and granulation filling of the chamber was not completed. These results suggest not only that the topical administration had the stronger inhibitory effect on neovascularization than the systemic administration but that the effect differed depending on the stage of wound healing. In view of this effect of this steroid, we should pay careful attention to the time when steroids are administered to patients. *J. Med. Invest.* 49 : 61-66, 2002

Keywords : *angiogenesis, corticosteroid, wound healing, rabbit ear chamber*

INTRODUCTION

Wound healing of the skin is an important clinical factor for skin surgery, burn injury, and skin ulcers. It is a complex biologic process with initial inflammation, repair (granulation tissue formation), and matrix remodeling (1). Since the repair process comprises

angiogenesis and fibroplasia, angiogenesis is considered to be an indicator of wound healing.

Although suppressive effects on the wound healing by corticosteroids have been recognized (2), details about the relation between these effects and administration time remain unclear. Steroid injection into wounds is performed for treatment of keloids and hypertrophic scars both intra- or post-operatively (3). Sometimes, surgery must be performed on patients undergoing systemic steroid therapy. We undertook two experiments to represent the systemic and the topical administration of steroids. The purpose of this study was to clarify the angiostatic effect of

Received for publication December 3, 2001 ; accepted January 28, 2002.

Address correspondence and reprint requests to Ichiro Hashimoto, M.D., Ph.D., Department of Plastic and Reconstructive Surgery, The University of Tokushima School of Medicine, Kuramoto-cho, Tokushima 770-8503, Japan and Fax : +81-88-633-7297.

corticosteroids during wound healing and to analyze the relation between the effect of this agent and its administration time in the rabbit ear chamber.

MATERIALS AND METHODS

Animals/Rabbit Ear Chamber

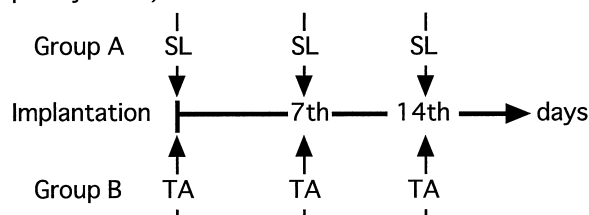
Japanese white rabbits weighing between 2.5 and 3.0 kg were used. Three holes in the edge and one in the center were made on the distal side of the earlobe after removal of the fur with a laser. The rabbit ear chamber was implanted after the epidermis around the central perforation was carefully removed without damaging the cartilage and the subdermal blood vessels. The translucent disk and glass cover of the chamber formed a tissue regeneration space (50 μ m thick) (2, 4). Granulation from the surrounding intact tissue started to grow into this space. The length of the new vascular growth was measured on the monitor TV of the microscope-television system on the days mentioned below. After the round chamber was divided into four parts each of 90 degrees, the vessel growth was rated in the center of each part. The average of the four points was regarded as the growth for that day. The average growth on the observation days was calculated based on the basis of these findings. We observed not only the growth of vessels but also the size of vessels and the condition of flow.

Experimental Groups

Triamcinolone acetonide (Sankyo Co., Ltd, Tokyo, Japan) was used as the corticosteroid and saline as the control. In experiment 1, nine animals each in group, A and B, were injected intramuscularly three times (on the day of implantation of the chamber, and the 7th and 14th day after implantation) with saline (1 ml) or triamcinolone acetonide (10mg, 1 ml), respectively (Fig. 1). The growth of the vessels was assessed on the 5th, 7th, 14th, and 21st day after implantation. In experiment 2, 15 rabbits were divided into three groups (group C, D, and E) and each received two administrations of intradermal injection around the chambers (on the day of implantation and on the 10th day after implantation) (Fig. 1). Similar volumes (0.05 ml at one place and total 0.3 ml) of saline or triamcinolone acetonide were injected intradermally into six places adjacent to the chamber. The total amount of triamcinolone acetonide was 3 mg in each administration. In group C, saline was

Experiment 1

(Intramuscular injection; 10 mg of steroid per injection)



Experiment 2

(Intradermal injection; 3 mg of steroid)

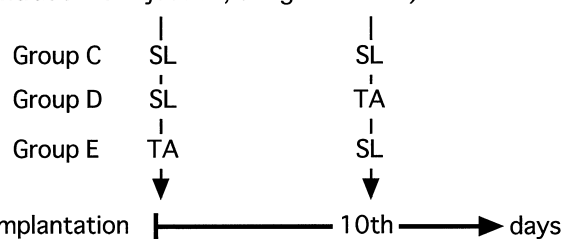


Fig. 1 Schedule of drug administration. SL, saline; TA, triamcinolone acetonide

injected two times, and in group D, saline was injected first and triamcinolone acetonide second. In group E, the triamcinolone acetonide was injected first and saline second. The growth of the vessels was assessed on the 7th, 10th, 14th, 17th, 21st, 24th, and 28th day after implantation.

Statistical Analysis

For all steroid-administered groups and the control group in each experiment, statistical analyses of the between-group differences in average growth of the vessels were performed with the Mann-Whitney U test. *P* values less than 0.05 were regarded as statistically significant.

RESULTS

Experiment 1

In group A (control group), the neovascularization process began with the chamber filled with debris. The progression of the newly formed vessels across the chamber was characterized by a hemorrhagic zone, which is known as a 'fibrin net', prior to distention of the capillary tips. The fibrin net was apparently formed by the extrusion of blood cells through the distended and fragile walls of the blind capillary sprouts as a result of the constant pulsation transmitted from the general circulation through the feeding

vessels. The diameter of the dilated new capillaries then became smaller and formed pre- and post-capillary vessels and eventually arterioles.

The sprouts in group A were observed from the 5th to 7th day (average : 6th day), but in group B from the 7th to 10th day (average : 8th day). The sprouting was delayed significantly ($p < 0.05$) in the steroid-administered group. In the steroid-treated animals, the forcible ebb and flow seen in the newly formed capillaries of the control animals were conspicuously absent, and the hemorrhagic zone prior to budding of the capillaries did not develop. Moreover, a very large proportion of the capillaries were filled with plasma alone, in which a few almost motionless red cells were suspended.

The neovascularization in group B was significantly delayed at the 7th, 14th, and 21st days (Fig. 2). At the completion of the vascularization, however, there was no difference in the size and density of vessels and the condition of flow between the control group and the systemic administration model.

Experiment 2

In group C (control group), endothelial budding, fibrin net, and vascular new growth were observed in the same manner as in group A (Figs. 3, 4). The fibrin net prior to all new vessels was seen on the 17th day. All vessels had started to grow towards the center of the chamber and the fibrin net to diminish on the 21st day. The growth of the new vessels was completed from the 23rd to 25th day.

In group D, sprouts formation and vascular new growth were not delayed until triamcinolone acetate

was injected (Figs. 3, 5). The normal fibrin net was seen on the 17th day, but vascular dilation began to be observed from this time. Delay in vascular new growth was observed and the fibrin net started to become thinner from the 21st day. The granulation filling of the chamber was delayed compared with that of control group. After completion of the vascular growth, however, no differences between groups C and D in size and density of vessels and condition of flow were observed.

The debris of group E was less and moved more slowly than that of groups C and D. In group E, endothelial budding was significantly delayed ($p < 0.0001$) (Figs. 3, 6). The capillary network behind the advancing endothelial sprouts was markedly empty and no hemorrhagic zone prior to capillary budding developed (Fig. 7). Vascular constriction occurred in both arterioles and venules, that is, the blood flow was reduced and intermittent in the area of new vascular growth, which was delayed, while granular filling of the chamber was not completed in group E.

DISCUSSION

There are many models for observing angiogenesis *in vivo*, including the chorioallantoic membrane of the chick embryo, the rabbit or rat cornea, and the hamster cheek pouch (5-7). These models, however, are useful for assessment of angiogenesis from noninjured existing vessels. The rabbit ear chamber model, in which we can observe angiogenesis from injured skin, was suggested to be one of the best

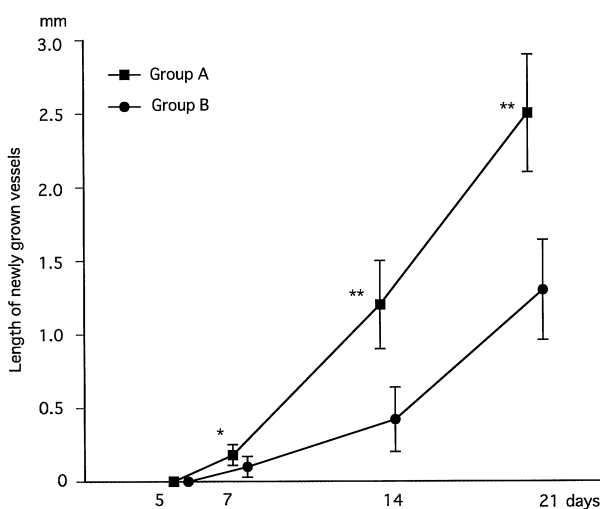


Fig. 2 The average growth of new vessels in experiment 1. Three intramuscular injections of saline and triamcinolone acetate were administered to group A and group B, respectively. (Mean values \pm S.E., * $p < 0.05$, ** $p < 0.01$)

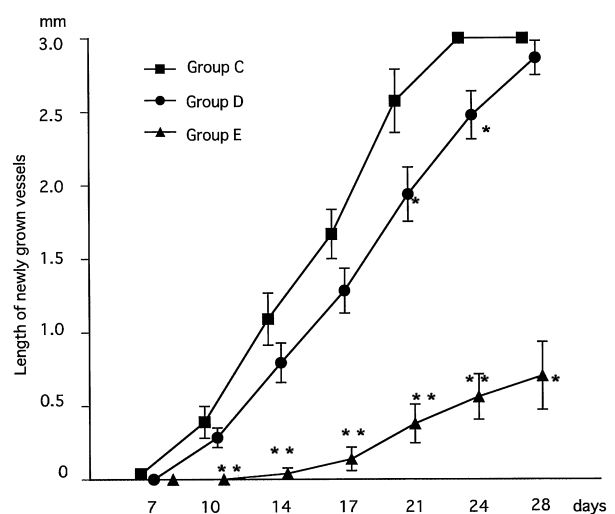


Fig. 3 The average growth of new vessels in experiment 2. Group C is the control group. In group D, triamcinolone acetate was injected on the 10th day, and in group E, on the day of implantation. (Mean values \pm S.E., * $p < 0.05$, ** $p < 0.01$)

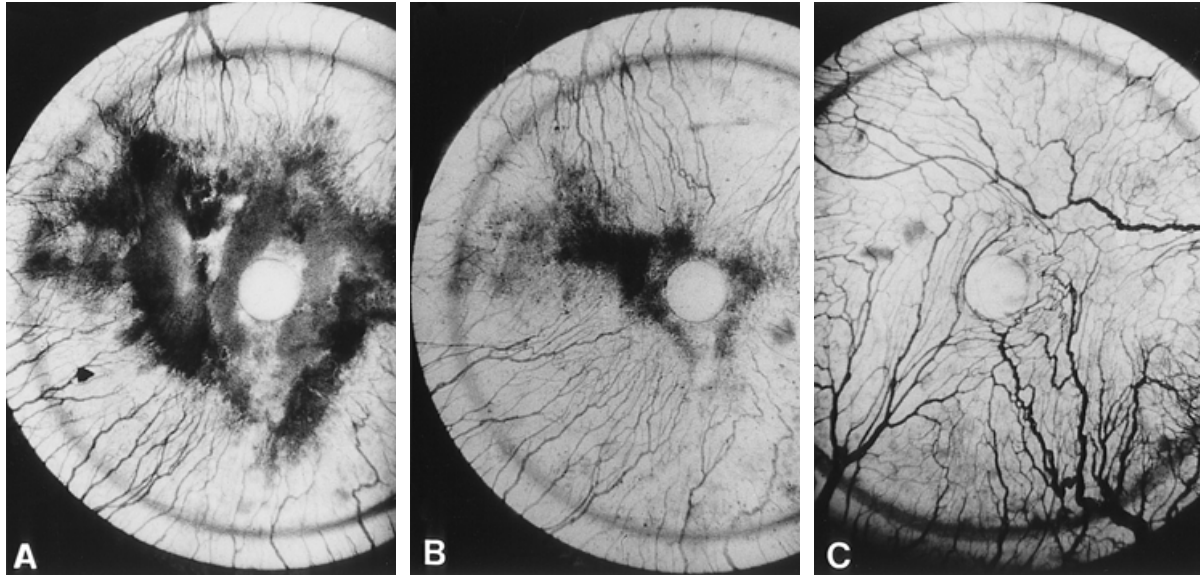


Fig. 4 Group C (control) in experiment 2. A : 17th day after surgery, B : 21st day after surgery, C : 28th day after surgery. Note the fibrin net spread prior to the development of tips of the new vessels.

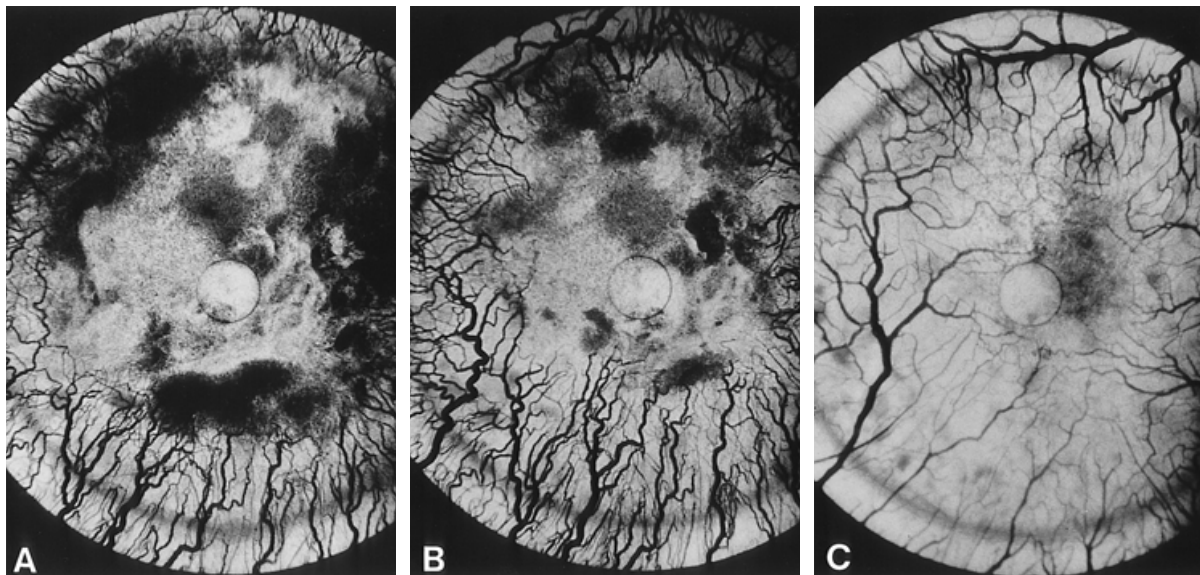


Fig. 5 Group D in experiment 2 (triamcinolone acetate administered on the 10th day after implantation). A : 17th day after implantation, B : 21st day after implantation, C : 28th day after implantation. Note the dilated vessels (A, B) and normal vessels after completion (C).

models for wound healing in the skin.

Inhibition of wound healing by corticosteroids is a well-known phenomenon that was suggested to be caused by the inhibition of the inflammatory phase of healing as well as of matrix synthesis (2, 8-10). Corticosteroids reduce vascular permeability and induce a transient monocytopenia, which results in a decrease in extravasation and migration of inflammatory cells to the sites of injury (11, 12). Corticosteroids inhibit the production of other chemotactic stimuli such as the complement system and lymphocyte-derived chemotactic factor, and also inhibit macrophage activation (13).

The aim of experiment 1 was to confirm the anti-angiogenic activity of corticosteroids upon systemic administration. Despite the administration of 30 mg of triamcinolone acetate, however, we found no differences between the administered group and the control group after completion of vascularization. In the comparison between two methods of administration, it was suggested that the topical administration had the stronger inhibitory effect on neovascularization than the systemic administration. In experiment 2, we found that the inhibitory effect of corticosteroids on neovascularization differed according to the stage of wound healing. When the steroid was administered immediately after injury,

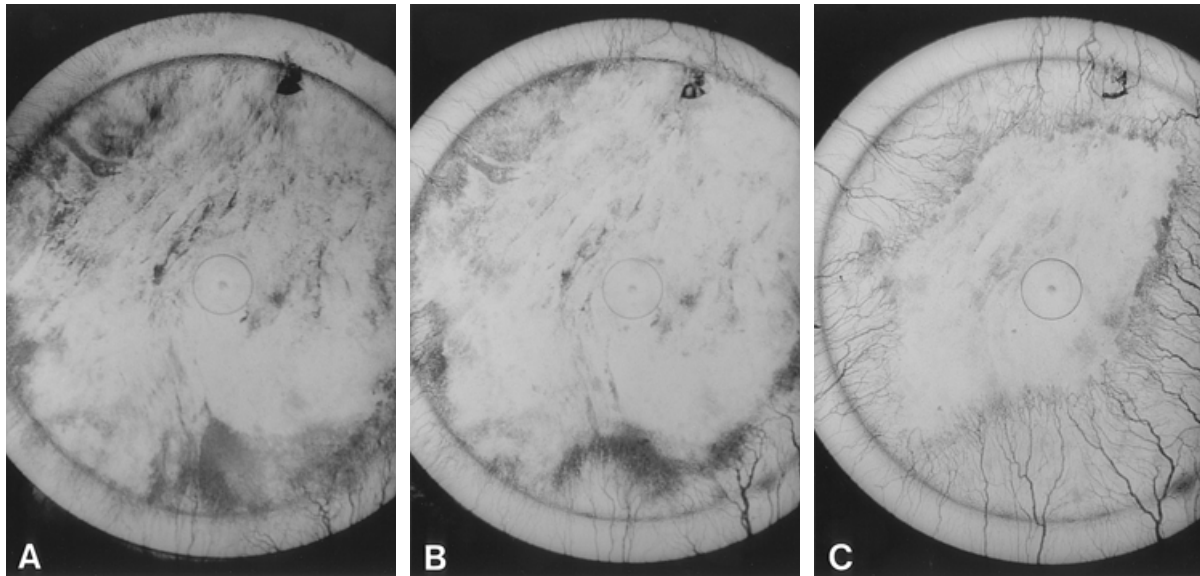


Fig. 6 Group E in experiment 2 (triamcinolone acetate administered immediately after the implantation). A : 17th day after implantation, B : 21st day after implantation, C : 28th day after implantation. Note the thinner fibrin net and constricted vessels.

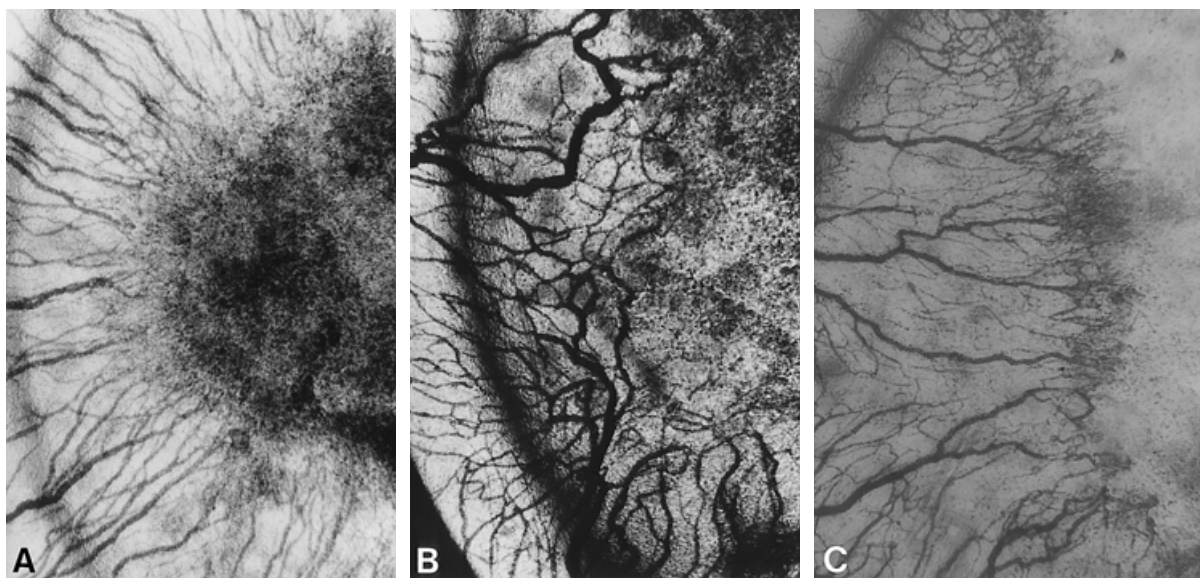


Fig. 7 The fibrin net in group C (A : 17th day after surgery), D (B : 17th day after surgery), and E (C : 28th day after surgery). In group C, the fibrin net was dense and tips of the vessels could not be seen. In group D, it was not dense and tips of the vessels could be seen. In group E, the vessels were constricted and tips of the vessels could be seen due to the diminished fibrin net.

granulation was not completed. It is suggested that the delay in vascular new growth was caused by the inhibition of vascular permeability and matrix synthesis and that this inhibition was due to suppression of some growth factors which are normally expressed during the early stage of wound healing.

Many kinds of growth factors related to angiogenesis have been identified recently. Endothelial growth factor, transforming growth factor- α , β , vascular endothelial growth factor (VEGF), and platelet derived growth factor have been found to accelerate endothelial growth *in vivo* and *in vitro* (14, 15). Due to the finding that VEGF affects mainly endothelial cells and can

also increase vascular permeability, it was suggested to be the most effective factor for endothelial growth. Its expression becomes prominent within 1 to 3 days after injury (16). This suggests that VEGF is an important cytokine for vascular hyperpermeability and angiogenesis in the early stages of wound healing. The findings of the present study demonstrated that suppression of angiogenesis by corticosteroids was more effective before rather than during wound healing. Therefore, corticosteroids may also suppress VEGF or other growth factors active at the beginning of wound healing.

For surgery in steroid-treated patients, the effects

of steroids on wound healing is very important, so that careful consideration should be given to the time and period of their administration.

ACKNOWLEDGMENTS

This work was supported in part by Grant-in-Aids for Encouragement of Young Scientist and for Scientific Research (C) from the Japan Society for the Promotion of Science.

REFERENCES

1. Clark RAF : Cutaneous tissue repair : Basic biologic considerations I. *J Am Acad Dermatol* 13 : 701-725, 1985
2. Ashton N, Cook C : *In vivo* observations of the effects of cortisone upon the blood vessels in rabbit ear chamber. *Br J Exp Pathol* 33 : 445-450, 1952
3. Tang YW : Intra-and postoperative steroid injections for keloids and hypertrophic scars. *Br J Plast Surg* 45 : 371-373, 1992
4. Hashimoto I, Nakanishi H, Shono Y, Tanaka S : The effects of desferrioxamine on thrombus formation in injured microvessels of rabbit ear. *J Med Invest* 46 : 200-204, 1999
5. Gimbrone MA, Cotran RS, Leapman SB, Folkman J : Tumor growth and neovascularization : An experimental model using the rabbit cornea. *JNCI* 52 : 413-427, 1974
6. Greenblatt M, Shubik P : Tumor angiogenesis : Transfilter diffusion studies in the hamster by the transparent chamber technique. *JNCI* 41 : 111-124, 1968
7. Vu MT, Smith CF, Burger PC, Klintworth GK : An evaluation of method to quantitate the chick chorioalantoic membrane assay in angiogenesis. *Lab Invest* 53 : 499-508, 1985
8. Balow JE, Rosenthal AS : Glucocorticoid suppression of macrophage migration inhibitory factor. *J Exp Med* 137 : 1031-1041, 1973
9. Blackwell JI, Carnuccio R, DiRosa M, Flower RJ, Parente L, Persico P : Macrocortin : A polypeptide causing the anti-phospholipase effect of glucocorticoids. *Nature* 287 : 147-149, 1980
10. Claman HN : Corticosteroids and lymphoid cells. *N Engl J Med* 287 : 388-397, 1972
11. Ebert RH, Barclay WR : Changes in connective tissue reaction induced by cortisone. *Ann Intern Med* 37 : 506-518, 1952
12. Haynes BF, Fauci AS : The differential effect of *in vivo* hydrocortisone on the kinetics of subpopulations of human peripheral blood thymus-derived lymphocytes. *J Clin Invest* 61 : 703-707, 1978
13. Gewurz H, Wernick PR, Quie PG, Good RA : Effect of hydrocortisone succinate on the complement system. *Nature* 208 : 755-757, 1965
14. Rudkin GH, Miller TA : Growth factors in surgery. *Plast Reconstr Surg* 97 : 469-476, 1996
15. Steenfos HH : Growth factors and wound healing. *Scand J Plast Reconstr Hand Surg* 28 : 95-105, 1994
16. Brown LF, Yeo KT, Berse B, Yeo TK, Senger DR, Dvorak HF : Expression of vascular permeability factor (vascular endothelial growth factor) by epidermal keratinocytes during wound healing. *J Exp Med* 176 : 1375-1379, 1992