

Human pulmonary dirofilariasis presenting as a small nodule with a cavity

Takanori Sako¹, Naoto Burioka¹, Hisashi Suyama¹, Youichi Kinugasa²,
Masanari Watanabe¹, Kazumitsu Hirai³, and Eiji Shimizu¹

¹Third Department of Internal Medicine, Faculty of Medicine, Tottori University, Yonago, Tottori, Japan ; ²Hakuai Hospital, Yonago, Tottori, Japan ; and ³Department of Medicine Zoology, Faculty of Medicine, Tottori University, Yonago, Tottori, Japan

Abstract : A 73-year-old woman had a 4-year history of lung fibrosis from collagen vascular disease.

She presented with a complaint of dry cough. A chest radiograph showed a 2-cm solitary pulmonary nodule with a small cavity in the right lower lobe. Preoperatively, we performed computed tomography of the chest and measured tumor markers. Video-assisted thoracotomy was performed because we could not rule out lung cancer. Pathologic analysis confirmed the presence of a granuloma with *Dirofilaria immitis*. In Japan, the incidence of human dirofilariasis has steadily increased and must be considered in the workup of cavitory pulmonary nodules. *J. Med. Invest.* 47 : 161-163, 2000

Key words : *dirofilaria immitis*, pulmonary dirofilariasis, zoonotic disease, computed tomography

INTRODUCTION

The dog heartworm *Dirofilaria immitis* can cause solitary pulmonary nodules in humans. Pulmonary *Dirofilaria immitis* is a rare zoonotic disease (1-3). The name of Dirofilariasis comes from the Latin *diro* and *filum* meaning 'evil thread' (4). It is transmitted from dogs to humans by mosquitoes (5). In Japan, approximately 120 cases have been reported (6,7). Most patients with *Dirofilaria immitis* are asymptomatic. A solitary pleural-based nodule is the most common radiographic finding (8). In this report, we present a case of *Dirofilaria immitis* with a solitary cavitory nodule in the right lung field.

CASE REPORT

A 73-year-old woman with hypertension and a 4-year history of lung fibrosis due to rheumatoid

arthritis presented in December 1997 complaining of a dry cough she had had for 1 week. She denied having fever or chest pain. Findings on physical examination were normal except for fine crackles on auscultation. Laboratory studies were normal except for elevation of the antinuclear antibody ($\times 160$) and rheumatoid factor (48 IU/mL). The C-reactive protein was not elevated. The white blood cell count and the eosinophil count were normal. Her rheumatoid arthritis was managed with NSAID, and she had not yet received steroid treatment. Therefore she was not under immunosuppression by drugs at this time. Immunoelectrophoresis and ELISA were negative for *Dirofilaria immitis*. A chest radiograph showed a 2-cm noncalcified solitary pulmonary nodule in the right lower lobe (Fig.1). High-resolution computed tomography of the chest showed a subpleural cavitory nodule with spiculated margins in the right basal lateral segment. There were not other nodules or adenopathy (Fig.2). A percutaneous transthoracic fine needle aspiration biopsy under computed tomographic guidance was not diagnostic, and video-assisted thoracoscopic surgery (VATS) was performed. At surgery, the lesion in the posterior seg-

Received for publication June 15, 2000 ; accepted July 12, 2000.

Address correspondence and reprint requests to Takanori Sako, M.D., Third Department of Internal Medicine, Faculty of Medicine, Tottori University, 36-1, Nishimachi, Yonago 683-8503 Tottori, Japan and Fax : +81-859-34-8098

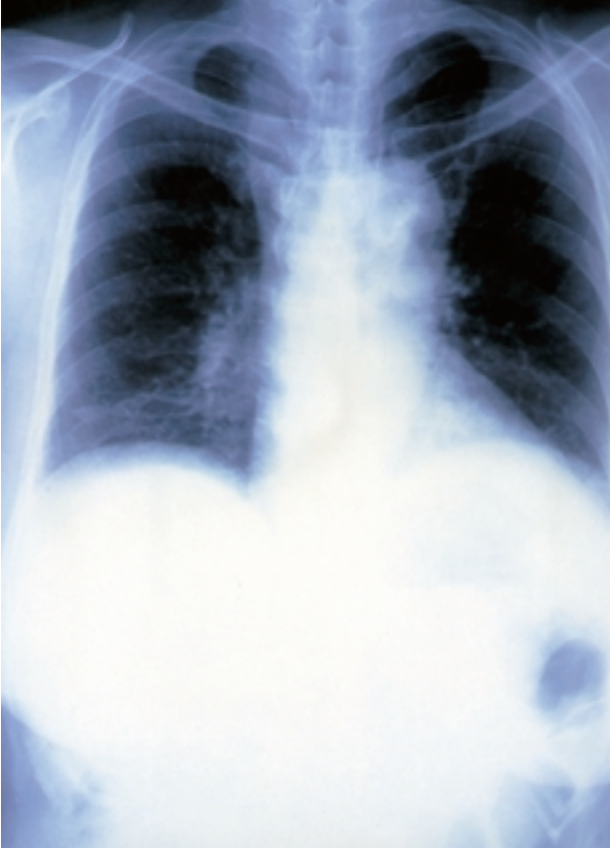


Fig. 1. Chest radiography shows a 2-cm noncalcified solitary pulmonary nodule in the right lower lobe.

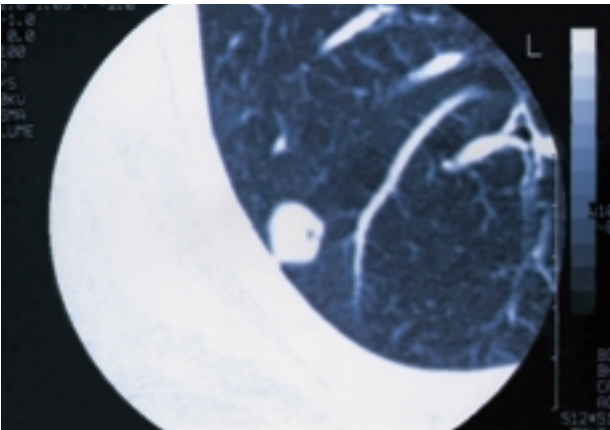


Fig. 2. High-resolution computed tomography scan of the chest shows a small cavity in the subpleural nodule with spiculated margins in the right basal lateral segment.

ment of the right lower lobe was adherent to the parietal pleura and was removed with the use of a wedge excision. Frozen sections showed a benign mass and pathologic analysis showed a granuloma containing the worm.

Pathology

On gross examination, the nodule was 2 to 3 cm in diameter and was round and grayish yellow (Fig.3). Microscopic examination showed a formed, circum-

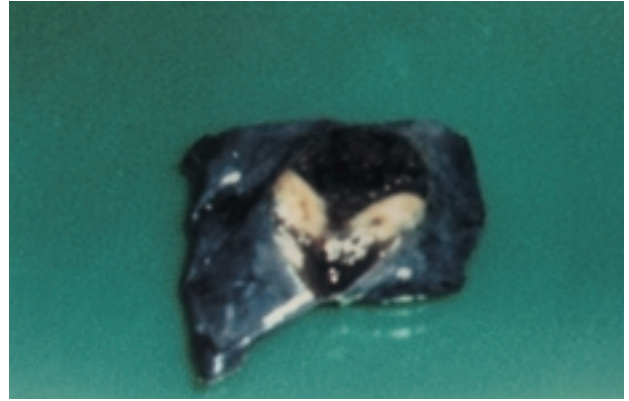


Fig. 3. Photograph of the surgical specimen containing the pulmonary nodule. The nodule was 2 to 3 cm in diameter and was rounded and grayish yellow

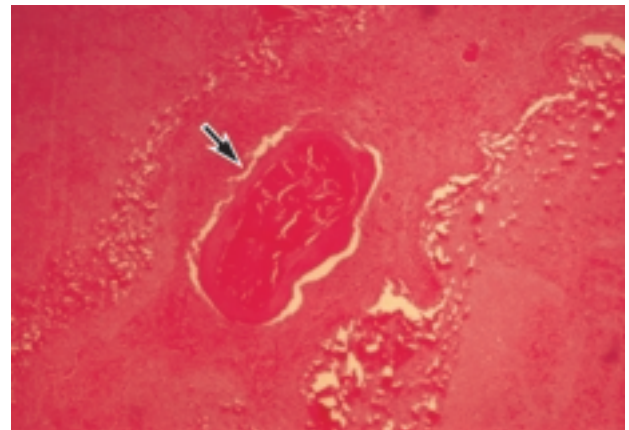


Fig. 4. The lesion is a formed, circumscribed granuloma that contains a fragment of the parasite. There is a central core of necrosis surrounded by a wall of fibrotic tissue containing epithelial cells, plasma cells, and fibroblasts. (Hematoxylin and eosin stain, $\times 100$ before reduction.) Arrow shows the worm body in the vessel.

scribed granuloma that contained fragments of a parasite that had features of *Dirofilaria immitis*, such as a smooth surface and internal longitudinal ridges. There was a central core of necrosis surrounded by a wall of fibrocystic tissue containing epithelial cells, plasma cells, and fibroblasts.

DISCUSSION

All routine laboratory studies in this patient were within normal limits except that the serum antinuclear antibody concentration was elevated ($\times 160$). High-resolution computed tomography of the chest showed a cavitary, subpleural nodule with spiculated margins in the right basal lateral segment; there were no other nodules or adenopathy. Tissue obtained by VATS showed pulmonary *Dirofilaria immitis*.

In 1887, de Magalhaes reported the first human infection with *Dirofilaria* in a male child from Rio de Janeiro (9). In Japan, it was first reported in 1968.

Between 1968 and 1995, there have been 120 cases reported in Japan. Human dirofilariasis has been diagnosed in all parts of Japan except the northernmost mainland of Hokkaido. Most (74%) of the nodules were located in the right lung. Forty-nine percent of the right lung nodules were in the lower lobe. A single worm section was present in 90% of nodules (8). In a review of the literature of human pulmonary dirofilariasis, sufficient attention has not been paid to the relationship between nodule and cavity (6,9,10). Human pulmonary dirofilariasis is a benign condition. The dog is the usual host and the mosquitoes are the normal vector-intermediate hosts. The sexually mature female worm often resides in the canine right ventricle. Humans are "dead-end hosts" since larvae cannot develop into their adult forms in humans. Transmitted by mosquitoes, humans are accidental hosts for *Dirofilaria immitis*, and infection only results in the development of a small, solitary peripheral pulmonary nodule (11-13). *Dirofilaria immitis* is usually discovered on a routine radiograph as a solitary, noncalcified, pleural-based nodule. Serologic tests are available but lack sufficient sensitivity and specificity to be useful diagnostically; in the present case immunoelectrophoresis was negative. In addition, ELISA was also negative. Some cases of *Dirofilaria immitis* may be diagnosed by fine needle aspiration biopsy (FNAB). However, FNAB is not 100% conclusive, and surgical resection is generally required to make an unequivocal diagnosis (10). In this case, the cavitation raised our suspicions of lung cancer. Histopathology clearly demonstrated that the cavity observed on CT was due to the collapse of necrotic tissue. We believe that antigens from the dead nematode diffused radially into lung tissues and caused a vasculitis with thickening and obstruction of small surrounding vessels. It was the gradual narrowing and occlusion of these vessels that led to necrosis. Thus pulmonary *Dirofilaria immitis* should be included in the differential diagnosis of a cavitary pulmonary subpleural nodule. Since humans are dead-end hosts, treatment is unnecessary. The importance of the infection is due to the fact that these lesions are often radiographically mistaken for a manifestation of primary or metastatic lung

cancer. Because of the peripheral location of the lesions, a pulmonary wedge resection may be required for diagnosis and resection to avoid an unnecessary thoracotomy.

REFERENCES

1. Cordero M, Muro A, Simon F, Tapia J, Eponia E : Are transient pulmonary solitary nodules a common event in human dirofilariasis? *Clin Invest* 70 : 437-440, 1992
2. Barrigia O : *Dirofilariasis*. *Parasitic zoonoses* 2 : 93-109, 1982
3. Beaver PC, Jung RC, Cupp EW : *Human dirofilariasis*. *Clin parasitology* 1 : 363-431, 1984
4. Breitenbacher A, Gayer R, Giachino D, Mordasini C : Multiple Pulmonary Nodules. *Respiration* 65 : 91-94, 1998
5. Nicholson C, Allen M, Trastek V, Tazelaar H, Pairolero P : *Dirofilaria immitis* : a rare, increasing cause of pulmonary nodules. *Mayo Clin Proc* 67 : 646-650, 1992
6. Makiya K : Recent increase of human infections with dog heart worm *Dirofilaria immitis* in Japan. *Parassitologia* 39 : 387-388, 1997
7. Makiya K, Tsukamoto M, Manabe H, Asano S, Iwata Y : A human case of pulmonary dirofilariasis suspected to be lung cancer. *J UOEH* 9 : 227-232, 1987
8. Echeverri A, Long R, Check W, Burnett C : Pulmonary dirofilariasis. *Ann Thorac Surg* 67 : 201-202, 1999
9. Mrugeshkumar K : Human Pulmonary *Dirofilaria immitis* : Review of the Literature. *South Med J* 92 : 276-279, 1999
10. Bailey T, Sohrabi A : Pulmonary coin lesions caused by *Dirofilaria immitis*. *J Surg Oncol*. 44 : 268-272, 1990
11. Watson J, Wetzel WJ, Burkhalter J : Human disease caused by dog heartworm. *J Miss State Med Assoc* 32 : 399-401, 1992
12. Harrison E Jr, Thompson J Jr : *Dirofilaria immitis* of human lung. *Am J Clin Pathol* 43 : 224-234, 1965
13. Merrill JR, Otis J, Logan WD Jr : The dog heart worm in man. *JAMA* 243 : 1066-1068, 1980