

The utility and limitations of an ultrasonic miniprobe in the staging of gastric cancer

Seisuke Okamura*, Akemi Tsutsui*, Naoki Muguruma*, Soichi Ichikawa*, Masahiro Sogabe*, Yoshio Okita*, Tamotsu Fukuda*, Shigehito Hayashi*, Toshiya Okahisa*, Hiroshi Shibata*, Susumu Ito*, and Toshiaki Sano†

*Second Department of Internal Medicine, and †First Department of Pathology, The University of Tokushima School of Medicine, Tokushima, Japan

Abstract : To determine the utility and limitations of an ultrasonic miniprobe (UMP) in the staging of gastric cancer, we evaluated 46 patients who underwent endoscopic ultrasonography (EUS) using an UMP and who were histologically determined to have gastric cancers. In every case, UMP findings were compared with histopathological findings after treatment. The total accuracy of UMP relative to the depth of tumor invasion was 71.7% (33/46 cases). Accuracy with respect to T1-m tumor diagnosis was 75.7% (22/29 cases), and for T1-sm, 76.9% (10/13 cases), but accuracy for T2 tumor diagnosis was low, due to ultrasound attenuation. When the analysis was carried out based on the size of tumor, the accuracy for UMP was 50.0% (9/18 cases) for all tumors over 20 mm and 85.7% (24/28 cases) for all tumors smaller than 20 mm. We conclude that UMP is suitable for investigation of tumor extension when the lesion is superficial and / or small gastric cancers which do not cause ultrasonic attenuation, but not when the tumor is large or located in certain sites, although conventional EUS is useful in some of these cases.

J. Med. Invest. 46 : 49-53, 1999

Key words : endoscopic ultrasonography, ultrasonic miniprobe, gastric cancer

INTRODUCTION

Accurate staging is an important consideration in the management cases of gastric cancer, since this staging is the basis on which treatment decisions are made. Endoscopic ultrasonography (EUS) is generally considered to be the most accurate method for the locoregional staging of gastric cancer (1-3). This is due to its ability to visualize the different layers of the wall of the gastrointestinal tract (4), as well as its role in demonstrating lymph nodes (5).

Conventional EUS is performed with a side-viewing instrument containing a small ultrasonic transducer incorporated in the tip which generates high frequency ultrasonic images (7.5 to 20 MHz). Recently,

a radial scanning ultrasonic miniprobe (UMP) has been developed (6-7). The UMP is inserted through the instrument channel of a standard endoscope with a diameter of 2.5 mm and a rotating 12 or 20 MHz transducer for radial imaging. The UMP permits the scanning of lesions under direct endoscopic visualization within the water-filled gastric lumen (8).

In this study, we assess the utility and limitations of a UMP in terms of the staging of gastric cancer.

MATERIALS AND METHODS

Subjects

Forty six patients who underwent EUS using a UMP in this department between April 1995 and July 1997 and who were histologically determined to have gastric cancers were included in this study. EUS using a UMP was performed prior to treatment after obtaining informed consent of the patient ; 25 patients underwent gastrectomy and the remaining

Received for publication November 11, 1998 ; accepted December 16, 1998.

Address correspondence and reprint requests to Seisuke Okamura, M.D., Ph.D., Second Department of Internal Medicine, The University of Tokushima School of Medicine, Kuramoto-cho, Tokushima 770-8503, Japan and Fax : +81-88-633-9235.

21 patients underwent endoscopic mucosal resection. For all cases, the UMP findings were compared with the histopathological findings in endoscopically or surgically excised specimens after treatment (Table 1).

High frequency UMP

The UMP used in this study was a model UM-3R (Olympus, Tokyo, Japan). The probe was inserted through the instrument channel of an endoscope of diameter 2.4 mm with a 20 MHz high frequency rotating transducer for radial imaging (8). The UMP permits the scanning of lesions under direct endoscopic visualization within the water-filled gastric lumen. For the standard endoscopy, GIF-Q200 or GIF-Q230 (Olympus, Tokyo, Japan) endoscopes were used.

Diagnosis of the depth of tumor invasion

The depth of tumor invasion was determined according to the Union Intern Contra Cancrum TNM classification (9). Additionally, we classified T1 tumor as T1-m, where the tumor remained in the mucosa, or T1-sm, where the submucosa was invaded.

On EUS using a UMP, the diagnostic criteria for the depth of tumor invasion is the same as that for dedicated conventional EUS (1). Briefly, stage T1-m was diagnosed when the tumor invasion was limited to the mucosa, T1-sm was diagnosed when the tumor invasion was limited to the submucosa, stage T2 when the wall layer structure was destroyed but the outer margin was smooth or only slightly irregular, stage T3 when transmural tumor growth was

detected, and stage T4 in cases of invasion into adjacent organs.

Diagnosis of regional lymph nodes metastasis

Lymph node metastasis was diagnosed based on previously established criteria (5), i.e. hypoechoic, roundish and well-demarcated nodes were assumed to be malignant, whereas hyperechoic and elliptoid nodes with indistinct margins were assumed to be benign.

RESULTS

Accuracy of UMP with reference to the depth of tumor invasion

Table 2 shows the accuracy of UMP relative to the depth of tumor invasion in the 46 patients with gastric cancer. The total accuracy was 71.7% (33/46 cases). The accuracy for T1-m tumor was 75.7% (22/29 cases), and for T1-sm 76.9% (10/13 cases), but the accuracy relative to the T2 tumor was low due to ultrasound attenuation. When the analysis was carried out based on the size of tumor (Table 3), the accuracy for UMP was 50.0% (8/19 cases) for all tumors over 20 mm and 85.7% (24/28 cases) for all tumors smaller than 20 mm. When analyzed

Table 1. Clinicopathological findings in 46 patients with gastric cancer

Sex	
Male	34
Female	12
Macroscopic appearance of lesion	
Elevated	27
Flat	0
Depressed	19
Histological type	
Well differentiated	25
Moderately differentiated	10
Poorly differentiated	7
Signet ring cell	4
Treatment	
Endoscopic mucosal resection	21
Gastrectomy	25
	n=46

Table 2. Accuracy of ultrasonic miniprobe in the depth of tumor invasion in 46 patients with gastric cancer

Histologic results \ UMP findings	UMP findings			Accuracy
	T1-m	T1-sm	T2	
pT1-m	22	7		22/29 (75.7%)
pT1-sm	2	10		10/13 (76.9%)
pT2-mp		1	1	1/2 (50.0%)
pT2-ss			2*	0/2 (0.0%)
				33/46 (71.7%)

UMP : ultrasonic miniprobe

*Not diagnosed due to ultrasonic attenuation

Table 3. Accuracy of ultrasonic miniprobe in the depth of tumor invasion in 46 patients with gastric cancer analyzed by the size of tumor

Size of tumor (mm)	Accuracy	
<20	<10	8/10 (80.0%)
	10 ~ 20	16/18 (88.9%)
	total	24/28 (85.7%)
20		9/18 (50.0%)

based on the location of the tumor (Table 4), the accuracy for UMP was 86.7% (13/15 cases) for tumors in the antrum, 53.3% (8/15 cases) in the angles, 73.3% (11/15 cases) in the body and 100% (1/1 case) in the fornix.

Accuracy of UMP with reference to the preoperative detection of regional lymph node metastasis

Of the 25 cases which underwent gastrectomy, 6 (24.0%) had lymph node metastasis.

Preoperative detection of regional lymph nodes with UMP was possible in only 2/6 cases, 33.3% (Table 5).

Case reports

Case 1 : Figure 1 shows the UMP image of a superficial depressed type gastric cancer in the anterior wall of the body (diameter 5 mm). The focal area of tumorous thickening is observed to be limited to the mucosa, but the submucosa is intact. This case was thus diagnosed as having IIc type gastric cancer in stage T1-m, and as a result underwent endoscopic mucosal resection. The histological findings confirmed the presence of a superficial depressed carcinoma localizing in the mucosa (Figure 2).

Case 2 : Figure 3 shows the UMP image of an ulcerative and infiltrated type gastric cancer in the posterior wall of the body (diameter 54 mm). It was not possible to diagnose the depth of tumor invasion because of ultrasound attenuation. This case under-

went gastrectomy. The histologic findings revealed an ulcerative and infiltrated carcinoma invading to the subserosa (Figure 4).

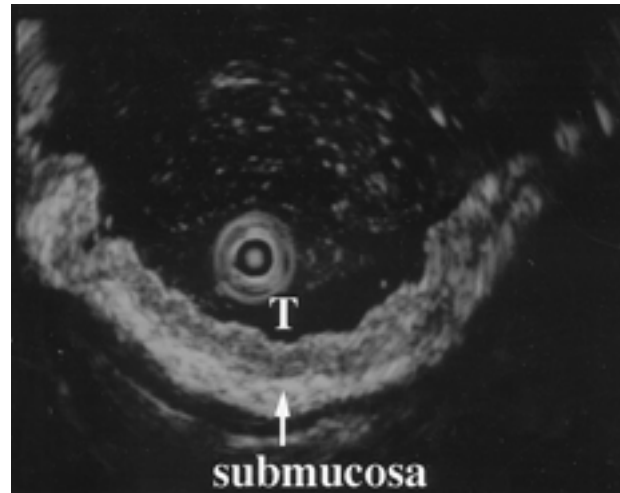


Fig.1. The UMP image of Case 1. A focal area of tumorous thickening (T) is observed to be limited to the mucosa, but the submucosa is intact.

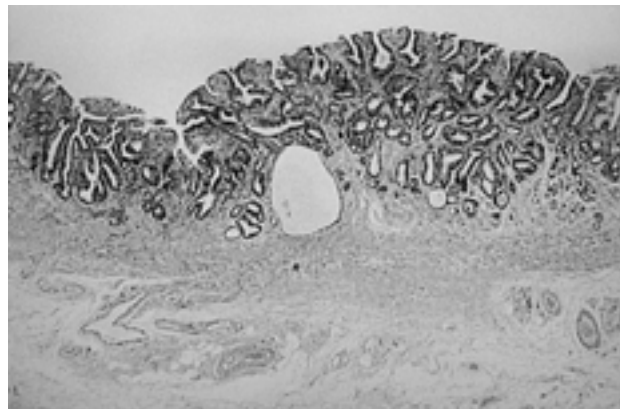


Fig. 2. The histological findings of Case 1. A superficial depressed carcinoma localizing in the mucosa.

Table 4. Accuracy of ultrasonic miniprobe in the depth of tumor invasion in 46 patients with gastric cancer analyzed by the location of tumor

	Anterior	Posterior	Lesser curvature	Greater curvature	Accuracy rate
Antrum	3/4	4/4	4/4	2/3	13/15 (86.7%)
Angle	2/3	0/1	5/10	1/1	8/15 (53.3%)
Body	2/2	8/11	1/2		11/15 (73.3%)
Fornix		1/1			1/1 (100.0%)
	7/9 (77.8%)	13/17 (76.4%)	10/16 (62.5%)	3/4 (75.0%)	33/46 (71.7%)

Table 5. Accuracy of ultrasonic miniprobe in the preoperative detection of regional lymph nodes metastasis

No of Cases	Positive lymph nodes metastasis (%)	Detection with ultrasonic miniprobe (%)
25	6/25 (24.0%)	2/6 (33.3%)

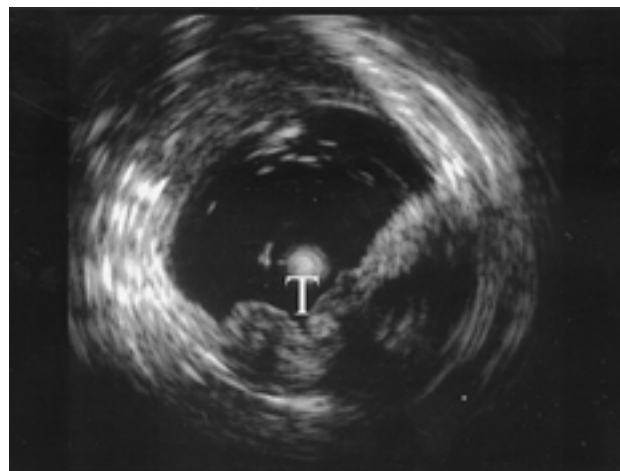


Fig. 3. The UMP image of Case 2. The depth of invasion of the tumor (T) cannot be diagnosed due to ultrasound attenuation.

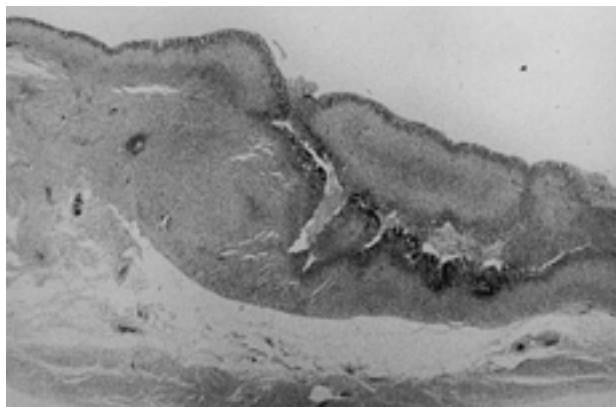


Fig. 4. The histological findings of Case 2.
An ulcerative and infiltrated carcinoma invading to the subserosa.

DISCUSSION

Gastric cancer is a disease of the elderly in the Western world, and not all patients are sufficiently robust to undergo a gastrectomy. Furthermore, the huge difference in prognosis between T1 or T2 cancer and T3 or T4 cancer influences decisions regarding endoscopic or surgical treatment (10-13). As a result, the accurate staging of gastric cancer is of crucial importance in the management of this type of case. Various studies support the view that EUS is a very accurate technique in the staging of gastric cancer, and that it is superior to other imaging methods, such as extracorporeal ultrasonography and CT (1-3, 14-15).

The UMP is inserted through the instrument channel of a standard endoscope, and is then used to scan a lesion at anytime during an endoscopic examination. Moreover, the UMP permits the scanning of lesions under direct vision. In conventional EUS, diagnosis of small mucosal lesions is difficult, due to the fact that the lesion is either compressed by the balloon, or out of focus and, therefore not visualizable. Small mucosal lesions can be scanned with less difficulty than with a conventional EUS (6-8) and the UMP produces an image with finer resolution.

These advantages make this probe useful in assessing superficial and/or small gastric cancers. To our disappointment, studies using the conventional EUS were made on the basis of the TNM staging system, in which T1 includes both m and sm invasion depth, and does not distinguish between the two (1-3, 16). Some investigators have studied the differentiation of m from sm cancer, but its accuracy ranges from 63.3% to 71.4% (17-19). In the present study, the

accuracy of T1-m tumor diagnosis was 75.7%, and T1-sm 76.9%. When the analysis was carried out based on the size of tumor, the accuracy for UMP was 85.7% for all tumors smaller than 20 mm. In our opinion, the UMP will be useful for the determination of a need for endoscopic mucosal resection in mucosal gastric cancer.

In this study, the accuracy of assessment was low for tumors over 20 mm in size, probably due to the ultrasound attenuation. Determination of the extent of tumor invasion is not always possible with UMP, due to the limited depth of penetration (8). The accuracy of assessment was lower for tumors located in the vicinity of the gastric angle, probably due to the fact that it is difficult to place the probe parallel to the lesion in this region.

Detection of regional lymph node metastasis is possible, but is limited due to the small depth of visualization of the UMP (about 25 mm in diameter). In this study, the rate of preoperative detection of regional lymph node metastasis with UMP was 33.3%. The accuracy of conventional EUS in preoperative detection of regional lymph node metastasis ranges from 50% to 87% (1, 3, 16) due to the greater penetration depth of ultrasound (about 60 mm diameter).

We concluded that the UMP is suitable for the investigation of tumor extension when the lesion is superficial or for small gastric cancers which do not cause ultrasonic attenuation, but not when the tumor is large or located in certain sites, although conventional EUS is useful in some of these cases. It is recommended that a UMP and an optimal frequency of sound be selected, taking into consideration the features of a given case, when EUS is performed for gastric cancer.

REFERENCE

1. Dittler HJ, Siewert JR : Role of endoscopic ultrasonography in gastric carcinoma. *Endoscopy* 25 : 162-166, 1993
2. Kiff RS, Taylor BA : Comparison of computed tomography, endosonography and intraoperative assessment in TN staging of gastric carcinoma. *Gut* 35 : 287-288, 1994
3. Rosch T : Endosonographic staging of gastric cancer : a review of literature results. *Gastrointest Clin North Am* 5 : 549-557, 1995
4. Kimmy MB, Martin RW, Haggit RC, Wang KY, Franklin DW, Silverstein FE : Histologic correlates of gastrointestinal ultrasound images.

- Gastroenterology 96 : 433-441, 1989
5. Tio TL, Tytgat GNJ : Endoscopic ultrasonography in analysing periintestinal lymph node abnormality. *J Gastroenterol* 21 : 158-163, 1986
 6. Silverstein FE, Martin RW, Kimmy MB, Jiranek GC, Franklin DW, Proctor A : Experimental evaluation of an endoscopic ultrasound probe : In vitro and in vivo canine studies. *Gastroenterology* 96 : 1058-1062, 1989
 7. Rosch T, Classen M : A new ultrasonic probe for endosonographic imaging for upper GI tract. *Endoscopy* 22 : 41-46, 1990
 8. Frank N, Grieshammer B, Zimmermann W : A new miniature ultrasonic probe for gastrointestinal scanning : Feasibility and preliminary results. *Endoscopy* 26 : 4603-608, 1994
 9. Sobin LH, Hermanek P, Hutter RP : TNM classification of malignant tumors. *Cancer* 61 : 2310-2314, 1988
 10. Tada M, Murakami A, Karita M, Yanai H, Okita K : Endoscopic resection of early gastric cancer. *Endoscopy* 25 : 445-450, 1993
 11. Yasuda K, Mizuma Y, Nakajima M, Kawai K : Endoscopic laser treatment for early gastric cancer. *Endoscopy* 25 : 451-454, 1993
 12. Yamano T, Shirao K, Ono H, Kondo H, Saito D, Yamaguchi H : Risk factors for lymph-node metastasis from intramucosal gastric carcinoma. *Cancer* 77 : 602-6, 1996
 13. Sano T, Kobori O, Muto T : Lymph-node metastasis from early gastric cancer. : endoscopic resection of tumor. *Br J Surg* 79 : 241-244, 1992
 14. Caletti GC, Ferrari A, Brocchi E, Barbara L : Accuracy of endoscopic ultrasonography in the diagnosis and staging of gastric cancer and lymphoma. *Surgery* 113 : 14-27, 1993
 15. Collin-jones DG, Rosch T, Dittler HJ : Staging of gastric cancer by endoscopy. *Endoscopy* 25 : 34-38, 1993
 16. Tio TL, Schouwink MH, Cikot RJLM, Tytgat GNJ : Preoperative TNM classification of gastric carcinoma by endosonography in comparison with the pathological TNM system : a prospective study of 72 cases. *Hepatogastroenterology* 36 : 51-56, 1989
 17. Nakazawa S, Nakamura T, Yoshino J. : Endoscopic ultrasonography. In : Oguro Y, Takagi K, eds. *Endoscopic approaches to cancer diagnosis and treatment*. Japan Scientific Press, Tokyo, 1990, pp 41-56
 18. Kimura K, Yamanaka T, Yoshino J. : Endoscopic ultrasonography. in the assessment of depth of invasion of gastric cancer. In : Takemoto T, Kawai K, eds. *Recent topics of digestive endoscopy*. Excerpta Medica, Tokyo, 1987, pp 70-76
 19. Yasuda K, Nakajima M, Kawai K. : Malignant lesions of the gastrointestinal tract. In : Kawai K, eds. *Endoscopic ultrasonography in gastroenterology*. Igaku-shoin, Tokyo, 1988, pp 56-71