

# Immunohistochemical diagnosis and significance of forensic neuropathological changes

Shin-ichi Kubo<sup>\*</sup>, Osamu Kitamura<sup>†</sup>, Yoshiyuki Orihara<sup>‡</sup>, Mamoru Ogata<sup>§</sup>, Itsuo Tokunaga<sup>\*</sup> and Ichiro Nakasono<sup>†</sup>

<sup>\*</sup>Department of Legal Medicine, The University of Tokushima School of Medicine, Tokushima, Japan ; <sup>†</sup>Department of Forensic Medicine, The Jikei University School of Medicine, Tokyo, Japan ; <sup>‡</sup>Department of Legal Medicine, Nagasaki University School of Medicine, Nagasaki, Japan ; and <sup>§</sup>Department of Legal Medicine, Faculty of Medicine, Kagoshima University, Kagoshima, Japan

**Abstract :** Immunohistochemistry is very useful when investigating the cause of death. Ischemic cell changes in the hippocampal neurons were not obvious in the brains damaged by hypoxic injury. However, it is suggested that even a moderate hypoxia, which may affect the neuronal proteins and metabolism, induced astrocytosis in the CA3 and CA4 regions, and that in patients with a history of hypoxic attacks neuronal damage may be severe even several hours after ischemic injury. Furthermore, hsp70 expression was found in the CA2, CA3 and CA4 regions of long-term survivors after severe hypoxic/ischemic injury. In forensic practice, detailed information about the duration and extent of a hypoxic/ischemic injury is often unavailable, so that immunohistochemical detection of hsp70 and glial cell staining can be of great value in diagnosing not only the hypoxic/ischemic injury during the process of death but also the victim's past history of hypoxic attacks. In diffuse axonal injury, degeneration of axon and myelin, such as swelling and waving, were observed in survivors of more than 8 hours. Retraction balls appeared in survivors of more than 1 days. In longer term survivors, such as 3 or 5 months, breakdown of myelin and fat-granule cells were observed. In addition, retraction balls were also found. Immunohistochemical staining of 200 kD neurofilament was a very useful method to examine axonal changes, because antisera is specific for degenerative neurofilaments. In our study, all cases which had pathological findings of diffuse axonal injury (DAI) were associated with focal head injuries. From the immunohistochemical staining of neurons in the hippocampus, it was suggested that neurons in the hippocampus were injured by diffuse brain damage. Furthermore, repairing and protective mechanisms occurred especially from CA2 to CA4. It was considered that neuronal damage in diffuse brain injury was elucidated not only morphologically but also functionally. Therefore, in cases of suspected diffuse brain damage, it is recommended to examine the neuronal changes in addition to observing the findings of diffuse axonal injury. Immunohistochemical staining of the carotid body is potentially very useful for necropsy diagnosis, since it provides a method to detect evidence of mechanical asphyxia in suspected cases of manual and/or ligature strangulation. *J. Med. Invest.* 44 : 109-119, 1998

**Key Words :** forensic neuropathology, immunohistochemistry, ischemic brain damage, diffuse axonal injury, carotid body.

## INTRODUCTION

According to the development of the immunohistochemistry (IH) and various antibodies for IH, the neuropathological investigation has spread from morphological to functional observation.

In forensic neuropathology, immunohistochemistry is very useful when investigating the cause of death.

In this review, we introduce our immunohistochemical investigation for neuropathological changes in forensic autopsy cases (1-6, 62). The avidin-biotin complex (ABC) method and/or labeled streptavidin biotin (LSAB) method were used in the immunohistochemical procedure. The primary antibodies and lectin used in this review are listed in Table 1.

Received for publication December 19, 1997 ; accepted January 5, 1998.

<sup>1</sup> Address correspondence and reprint requests to Shin-ichi Kubo, M.D., Ph.D., Department of Legal Medicine, The University of Tokushima School of Medicine, Kuramoto-cho, Tokushima 770-8503, Japan and Fax : +81-886-33-7084.

Table 1. The primary antibodies and lectin in this review.

for neuron
microtubule associated protein 2 (MAP2)
72 kD heat shock protein (hsp72)
<i>c-fos</i> gene product (c-Fos)
acidic fibroblast growth factor (a-FGF)
basic fibroblast growth factor (b-FGF)
for astrocyte
glial fibrillary acidic protein (GFAP)
vimentin
for microglia
Retinus Communis agglutinin-I (RCA-I)
for neurofilament
200 kD neurofilament (NF200)
for neuropeptide
enkephalin (EK)
vasoactive intestinal peptide (VIP)

## 1. HYPOXIC/ISCHEMIC BRAIN DAMAGE

The CA1 pyramidal cells and neurons in the third, fifth and sixth neocortical layers are these most vulnerable to hypoxic / ischemic injury (7, 11, 13, 15-17, 29, 31, 38). Few neuropathological changes occur in the neurons immediately after hypoxic/ischemic injury, but neuronal ischemic changes begin to appear in the human brain after several hours. Furthermore, neuronal necrosis and / or a loss of neurons is found in patients after long-term survival (11, 13, 15-17, 31, 38).

Astrocytes react to hypoxic/ischemic injury by conversion to reactive forms and proliferation in the regions showing neuronal necrosis (9-11, 24, 32, 33, 42). Microglia are transformed into rod cells that have rod-shaped nuclei and processes in the regions showing neuronal necrosis (9, 11, 23, 27). In the destroyed tissue, these microglia become rounded and contain fat droplets in their cytoplasm and are termed lipid-laden macrophages or lipid phagocytes (11). These glial reactions are proportional to the extent of neuronal alterations (9-11, 23, 24, 27, 32, 33).

Exposure of the cells to various forms of stress, such as heat, ischemia and alcohol, induces the synthesis of heat shock protein species (8, 21, 36, 37), and in an immunohistochemical study, the induction of a 70-kD heat shock protein (hsp70) was found to be far lower in the CA1 pyramidal cells than in the CA3 region. These findings suggest that heat shock proteins, such as hsp70, may play an important role in protection against hypoxic/ischemic injury and other pathological conditions (8, 21, 36, 37, 41).

A neuropathological study of 41 forensic autopsy cases of hypoxic/ischemic brain damage was undertaken, using immunohistochemical staining to detect the 72-kD heat shock protein (hsp72) for neuron, glial fibrillary acidic protein (GFAP) and vimentin as markers for astrocytes and the lectin *Retinus Communis* agglutinin-I (RCA-I) for the microglial marker. The sample used for this study came from forensic autopsy cases, and the cases were

divided into 3 groups. Group A (n=33) : sudden death with no history of hypoxic attacks ; Group B (n=4) : long term-survival after hypoxic/ischemic injury with no history of hypoxic attacks ; Group C (n=4) : sudden death or long term-survival with a history of hypoxic attacks.

In our study, no ischemic changes were found in the brain tissue following sudden death (Group A), although swelling of astrocytes were seen in 16 cases. In the early stage of hypoxic / ischemic injury, astrocytes showed a swelling of their cell bodies, which is a significant sign in diagnosing a hypoxic/ischemic injury (12). However, such swelling also occurs in post-mortem autolysis. Because of a lack of detailed information about duration and severity of hypoxic / ischemic injury, it was not clear whether these 16 cases differed from the other 10 cases showing no astrocytic swelling. Therefore, GFAP immunostaining was unable to distinguish whether this astrocytic swelling was due to hypoxic/ischemic injury or post-mortem changes.

Table 2 summarized the findings in the cases of group B and group C.

In the 2-5 hours survival period of Group B, some neurons in the neocortex and the CA1 sector showed ischemic cell changes, i.e., shrinkage of the cell bodies, eosinophilia or dark staining of the cytoplasm with Klüver-Barrera 5 stain (KB), and deformity and pyknosis of the nuclei. In 2 cases of 2-5 hours survival (Case 1 and 2-Table 2), swelling of astrocytes was observed, but no microglial reaction was found.

In a case of 18days survival in Group B (Case3-Table2), no neurons of the hippocampus showed ischemic change, although laminar necrosis was seen in the third, fifth and sixth cortical layers. The cell bodies of many neurons showed an hsp70-positive staining, as did some nuclei in the CA2, CA3 and CA4 regions. However, there was weak or no hsp70 immunoreactivity in the CA1 pyramidal cells. GFAP-positive astrocytes were numerous in the neocortex (Fig.1a and b) and vimentin-positive cells proliferated in the regions showing neuronal necrosis (Figs.1 c and d). A proliferation of microglia was observed in the neocortex regions manifesting neuronal necrosis (Fig.2 a). In this case, many of the microglia were transformed into rod cells (reactive microglia) with bipolar processes and rod-shape nuclei (Fig.2b), and other microglia manifested short processes and roundish cell bodies.

In a case of 120 days survival in Group B (Case4-Table2), a severe subtotal loss of neurons was seen in both the hippocampus and the second to sixth layers of the neocortex. In this case, astrocytosis in the neocortex was more marked than in the case of 18 days survival (Fig.1e-h) and GFAP-positive cells had proliferated throughout the hippocampus, and vimentin-positive cells were numerous in the CA1 sector, but there were fewer in the CA2, CA3 and CA4 regions. Numerous microglia such as lipid-laden cells were in the brain after 120 days survival (Fig. 2c).

In patients surviving for 4-12 h after cardiac arrest, the neocortex showed ischemic cell changes and neuronal changes in the hippocampus were invariable. Severe

Table 2. Summary of the findings in the cases of group B (cases 1-4) and group C (cases 5-8)

Case	Region of brain	Neurons		Astrocytes		Microglia
		Morphological changes	Hsp70	GFAP	Vimentin	
1	CA 1	+	-	-	-	-
	CA 2	-	+	-	-	-
	CA 3/4	-	+	-	-	-
	Neocortex	+	NT	-	-	-
2	CA 1	+	-	-	-	-
	CA 2	-	+	-	-	-
	CA 3/4	-	+	-	-	-
	Neocortex	+	NT	-	-	-
3	CA 1	-	-	-	-	-
	CA 2	-	+	-	-	-
	CA 3/4	-	+	++	-	-
	Neocortex	++	NT	+	+	+
4	CA 1	+++	-	++	++	++
	CA 2	+++	-	++	+	++
	CA 3/4	+++	-	++	+	++
	Neocortex	+++	NT	++	++	++
5	CA 1	-	-	-	-	-
	CA 2	-	-	-	-	-
	CA 3/4	-	-	+	-	-
	Neocortex	+	NT	-	-	-
6	CA 1	-	-	-	-	-
	CA 2	-	+	-	-	-
	CA 3/4	-	+	+	-	-
	Neocortex	+	NT	-	-	-
7	CA 1	-	-	-	-	-
	CA 2	-	+	-	-	-
	CA 3/4	-	+	++	-	-
	Neocortex	+	NT	-	-	-
8	CA 1	++	-	-	-	-
	CA 2	-	-	-	-	-
	CA 3/4	-	+	+	-	-
	Neocortex	+	NT	-	-	-

Morphological changes : -no change ; +mild ; ++severe ; +++subtotal or total loss of neurons  
 Hsp 70 : -negative or weakly positive in some neurons ; +prominently positive in many neurons  
 GFAP : -no reaction ; +mild proliferation ; ++severe proliferation  
 Vimentin : -negative ; +mild proliferation ; ++severe proliferation  
 Microglia : -no reaction ; +rod cells ; ++lipid-laden cells  
 NT : not tested

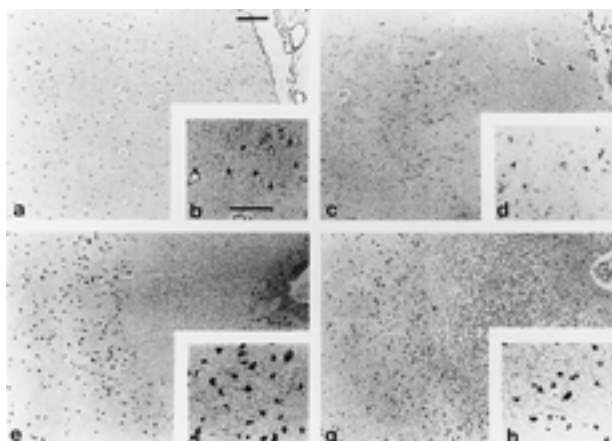


Fig. 1. Astrocytic reactions : immunohistochemical staining with GFAP (left ; a, b, e, f) and vimentin (right ; c, d, g, h). Proliferation of GFAP-positive cells throughout the neocortex (a, b) and vimentin-positive cells proliferation confined to the region of neuronal necrosis (c, d) in a patient surviving for 18 days after strangulation (case 3). Pronounced proliferation of GFAP-(e, h) and vimentin-(g, h) positive cells around the region of neuronal loss in a patient surviving for 120 days after acute respiratory failure (case 4). These astrocytes (f, h) had larger cell bodies and processes than those of case 3. Bar=200µm (a, c, e, g) ; bar=100µm (h, d, f, h)

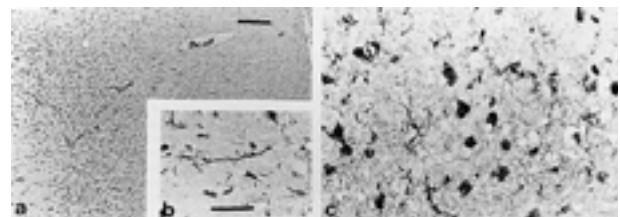


Fig.2. Microglial reactions with RCA-1 staining. A proliferation of microglia including rod cells (a, b) in the neocortex of a patient after 18 days survival (case 3). A proliferation of lipid-laden macrophages (c) in the patient surviving for 120 days (case 4). Bar=200µm(a) ; bar=50µm (b, c)

neuronal necrosis or a loss of neurons is accompanied by a glial reaction in the brain of long-term survivors after cardiac arrest (7, 11, 13). In contrast to a deprivation of the blood supply, as in cardiac arrest, a reduction in the cerebral blood flow induces neuronal changes in the neocortex, especially in the arterial boundary zone, but this does not necessarily damage the hippocampus (11). Since the arterial boundary zone of parieto-occipital lobe is most remote from the origin of each major artery, it is most vulnerable to a reduction in cerebral blood flow. In

our study, the findings in cases of long-term survival with no history of hypoxic attacks were relatively consistent with those of previous studies.

Ischemia includes several pathophysiological conditions, i.e., hypoxia, hypercapnea, acidosis and reduction of energy supply (11, 20, 26). However, the mechanisms of neuronal changes due to ischemia are not entirely clear. Furthermore, it is not clear how and whether pure hypoxia, which induces the release of amino acids, calcium uptake, and activation of several proteases, causes ischemic cell changes (20, 26). Based on observations from human and animal brain tissue, it has been suggested that hypoxia (anoxia) causes no ischemic cell change, and that morphological changes in the neurons may be a consequence of circulatory failure due to hypoxemia (anoxemia) (11, 20, 26, 35, 40).

In 3 cases of Group C (Case 5-7-Table 2), ischemic cell changes were seen in the neocortex, whereas no neurons showed any ischemic changes in the hippocampus. In one case with tetralogy of Fallot (TOF) (Case 8-Table 2), the CA1 pyramidal cells showed neuronal necrosis (Fig. 3a) and ischemic cell changes were seen in the neocortex. GFAP-positive astrocytes had proliferated in the CA3 and CA4 regions (Fig. 3b), and these proliferating cells showed no vimentin immunoreactivity. No microglial reactions were seen in this group.

In 3 cases with more than 2 hours survival, hsp70 immunoreactivity was found in the CA2, CA3 and CA4 neurons (Fig. 4a and b.).

It also has been reported that even 10 min of anoxia

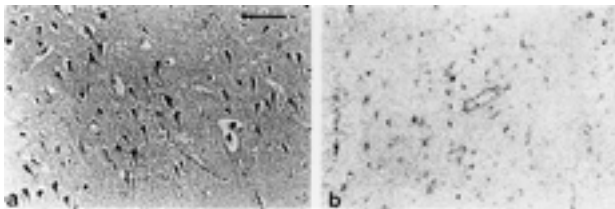


Fig. 3. Neuronal necrosis in the CA1 sector, stained with H.E.(a) and a proliferation of GFAP-positive astrocytes in the CA3 and CA4 regions (b) in a case of tetralogy of Fallot, surviving 2 hours after a traffic accident. Bar=200 $\mu$ m

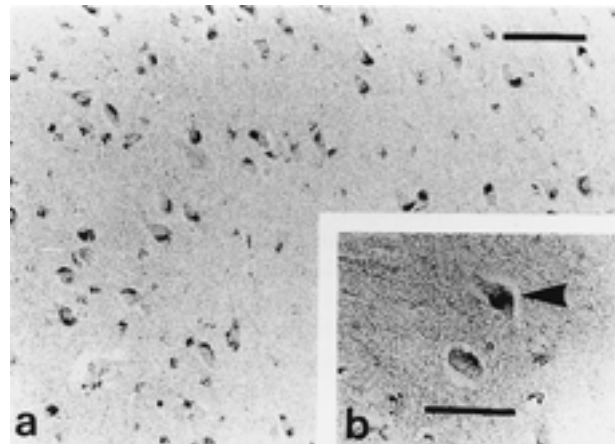


Fig. 4. Hsp 70 immunohistochemistry. Strongly positive neurons in the CA3 and CA4 regions (a) in the patient surviving for 8-10 hours after aspiration of a foreign body. In these neurons (b), most immunoreactivity occurred in the cytoplasm and occasional immunostaining in the nucleus (arrow). Bar=100 $\mu$ m ; bar=50 $\mu$ m

induces a decrease in the immunoreactivity to microtubule-associated protein 2 (MAP2), a cytoskeletal protein, in the hippocampus (20). Therefore, these findings suggest that repeated hypoxic attacks, such as asthma attacks, may impair some neuronal proteins to some extent, and neurons which are vulnerable to ischemia, such as CA1 pyramidal cells, may show more advanced alterations after severe stress, as in the patient with a history of hypoxic attacks.

In the rat hippocampus after ischemia, GFAP-positive and vimentin-positive astrocytes only appeared in the CA1 region showing neuronal necrosis, whereas GFAP-positive and vimentin-negative cells were seen not only in the CA1 region but also in the CA3 region, which shows neuronal viability (23, 27). Based on these finding and those of our study, vimentin could be a useful marker for neuronal necrosis. The stimuli which provoke an astrocytic reaction in a non-damaged area may differ from the stimuli that affect the damaged area, as reviewed by Petito et al. (33), since many factors have been identified *in vivo* or *in vitro*, including cytokines (25), growth factors (22), steroids (30, 39), protein kinase C and prostaglandin E2 (34).

In our study, a proliferation of GFAP and vimentin-positive astrocytes were found in regions of severe neuronal changes. However, GFAP-negative and vimentin-positive cells had proliferated in the CA3 and CA4 regions in a patient surviving for 18 days and in patients with a history of hypoxic attacks. Astrocytosis was also seen in cases of sudden death including heavy alcoholics, a toluene abuser, an epilepsy patient and a patient with a history of self-administration of antipsychotic drugs. These findings would indicate that a relatively mild hypoxic episode can induce the proliferation of GFAP-positive and vimentin-negative astrocytes, and such astrocytosis may be induced by epilepsy or toxic disorders. Microglial reactions were found in the area showing neuronal necrosis in long-term survival patients. However, there were no microglial reactions in the CA3 and CA4 regions in which GFAP-positive cells had proliferated. Thus, it is possible that microglia do not react to mild hypoxic/ischemic injury, whereas astrocytes do react.

In the brains of long-term survival patients (Group B and C), neurons in the CA2, CA3 and CA4 regions showed a definite hsp70 immunoreactivity, whereas weak or no hsp70 immunostaining was seen in the CA1 sector. In cases of alcoholic intake or toluene abuse just before death, the hsp70 distribution resembled the pattern seen in the hippocampus of long-term survivors. In other studies, the induction of species of the heat shock protein was seen after exposure to various types of stress, such as heat, ischemia, and alcohol (8, 21, 36, 37, 41). The significance of hsp70 expression is not clear. After transient ischemia, weak or no hsp70 immunoreactivity was induced in the CA1 pyramidal cells, whereas a significant increase in hsp70 immunostaining was noted in the CA3 region (18). The hsp70 immunoreactivity in CA1 neurons increased after 2 min of ischemia and a further increase in hsp70 immunoreactivity was seen in the CA1 pyramidal cells after a second ischemic attack (28). Furthermore, an early recovery of protein synthesis was noted in the CA1 region.

It has also been reported that transient ischemia, which is in itself not lethal to neurons, induced a tolerance to subsequent ischemic injury (14, 19). These studies seem to indicate that ischemic stress, which is lethal to the CA1 neurons, impairs the cellular metabolism, including the hsp70 expression in the CA1 sector, and that such stress induced hsp 70 in other regions of the hippocampus. Therefore, it is suggested that the hsp70 expression in the hippocampus found in our study reflected a hypoxic/ischemic injury and other stress prior to death.

## 2. DIFFUSE AXONAL INJURY AND ITS NEURONAL CHANGES IN THE HIPPOCAMPUS

The pathological concept of a diffuse axonal injury (DAI) is used as a clinical term of diffuse brain injury (DBI) (43-50). Generally, DAI is not associated with focal head injury, such as intracranial hematoma, fracture of the skull and contusion. Furthermore, Adams reported DAI with focal head injury as a microscopic DAI (51). This type of DAI is very important when investigating the cause of death in forensic autopsy cases (4, 51-55). However, only the pathological concept of DAI is difficult to explain all clinical symptoms and signs in cases of diffuse brain damage. The DAI should be considered as one type of diffuse brain injury. We suspected not only axonal injury but also the neuronal injury in cases of diffuse brain injury. Therefore, we investigated axonal changes and neuronal changes in diffuse brain injury with immunohistochemistry.

### 2-1. Axonal changes

Eighteen cases of non-missile closed head injury, and 6 control cases were used for the study of diffuse axonal injury. Control cases were associated with heart failure, bleeding, smothering, strangulation, hanging and asthma attack.

Pathological findings of diffuse axonal injury were examined in regions of the corpus callosum, the dorsolateral part of the midbrain and the superior cerebellar peduncle. Staining methods employed were hematoxylin-eosin (HE) stain, as a general stain, KB stain for myelin, and Bodian's stain for axon. Furthermore, immunohistochemical staining with anti-200 kD neurofilament antisera were applied using the labeled streptavidin biotin method.

From 18 cases, 11 cases (61.1%), showed pathological findings of diffuse axonal injury. In the 8 hours survival patient, using KB staining, ballooning, swelling and waving of myelin were observed. Bodian's stain showed ballooning, swelling and waving of axons. Some axons were various-sized. In neurofilament staining, axonal changes observed by Bodian's stain were more easily found, because anti-200 kD neurofilament antisera can specifically detect degenerative neurofilament (Fig. 5).

Two days survivors showed degenerative various-sized myelin, such as ballooning, swelling and waving with KB stain. Using HE staining, myelin changes were also observed and pink colored retraction balls were found. Bodian's staining showed axonal retraction balls, and swelling and waving of axons. By immunohistochemical staining, retraction balls and degenerative axons appeared (Fig. 6).




Fig. 5. Eight hours survivor (x200) : a ; (HE), b ; swelling of myelin (KB), c ; swelling and waving of axon (Bodian), d ; swelling and waving of neurofilament (immunohistochemical staining of 200 kD neurofilament).

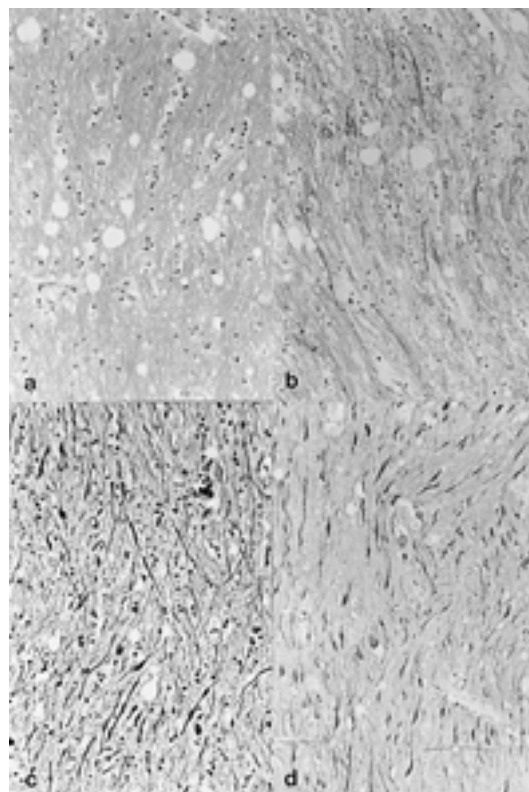


Fig. 6. Two days survivor (x200) : a ; (HE), b ; degeneration of myelin (KB), c ; axonal retraction ball, and swelling and waving of axon (Bodian), d ; axonal retraction ball (immunohistochemical staining of 200 kD neurofilament).

In 5 months survivors, gliosis and fat-granule cells were observed using HE staining. KB staining showed granules, breakdown of myelin and partial swelling of myelin. Using Bodian  $\delta$  stain, almost all axons were broken down, and in addition they remained swollen and waved. However, retraction balls were difficult to find, because of proliferated microglia. However, immunohistochemical staining for neurofilaments specifically showed partially remained degenerative axons and retraction balls (Fig. 7).

In summary, degeneration of axons and myelin, such as swelling and waving were observed in survivors of more than 8 hours. Retraction balls appeared in survivors of more than 1 day. In longer term survivors, such as 3 or 5 months, breakdown of myelin, and fat-granule cells were observed, and retraction balls were also found. Immunohistochemical staining of 200 kD neurofilament was a very useful method to examine the axonal changes, because the antisera is specific for degenerative neurofilaments. In our study, all cases which had pathological findings of DAI were associated with focal head injuries.

### 2-2. Neuronal changes

Neuronal changes were examined in 14 of the 18 cases because one patient with a highly damaged hippocampus and 3 cases of respirator brain were excluded. We examined the hippocampus with HE and KB stain. Immunohistochemically, microtubule-associated protein 2 (MAP2) (56), 200kD neurofilament (NF200), enkephalin (EK), vasoactive intestinal peptide (VIP) (57, 58), 72kD heat

shock protein (HSP72) (59), c-fos gene product (c-Fos) (60, 61), and acidic and basic fibroblast growth factor ( $\alpha$ ,  $\beta$ -FGF) were stained. Pathological findings were estimated in each regions of Ammon  $\delta$  horn.

The case of instantaneous death showed no significant difference with control cases. The 5 months survivor lost almost neurons. In the other 12 cases, all antisera, except for  $\alpha$ -FGF, stained neurons positively. However, the results were very different between the CA1 region and the regions from CA2 to CA4.

To gain a better understanding of neuronal changes, two cases, a short time survivor and a 2 days survivor are illustrated. The short time survivor showed no significant difference of neuronal appearance between CA1 and CA3. However, in the 2 days survivor, neurons in CA1 shrank and were partially lost. However there were no obvious changes in CA3 neurons (Fig. 8).

MAP2 is a cytoskeleton protein of neurons. In the CA3 region of short time survivors, neurons were stained homogeneously. So, it appeared that cells were not damaged. CA1 neurons of this case were weakly stained, the results showed cell damage. The 2 days survivors showed focal staining of MAP2. This pattern was due to progressive degeneration. Therefore, neuron degeneration occurred from the CA1 region just after injury. Thereafter, it spread to other regions, i.e., CA2 to CA4 according to survival




Fig. 7. Five months survivor (x200) : a ; gliosis and fat-granule cells (HE), b ; breakdown of myelin (KB), c ; breakdown of axon, partially remained swelling and waving of axon (Bodian), d ; partially remained swelling and waving of neurofilament (immunohistochemical staining of 200 kD neurofilament).

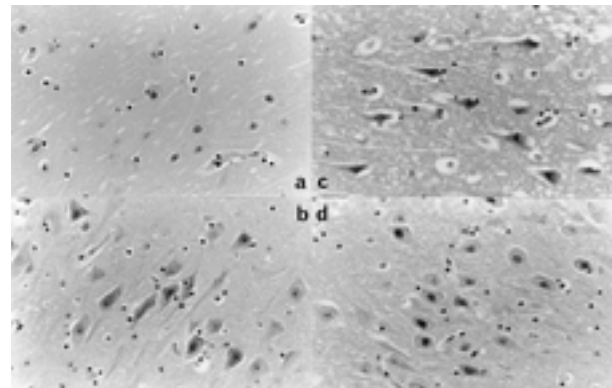


Fig. 8. Neuronal changes in hippocampus (HE, x200). a and b ; short time survivor, c and d ; 2 days survivor, a and c ; CA1 region, b and d ; CA3 region.

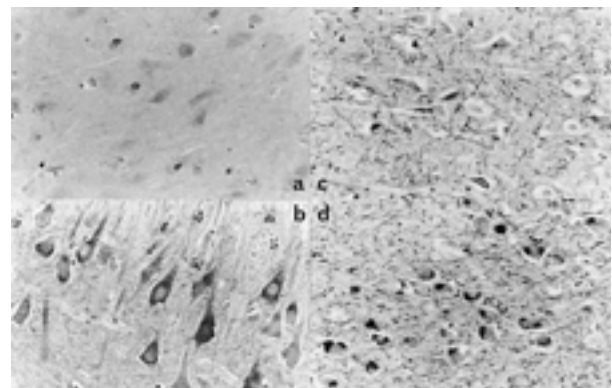


Fig. 9. Neuronal changes in hippocampus (MAP2, x200). a and b ; short time survivor, c and d ; 2 days survivor, a and c ; CA1 region, b and d ; CA3 region.

duration (Fig.9).

Neurotransmitter VIP could not be found in CA1, but was stained in CA3 of a short time survivor. In the 2 days survivor, VIP were weakly stained in CA 1 and strongly in CA3. VIP serves as a means of protection against neuronal damage such as ischemia (58). So, it is suspected that VIP in neurons might be produced by a cell protection mechanism (Fig. 10).

Hsps appears following stress, and has the ability to resist against cell death. Hsp72 was observed in the CA3 region in both short and long term survivors (Fig. 11).

c-Fos is one gene product of apoptosis. Recently, it has been suggested that c-Fos has a possible relation to the cascade mechanism against cell death. c-Fos was also observed in the CA3 region in both short and long term survivors. From these results, it was considered that hsp72 and c-Fos resist cell death in the hippocampus except in the CA1 region (Fig. 12).

In the CA1 region of short time survivors, b-FGF was weakly stained. Neurons in CA3 of short time survivors and both CA1 and CA3 of 2 days survivors were stained by b-FGF. Strongest staining was found in CA3 of 2 days survivors. Basic-FGF is involved in the repair of damaged neurons. So, it was suggested that neurons especially in the CA 2 to CA 4 regions were repaired by b-FGF (Fig.13).

For the purpose of observing neuronal changes, the

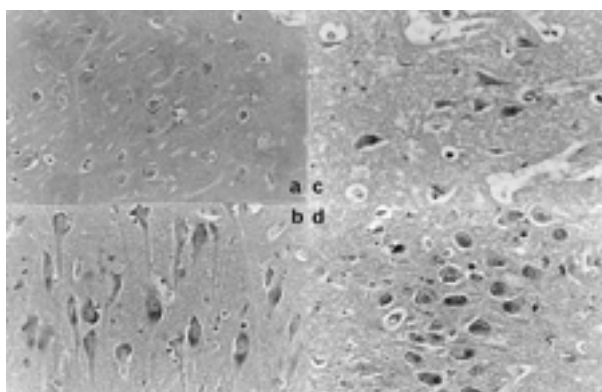


Fig. 10. Neuronal changes in hippocampus (VIP, x200). a and b ; short time survivor, c and d ; 2 days survivor, a and c ; CA1 region, b and d ; CA3 region.

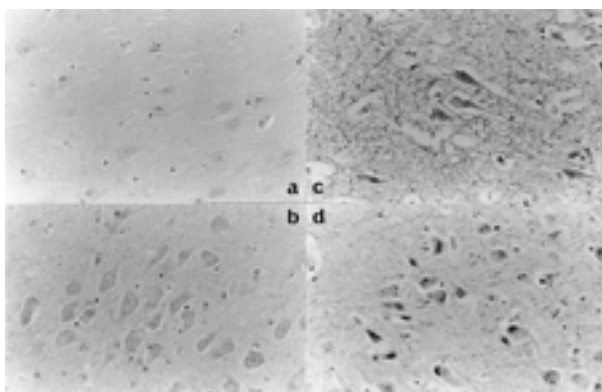


Fig. 11. Neuronal changes in hippocampus (hsp72, x200). a and b ; short time survivor, c and d ; 2 days survivor, a and c ; CA1 region, b and d ; CA3 region.

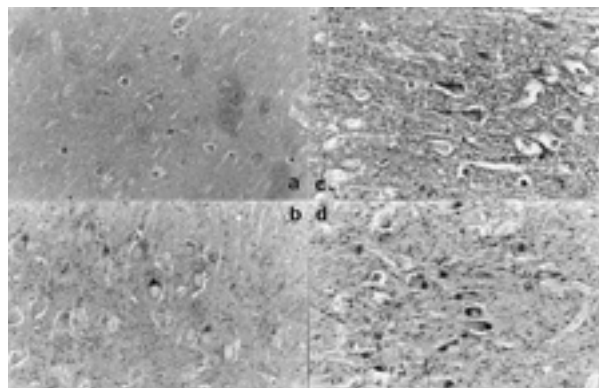


Fig. 12. Neuronal changes in hippocampus (c-Fos, x200). a and b ; short time survivor, c and d ; 2 days survivor, a and c ; CA1 region, b and d ; CA3 region.

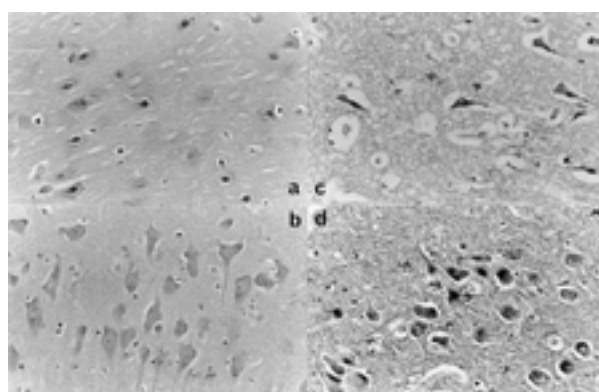


Fig. 13. Neuronal changes in hippocampus (b-FGF, x200). a and b ; short time survivor, c and d ; 2 days survivor, a and c ; CA1 region, b and d ; CA3 region.

hippocampus was examined. The degeneration of MAP2 was observed in all regions. Besides, VIP, Hsp72, c-Fos and b-FGF were found in the hippocampus, especially in regions from CA2 to CA4. From these results, it was suggested that neurons in the hippocampus were injured by diffuse brain damage, furthermore, repairing and protective mechanisms occurred especially from CA2 to CA4. In summary, it was considered that neuronal damage in diffuse brain injury was elucidated not only morphologically but also functionally.

Diffuse brain damage induces not only axonal and myelin injury but also neuronal injury. Therefore, in the cases suspected of diffuse brain damage, it is recommended to examine the neuronal changes in addition to observing the findings of diffuse axonal injury.

### 3. CAROTID BODY AND ITS CHANGES BY STRANGULATION

Autopsy diagnosis of mechanical asphyxia depends on the visual evaluation of injuries, and should also take into account general signs, such as petechial hemorrhages, cyanosis, congestion of organs, pulmonary edema, and the fluidity of blood. It would also be of great value to find evidence indicating a vital reaction to asphyxia.

In necropsy diagnostics, particularly with reference to

compressive neck injuries, little attention is given to investigating the carotid body, a small organ the size of a rice grain situated in the carotid bifurcation fork (Fig. 14) that secretes the following neuropeptides:enkephalin, VIP (63), and substance P (65). Therefore, in view of the anatomical position of the carotid body and its physiological functions, we have immunohistochemically studied the carotid body

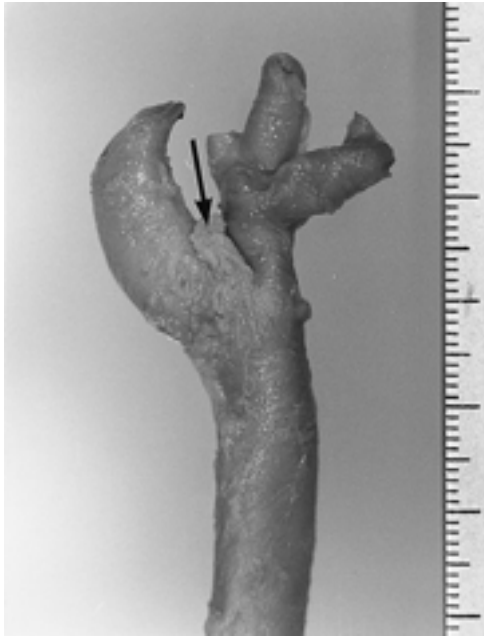

Fig. 14. Macroscopic view of the carotid body (arrow).

of autopsy cases involving strangulation to determine whether the findings can assist in achieving a diagnosis of a compressive neck injury.

We collected carotid bodies from forensic autopsy cases. Based on the cause of death, especially the position of the strangulation mark and subcutaneous hemorrhage and/or histological findings of the compressed skin, these carotid bodies were classified into 4 groups : Group A, 6 cases of manual and /or ligature strangulation with a mechanical force that had been applied to the neck near the carotid body ; Group B, 3 cases of hanging and ligature strangulation without the application of a mechanical force near carotid body and one case in which the patient died 18 days after strangulation, and group C, 4 cases of other types of asphyxia, i.e., smothering, choking or drowning. Group D were carotid body controls, collected from 5 cases of sudden unexpected natural death.

Anti-human enkephalin antisera and anti-human VIP antisera were used and immunohistochemical staining was performed by the avidin-biotin peroxidase complex (ABC) method. The appearance of the chief cells in the carotid body after staining was the basis for classification. If more than 60% of the cells were only lightly stained, then the cell classification was the "light" type ; if 40-60% appeared to be lightly stained, then the classification was the "light and dark" type. "Dark type" was less than 40%. The diameter of the cell and nucleus of the chief cells was measured.

Histopathological findings of carotid bodies are shown in Table 3.

The immunohistopathological staining results against

Table 3. Histopathological findings of the chief cells.

Group	Case No.	Main type of chief cell	Size( $\mu\text{m}$ )		Anti-Enkephalin	Anti-VIP
			Cell	Nucleus		
A	1	light	33.8 $\pm$ 8.2	14.0 $\pm$ 1.5	++	++
	2	light	10.6 $\pm$ 1.0	6.4 $\pm$ 0.9	++	+
	3	light	14.8 $\pm$ 3.0	8.6 $\pm$ 1.5	++	++
	4	light	12.2 $\pm$ 1.9	8.1 $\pm$ 1.4	++	+
	5	light	27.9 $\pm$ 6.3	13.0 $\pm$ 1.7	++	++
	6	light & dark	12.0 $\pm$ 1.4	6.4 $\pm$ 0.5	++	++
B	7	light & dark	8.3 $\pm$ 1.7	5.8 $\pm$ 1.2	++	++
	8	light & dark	9.2 $\pm$ 1.6	6.2 $\pm$ 0.4	++	++
	9	light & dark	8.0 $\pm$ 0.7	4.8 $\pm$ 0.4	+	+
C	10	dark	9.6 $\pm$ 0.8	5.6 $\pm$ 0.5	++	++
	11	light	10.2 $\pm$ 1.2	6.0 $\pm$ 0.6	++	++
	12	dark	8.0 $\pm$ 0.7	4.3 $\pm$ 0.4	++	++
	13	dark	9.0 $\pm$ 0.6	5.7 $\pm$ 0.5	++	++
D	14	light & dark	10.9 $\pm$ 1.9	5.6 $\pm$ 0.5	++	+
	15	dark	10.8 $\pm$ 1.2	5.8 $\pm$ 0.8	++	++
	16	dark	7.2 $\pm$ 0.8	5.5 $\pm$ 1.0	++	+
	17	dark	8.8 $\pm$ 1.0	4.8 $\pm$ 1.2	+	+
	18	light & dark	9.0 $\pm$ 1.3	5.5 $\pm$ 0.5	+	+



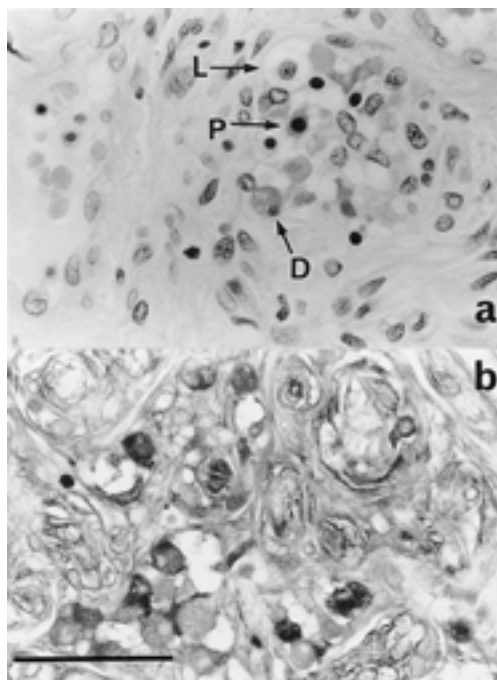


Fig. 15. Carotid body from Case 14 (Group D). a : Hematoxylin and eosin ( $\times 100$ ), b : Immunohistochemical staining for enkephalin ( $\times 100$ ). Bar=50  $\mu\text{m}$  L : light cell, D : dark cell, P : pyknotic cell.

enkephalin and VIP in the cytoplasm of the chief carotid body cells were specific. This method provided clearer evidence than the usual method of HE staining (Fig. 15), with enkephalin showing a stronger reactivity than VIP (Table 3). However from the results of immunohistochemical staining for many cases, it should be noted that because of autolysis, the immunoreactivities of these chief cells decreased significantly 1-2 days after death.

The chief cells consisted of 3 types : light, dark, or pyknotic, so designated from the cell's appearance on reacting to HE staining. Light cells were considered to be "active" cells, and both the dark and the pyknotic cells were considered to be inactive cells. The relationship of dark cells to light cells is still uncertain (63).

In Group A, most of the chief cells were the "light" type, with only a small number of dark and pyknotic cells. In contrast, the number of dark cells was greater in groups B, C, and D.

Furthermore, the diameters of the chief cells and their nuclei were enlarged only in group A (Table 3, Fig. 16). The mean size of the chief cells in group A was  $18.6 \pm 9.8 \mu\text{m}$ , and the mean nucleus size was  $9.4 \pm 3.3 \mu\text{m}$ . In groups B, C, and D, the mean size of the chief cells was  $8.5 \pm 0.6 \mu\text{m}$ ,  $9.2 \pm 0.9 \mu\text{m}$ , and  $9.3 \pm 1.5 \mu\text{m}$ , respectively, and the mean nucleus size was  $5.6 \pm 0.7 \mu\text{m}$ ,  $5.4 \pm 0.8 \mu\text{m}$ , and  $5.4 \pm 0.4 \mu\text{m}$ , respectively.

Since our findings have revealed the presence of light or "active" cells in Group A, this indicates that chief cells in the carotid body of these cases had synthesized and secrete neuropeptides. Measurement of the diameters of these chief cells and their nuclei revealed that the cells and nuclei were enlarged only in Group A (Table 3, Fig. 16). Moreover, results of an unpaired t-test calculation between Group D (the controls) and groups A, B, and C,

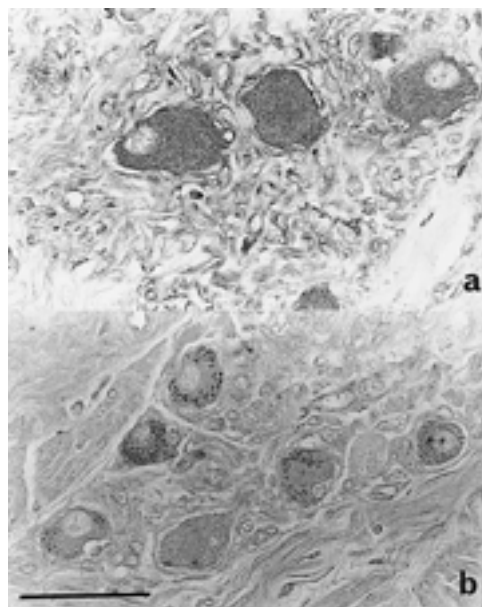


Fig. 16. Immunohistochemical staining for enkephalin. a : Case 1 ( $\times 100$ ), b : Case 5 ( $\times 100$ ). Bar=50  $\mu\text{m}$

respectively, confirmed that in Group A both the chief cell size ( $p=0.0693$ ) and nucleus size ( $p=0.0262$ ) were significantly enlarged, and that all of these enlarged cells were the light type (Fig. 16). And there was no correlation between those chief cell findings and age, and sex, respectively.

Generally, neurotransmitters are secreted and synthesized immediately reacting to stimulation. The large light cell is in keeping with intense synthetic activity and the presumed secretion (63). Ill-defined borders of light cells indicate secretion activity for secretion, and also show changeability of the cell shape. Thus, the larger cytoplasm and nucleus of these chief cells in Group A, the majority being the light type, are thought to be induced by a direct force that affected the carotid body, so that these changes in the chief cells can be a direct reaction to strangulation.

Immunohistochemical staining of the carotid body is potentially very useful for necropsy diagnosis, since it provides a method to detect evidence of mechanical asphyxia in suspected cases of manual and/or ligature strangulation.

#### ACKNOWLEDGEMENT

This study was partly supported by a Grant in Aid from the Ministry of Education, Science, and Culture of Japan No.03807036, No.04670357, No.05857049, No.05670393, No.06670462, and No.06857032.

#### REFERENCES

1. Kubo S, Ogata M, Iwasaki M, Kitamura O, Nakasono I : Immunohistochemical studies of hypoxic brain damage. *Res Pract Forens Med* 32 : 203-207, 1989
2. Kitamura O, Kubo S, Hirose W, Nakasono I : Histopathological studies of hypoxic and ischemic brain damage and its application to forensic autopsy cases. *Pro 1st Int Symposium Advances in Legal Medicine* : 252-254, 1990

3. Kitamura O : Immunohistochemical investigation of hypoxic / ischemic brain damage in forensic autopsy cases. *Int J Leg Med* 107 : 69-76, 1994
4. Kubo S, Orihara Y, Tsuda R, Kitamura O, Maeda E, Nakasono I : An autopsy case of traumatic subdural hematoma from arterio-venous malformation with diffuse axonal injury. *Jpn J Leg Med* 49 : 37-43, 1995
5. Kubo S, Orihara Y, Tsuda R, Hirose W, Nakasono I : Studies for pathological findings of diffuse axonal injury (DAI) in forensic autopsy cases, *Jpn J Forens Pathol* 1 : 173-181, 1995
6. Kubo S, Orihara Y, Matsumoto H, Hirose W, Nakasono I : Diffuse axonal injury and its neuronal changes in the hippocampus. *Proc 14th International Association Forensic Sciences : 1997* (in press)
7. Briery JB, Meldrum BS, Brown AW : The threshold and neuropathology of cerebral " anoxic-ischemic " cell change. *Arch Neurol* 29 : 367-374, 1973
8. Compton JL, McCarthy PD : Induction of the *Drosophila* heat shock response in isolated polytene nuclei. *Cell* 14 : 191-201, 1978
9. du Bois M, Bowman PD, Goldstein GW : Cell proliferation after ischemic injury in gerbil brain. An immunocytochemical and autoradiographic study. *Cell Tissue Res* 242 : 17-23, 1985
10. Gehrman J, Bonnekoh P, Miyazawa T, Hossmann KA, Kreutzberg GW : Immunocytochemical study of early microglial activation in ischemia. *J Cereb Blood Flow Metab* 12 : 257-269, 1992
11. Graham DI : Hypoxia and vascular disorders. In : Adams JH, DuChen LW, eds. *Greenfield's neuropathology*. Edward Arnold, 1992, pp.153-268
12. Hirano A : A guide to neuropathology. Igaku-shoin, Tokyo, 1986
13. Horn M, Schlote W : Delayed neuronal death and delayed neuronal recovery in the brain following global ischemia. *Acta Neuropathol* 85 : 79-87, 1992
14. Kato H, Liu Y, Araki T, Kogure K : Temporal profile of the effects of pretreatment with brief cerebral ischemia on the neuronal damage following secondary ischemic insult in the gerbil; cumulative damage and protective effects. *Brain Res* 553 : 238-242, 1991
15. Kirino T : Delayed neuronal death in the gerbil hippocampus following ischemia. *Brain Res* 239 : 57-69, 1982
16. Kirino T, Sano K : Selective vulnerability in the gerbil hippocampus following transient ischemia. *Acta Neuropathol* 62 : 201-208, 1984
17. Kirino T, Sano K : Fine structural nature of delayed neuronal death following ischemia in the gerbil hippocampus. *Acta Neuropathol* 62 : 209-218, 1984
18. Kirino T, Tsujita Y, Tamura A : Induced tolerance to ischemia in gerbil hippocampal neuron. *J Cereb Blood Flow Metab* 11 : 299-307, 1991
19. Kitagawa K, Matsumoto M, Tagaya M, Hata R, Ueda H, Niinobe M, Handa N, Fukunaga R, Kimura K, Mikisiba K, Kamada T : ' Ischemic tolerance ' phenomenon found in the brain. *Brain Res* 528 : 21-24, 1990
20. Kwei S, Jiang C, Haddad GG : Acute anoxia-induced alterations in MAP2 immunoreactivity and neuronal morphology in rat hippocampus. *Brain Res* 620 : 203-210, 1993
21. Li G : Induction of thermotolerance and enhanced heat shock protein synthesis in Chinese hamster fibroblasts by sodium arsenite and by ethanol. *J Cell Physiol* 115 : 116-122, 1983
22. Lim R : Glia maturation factor : an update. In : Norenberg M, Hertz L, Schousboe A, eds. *The biochemical pathology of astrocytes (Neurology and neurobiology vol 39)*. Alan R. Liss, New York, 1988, pp.67-78
23. Mannoji H, Yeger H, Becker LE : A specific histochemical marker (lectin *Recinus communis* agglutinin-I) for normal human microglia, and application to routine histopathology. *Acta Neuropathol* 71 : 341-343, 1986
24. Matsumoto M, Yamamoto K, Homburger HA, Yanagihara T : Early detection of cerebral ischemic damage and repair process in the gerbil by use of an immunohistochemical technique. *Mayo Clin Proc* 62 : 460-472, 1987
25. Merrill JE, Kutsunai S, Mohlstrom C, Hofman F, Groopman L, Golde DW : Proliferation of astroglia and oligodendroglia in response to human T cell-derived factors. *Science* 224 : 1428-1430, 1984
26. Meyer FB : Calcium, neuronal hyperexcitability and ischemic injury. *Brain Res Brain Res Rev* 14 : 227-243, 1989
27. Morioka T, Kalechua AN, Streit WJ : The microglial reaction in the rat dorsal hippocampus following transient forebrain ischemia. *J Cereb Blood Flow Metab* 11 : 966-973, 1991
28. Nagagomi T, Kirino T, Kanemitsu H, Tsujita Y, Tamura A : Early recovery of protein synthesis following ischemia in hippocampal neurons with induced tolerance in the gerbil. *Acta Neuropathol* 86 : 10-15, 1993
29. Ng T, Graham DI, Adams JH, Ford I : Changes in the hippocampus and the cerebellum resulting from hypoxic insults : frequency and distribution. *Acta Neuropathol* 78 : 438-443, 1989
30. O'Callaghan JP, Brinton RE, MacEwen BS : Glucocorticoids regulate the concentration of glial fibrillary protein throughout the brain. *Brain Res* 494 : 159-161, 1989
31. Petit CK, Feldmann E, Pulsinelli WA, Plum F : Delayed hippocampal damage in humans following cardiorespiratory arrest. *Neurology* 37 : 1281-1286, 1987
32. Petit CK, Morgello S, Felix JC, Holden LM : Astrocytes in cerebral ischemia. In : Norenberg MD, Hertz L, Schousboe A, eds. *The biochemical pathology of astrocytes (Neurology and Neurobiology, vol 39)*. Alan R. Liss, New York, 1988, pp.341-349
33. Petit CK, Morgello S, Felix JC, Lesser ML : The two patterns of reactive astrocytosis in postischemic rat brain. *J Cereb Blood Flow Methab* 10 : 850-859, 1990
34. Sawada M, Suzunura A, Ohno K, Marunouchi T : Regulation of astrocyte proliferation by prostaglandin E2 and alpha subtype of protein kinase C. *Brain Res* 613 : 67-73, 1993
35. Schneider M : Survival and revival of the brain in

- anoxia and ischemia. In : Meyer JS, Gastaut H, eds. Cerebral anoxia and the encephalogram. Charles C Thomas, Springfield, 1961, pp.134-143
36. Schlesinger M : Heat shock protein : the search for functions. *J Cell Biol* 103 : 321-325, 1986
  37. Sciandra JJ, Subjeck JR, Hughes CS : Induction of glucose-regulated proteins during anaerobic exposure and of heat shock proteins after reoxygenation. *Proc Natl Acad Sci USA* 81 : 4843-4847, 1984
  38. Smith ML, Auer RN, Siesj BK : The density and distribution of ischemic brain injury in the rat following 2-10 min of forebrain ischemia. *Acta Neuropathol* 64 : 319-332, 1984
  39. Tranque PA, Suarez I, Olmas G, Fernabdez G, Garcia-Segura LM : Estradiol-induced redistribution of glial fibrillary acidic protein immunoreactivity in the rat brain. *Brain Res* 406 : 348-351, 1987
  40. Takeda S, Ikuta F : Neuronal vulnerability to hypoxia and hypoglycemia. *Adv Neurol Sci* 36 : 236-260, 1992
  41. Vass K, Welch WJ, Nowak TS jr : Localization of 70-kDa stress protein induction in gerbil brain after ischemia. *Acta Neuropathol* 77 : 128-135, 1988
  42. Yamamoto K, Yoshimine T, Homburger HA, Yanagihara T : Immunohistochemical investigation of regional cerebral ischemia in the gerbil : occlusion of the posterior communicating artery. *Brain Res* 371 : 244-252, 1986
  43. Strich SJ : Diffuse degeneration of the cerebral white matter in severe dementia following head injury. *J Neuro Neurosurg Psychiatry* 19 : 163-185, 1956
  44. Strich SJ : Shearing of nerve fibers as a cause of brain damage due to head injury ; a pathological study of twenty cases. *The Lancet* Aug. 26 : 443-448, 1961
  45. Adams JH, Michell DE, Graham DI, Doyle D : Diffuse brain damage of immediate impact type, Its relationship to " primary brain-stem damage " in head injury. *Brain* 100 : 489-502, 1977
  46. Adams JH, Graham DI, Murray LS, Scott G : Diffuse axonal injury due to non-missile head injury in humans: an analysis of 45 cases. *Ann Neurol* 12 : 557-563, 1982
  47. Gennarelli TA, Thibault LE, Adams JH, Graham DI, Thompson CJ, Marcincin RP : Diffuse axonal injury and traumatic coma in the primate. *Ann Neurol* 12 : 564-574, 1982
  48. Gennarelli TA : Head injury in man and experimental animals : clinical aspects. *Acta Neurochir (Suppl)* 32 : 1-13, 1983
  49. Imajo T, Roessman U : Diffuse axonal injury. *Am J For Med Path* 5 : 217-222, 1984
  50. Blumberg PC, Jones NR, North JB : Diffuse axonal injury in head trauma. *J Neuro Neurosurg Psychiatry* 52 : 838-841, 1989
  51. Adams JH : Microscopic diffuse axonal injury in cases of head injury. *Med Sci Law* 25 : 265-269, 1985
  52. Sahuquillo-Barris J, Lamarrca-Ciuro J, Vilalta-Castan J, Rubio-Garcia E, Rodriguez-Pazos M : Acute subdural hematoma and diffuse axonal injury after sever head trauma. *J Neurosurg* 68 : 894-900, 1988
  53. Tubokawa T, Katayama Y, Yen CH : Clinical profile of diffuse brain injury-Classification of diffuse brain injury-. *Shinkei-gaisyou* 12 (in Japanese) : 31-36, 1989.
  54. Tokutomi T, Shigemori M, Kuramoto S, Nakashima H, Sasaguri Y : Clinicopathological study of acute subdural hematoma and traumatic intracerebral hematoma-In relation to diffuse axonal injury-. *Shinkei-gaisyou* 12 (in Japanese) : 56-61, 1989.
  55. Mukai T, Ohshiro T, Uchida E, Tamaki N, Morinaga Y, Nagamori H : Significance of diffuse axonal injury in cases with brain injury. *Res Pract Forens Med* 34 : 195-199, 1991
  56. Taft WC, Yang K, Dixon CE, Hayes RL : Microtubule-associated protein 2 levels decrease in hippocampus following traumatic brain injury. *J Neurotrauma* 9 : 281-290, 1992
  57. Zhang X, Verge VMK, Wiesenfeld-Hallin Z, Piehl F, Hökfelt I : Expression of neuropeptides and neuropeptide m RNAs in spinal cord after axotomy in the rat, with special reference to motoneurons and galanin. *Exp Brain Res* 93 : 450-461, 1993
  58. Brenneman DE, Eiden LE : Vasoactive intestinal peptide and electrical activity influence neuronal survival. *Proc Natl Acad Sci USA* 83 : 1159-1162, 1986
  59. Nowak TS, Osborne OC, Suga S : Stress protein and proto-oncogene expression as indicators of neuronal pathophysiology after ischemia. *Progress in Brain Research* 96 : 195-208, 1993
  60. Miyata S, Nakashima I, Kiyohara I : Expression of c-fos immunoreactivity in the hypothalamic magnocellular neurons during chronic osmotic stimulation. *Neuroscience letters* 175 : 63-66, 1994
  61. Phillips LL, Belardo EI : Expression of c-fos in the hippocampus following mild and moderate fluid percussion brain injury. *J Neurotrauma* 9 : 323-333, 1992
  62. Kubo S, Ogata M, Kitamura O, Tsuda R, Orihara Y, Hirose W, Matsumoto H, Nakasono I : Immunohistological investigations of autopsied carotid bodies and their application to diagnosing strangulation. *Int J Leg Med* 106 : 281-284, 1994
  63. Heath D, Smith P : The pathology of the carotid body and sinus. Edward Arnold, London, 1985
  64. Smith P, Jago R, Heath D : Anatomical variation and quantitative histology of the normal and enlarged carotid body. *J Pathology* 137 : 287-304, 1982
  65. Wharton J, Polak JM, Pearse AGE, Macgregor GP, Bryant MG, Bloom SR, Emson PC, Bisgard GE, Will JA : Enkephalin-, VIP-and substance P-like immunoreactivity in the carotid body. *Nature* 284 : 269-271, 1980